

Bilateral maxillary sinus floor augmentation with tissue-engineered autologous osteoblasts and demineralized freeze-dried bone

AASHISH DESHMUKH, RINKU KALRA, SHRUTI CHHADVA, ANGAD SHETYE

Abstract

The pneumatization of the maxillary sinus often results in a lack of sufficient alveolar bone for implant placement. In the last decades, maxillary sinus lift has become a very popular procedure with predictable results. Sinus floor augmentation procedures are generally carried out using autologous bone grafts, bone substitutes, or composites of bone and bone substitutes. However, the inherent limitations associated with each of these, have directed the attention of investigators to new technologies like bone tissue engineering. Bone marrow stromal cells have been regarded as multi-potent cells residing in bone marrow. These cells can be harvested from a person, multiplied outside his body using bioengineering principles and technologies and later introduced into a tissue defect. We present a case where tissue-engineered autologous osteoblasts were used along with demineralized freeze-dried bone for sinus floor augmentation.

Keywords: Autologous osteoblast implantation, bone grafting, sinus floor augmentation, tissue engineering

Introduction

The use of osteointegrated implants has become a routine procedure for replacement of missing teeth. However, for better stability of implants, resorbed bone in edentulous regions often requires augmentation before an implant is inserted. The posterior maxilla demonstrates the lowest density of bone in the oral cavity. The posterior edentulous maxilla also presents special challenges in implant placement compared with other areas of the mouth due to progressive resorption that results in less available bone. This poor quality and quantity of available bone challenge the essential condition for successful implant placement. Tatum^[1] was the first to report the penetration of the maxillary sinus with a modified Caldwell-Luc technique. In the posterior maxilla, using an unfinished fenestration osteotomy in the maxilla's external face, a space is created between the residual maxillary ridge and the Schneiderian

membrane, commonly known as the "Sinus lift procedure". Adequate bone formation in this space can be achieved with a variety of graft materials when a reasonable healing period (5-6 months) is allowed.

Autologous bone graft has been considered as the gold standard for bone grafting.^[2] It is the only graft material that heals by osteoinduction. Autologous bone from the iliac crest has been used most commonly and successfully for reconstruction of a variety of osseous defects. However, to overcome its disadvantages and to reduce morbidity at the donor site, allogeneic, xenogenous, alloplastic, or composite materials were introduced.

The currently available alternative alloplastic materials have significant disadvantages in a compromised vascular environment. However, autologous tissue-engineered osteoblasts offer important advantages compared with conventional autogenous bone grafts because the donor site morbidity is minimal and are performed as an outpatient procedure with local anesthesia.

We present a case where tissue-engineered autologous osteoblasts were used in combination with demineralized freeze-dried bone (DFDB) for bilateral sinus lift procedure.

Case Report

A 52-year-old female reported to the Department of Oral and Maxillofacial Surgery for the placement of implants in order to receive the implant-supported prosthesis in her bilateral edentulous posterior maxillary regions. The patient had been given other prosthetic options but decided upon implant-supported prosthesis. The medical history revealed that the patient was type II diabetic, hypertensive, asthmatic, anemic, and osteoporotic. She had undergone

Department of Oral and Maxillofacial Surgery, YMT Dental College and Hospital, Mumbai, Maharashtra, India

Correspondence: Dr. Aashish Deshmukh,
Department of Oral and Maxillofacial Surgery,
YMT Dental College and Hospital, Institutional Area,
Sector-4, Kharghar, Navi Mumbai - 410 210, Maharashtra, India.
E-mail: deshmukhaashish@gmail.com

Access this article online	
Quick Response Code: 	Website: www.contempclindent.org
	DOI: 10.4103/0976-237X.156057

multiple dental extractions due to poor periodontal health. Clinical examination revealed bilateral edentulous posterior maxillary ridges. Subsequent radiographic evaluation (orthopantomography [OPG] and cone-beam computed tomography) revealed sinus pneumatization on both the sides [Figures 1 and 2].

The treatment plan included Sinus lift procedure using Ossron[®] (autologous tissue-engineered osteoblasts) and DFDB graft, followed by, insertion of dental implants and the subsequent prosthetic phase. The patient was subjected to a thorough medical and hematological examination. When her medical conditions were found to be well under control, she was taken up for the harvest of bone marrow and bilateral sinus lift procedure.

Harvest of bone marrow

Six weeks before, the sinus lift procedure, the marrow cells were harvested from posterior superior iliac crest with bone marrow aspiration technique. The surgical site, posterior iliac crest was prepared with standard surgical protocol. Local anesthesia was infiltrated. Stab incision was taken on the posterior iliac crest. Needle - 11 Gz × 10 cm (care fusion) was inserted and about 10 ml bone marrow was harvested and collected in two bottles with Dulbeccos modified Eagles's medium. The specimen was transported to RMS Regrow laboratory, maintaining the temperature between 2°C and 8°C. The patient was discharged immediately. The osteoblasts were cultured for a period of 6 weeks.

Sinus lift

After 6 weeks, when the osteoblasts were ready to be implanted, the patient was taken under sedation and local anesthesia using lignocaine 2% with adrenaline 1:80,000 for bilateral infra-orbital, posterior superior alveolar and greater palatine nerve blocks. Prophylactic antibiotics were administered before the procedure. The patient was scrubbed and draped as per standard surgical protocol. The standard lateral approach technique was used for the procedure. A trapezoidal muco-periosteal flap was reflected from the distal aspect of 13 to 18 region using a crestal incision and anterior and posterior releasing incisions. A 1.5 cm × 1 cm bony window was created in the antero-lateral wall of the maxilla, approximately 3 mm superior to the crest. The membrane was elevated inferiorly, anteriorly, and posteriorly together with the bony window [Figure 3] until the desired elevation was reached keeping it well below the level of the ostium, as guided by the measurements on the computed tomography. The membrane was checked for any perforation. The space thus created between the bony floor of the sinus and the membrane was filled with Ossron [Figure 4] and DFDB (allograft), making a putty [Figure 5]. A collagen membrane was placed and secured in position to cover the lateral window. Hemostasis was achieved and the flap was repositioned and sutured with 4-0 vicryl. The same

surgical steps were carried out on the left side. There was slight anatomical difference between the two sides, with the left sinus being narrower mediolaterally than the right. The patient was discharged after 2 h. She was prescribed antibiotics and analgesics for 5 days. Healing was uneventful. Postoperative OPG taken after 3 months shows adequate bone height [Figure 6].

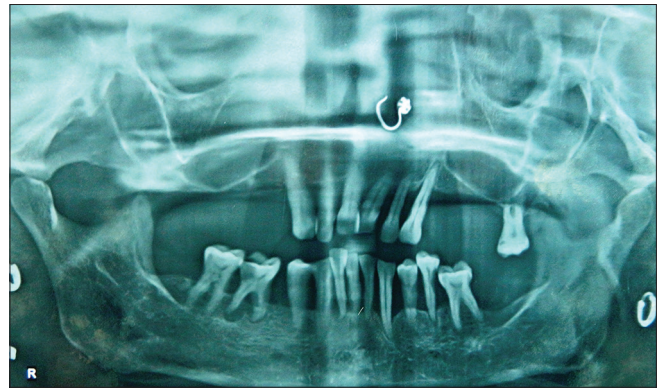

Figure 1: Preoperative orthopantomography showing the deficient height in the posterior maxilla

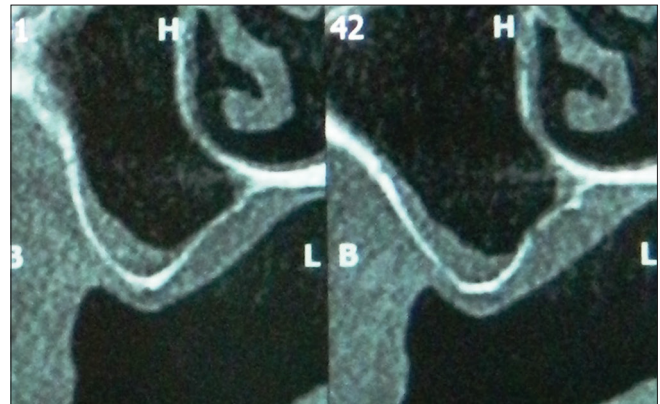


Figure 2: Cone-beam computed tomography showing sinus pneumatization on both the sides

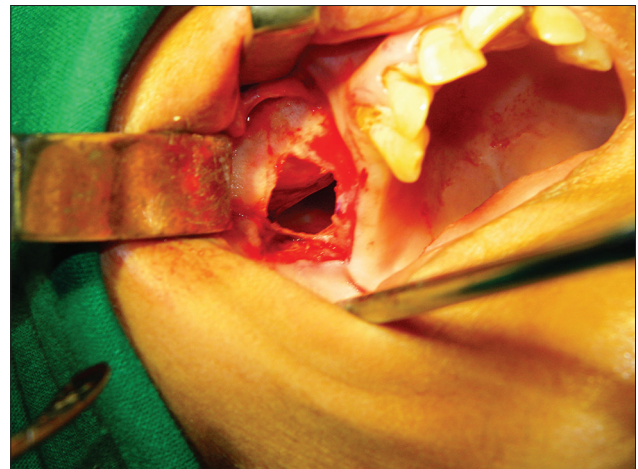


Figure 3: Elevation of the sinus membrane

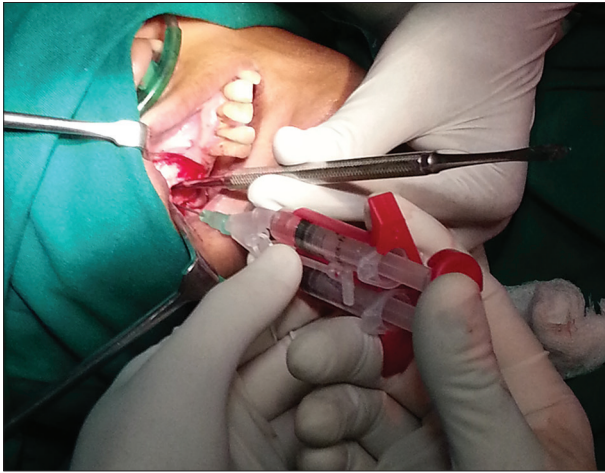


Figure 4: Placement of ossron

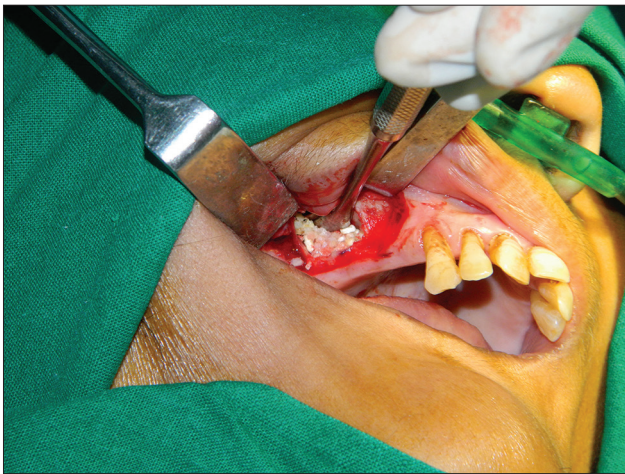


Figure 5: Placement of demineralized freeze-dried bone (allograft)

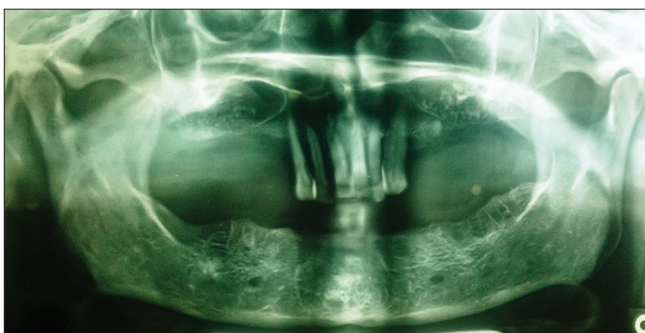


Figure 6: Three months postoperative orthopantomography showing adequate bone height

Discussion

Sinus lift procedure has become a predictable and acceptable technique for bone augmentation in the posterior maxilla. Since its first description by Tatum in 1976,^[1] many modifications have been done to the technique. The more notable ones are by Boyne and James in 1980,^[3] Kent and Block 1989.^[4]

Subsequently, Jensen *et al.*^[5] described a two-stage procedure for sinus lift followed by implant placement at a later date. Loukota *et al.*^[6] described a single stage procedure of immediate implants placement at the time of sinus lift procedure.

With the procedure and technique now almost been a routine, the current trend is toward making bone grafting and bone formation more predictable. Use of autologous bone for grafting has been advocated by many.^[2,7-9] Though autologous bone is the gold standard for sinus grafting, it has the limitations of requiring donor site and the need for hospital care, especially if iliac crest bone harvesting is involved. Apart from potential problems such as pain and infection at the donor site, intraoral bone grafts have a limited volume.^[10] Alloplastic materials in turn have drawbacks, particularly in a vascularly compromised environment.^[11] Increasingly, attention is being shifted to use of tissue-engineered bone. Tissue-engineering procedures for bony augmentations of the maxilla offer significant advantages compared with conventional grafts, as there is minimal or no donor site morbidity. Ideally, these procedures are used under outpatient conditions under local anesthesia, using exclusively autologous material with bone forming capacity.

The ongoing development of tissue-engineered materials is aiming at a significant reduction in donor site morbidity and providing materials with better mechanical properties than those currently used.^[12] Bone marrow stromal cells (BMSC'S) have been regarded as multi potent cells residing in bone marrow. Under adequate culture conditions, BMSC'S can differentiate into various lineages of mesenchymal tissues, including bone, cartilage, fat, tendon, muscle, and marrow stroma.^[13,14] In addition, they are relatively easy to harvest and easily expandable *in vitro*.^[13] Their advantages have made BMSC'S ideal seed cells for tissue engineering.

Schmelzeisen *et al.*^[11] first described the use of periosteum derived tissue-engineered bone for Sinus grafting in two patients. Their preliminary results were encouraging. A year later, they reported their study for 27 patients and their results suggest that periosteum-derived osteoblasts on a suitable matrix can form lamellar bone within 3 months after transplantation and provide a reliable basis for simultaneous or secondary insertion of dental implants.^[15] Similar studies were reported by others.^[16,17]

In our current case report, we have used autologous osteoblasts obtained and cultured from bone marrow aspirate of posterior iliac crest. As per our knowledge, such a procedure has not been reported so far for sinus floor augmentation. Since the patient was osteoporotic, autologous block grafts were not deemed advisable. Furthermore, the sole use of alloplast or allografts would not have been a good option in a diabetic patient due to the

compromised microvasculature. We have also combined the same with DFDB so as to achieve greater volume and take advantage of the excellent osteoinductive characteristics of autologous osteoblasts. The postoperative radiograph shows adequate height of the bilateral posterior maxillary edentulous alveolar ridge, with no postoperative sequelae.

Conclusion

We believe tissue engineering makes it possible to fill larger volumes of the sinus cavity and provides predictable bone formation as compared to alloplasts and allografts. Tissue engineering also reduces donor site morbidity and makes the procedure more acceptable to the patient. This study can be regarded as a pilot study; further such studies on a larger scale can be carried out especially in such medically compromised cases where large volume autologous bone is not possible to harvest.

Acknowledgment

ossron® is a registered trademark of RMS regrow, Regenerative medical services Limited, India.

References

1. Tatum H Jr. Maxillary and sinus implant reconstructions. *Dent Clin North Am* 1986;30:207-29.
2. Moreno Vazquez JC, Gonzalez de Rivera AS, Gil HS, Mifsut RS. Complication rate in 200 consecutive sinus lift procedures: Guidelines for prevention and treatment. *J Oral Maxillofac Surg* 2014;72:892-901.
3. Boyne PJ, James RA. Grafting of the maxillary sinus floor with autogenous marrow and bone. *J Oral Surg* 1980;38:613-6.
4. Kent JN, Block MS. Simultaneous maxillary sinus floor bone grafting and placement of hydroxylapatite-coated implants. *J Oral Maxillofac Surg* 1989;47:238-42.
5. Jensen J, Simonsen EK, Sindet-Pedersen S. Reconstruction of the severely resorbed maxilla with bone grafting and osseointegrated implants: A preliminary report. *J Oral Maxillofac Surg* 1990;48:27-32.
6. Loukota RA, Isaksson SG, Linnér EL, Blomqvist JE. A technique for inserting endosseous implants in the atrophic maxilla in a single stage procedure. *Br J Oral Maxillofac Surg* 1992;30:46-9.
7. Martuscelli R, Toti P, Sbordone L, Guidetti F, Ramaglia L, Sbordone C. Five-year outcome of bone remodelling around implants in the maxillary sinus: Assessment of differences between implants placed in autogenous inlay bone blocks and in ungrafted maxilla. *Int J Oral Maxillofac Surg* 2014;43:1117-26.
8. Schaudy C, Vinzenz K. Osteoplastic reconstruction of severely resorbed maxilla by stack plasty: Combining sinus augmentation with lateral and vertical onlay bone grafting. *Br J Oral Maxillofac Surg* 2014;52:647-51.
9. Voss P, Sauerbier S, Wiedmann-Al-Ahmad M, Zizelmann C, Stricker A, Schmelzeisen R, *et al.* Bone regeneration in sinus lifts: Comparing tissue-engineered bone and iliac bone. *Br J Oral Maxillofac Surg* 2010;48:121-6.
10. Younger EM, Chapman MW. Morbidity at bone graft donor sites. *J Orthop Trauma* 1989;3:192-5.
11. Schmelzeisen R, Schimming R, Sittlinger M. Making bone: Implant insertion into tissue-engineered bone for maxillary sinus floor augmentation-a preliminary report. *J Craniomaxillofac Surg* 2003;31:34-9.
12. Burg KJ, Porter S, Kellam JF. Biomaterial developments for bone tissue engineering. *Biomaterials* 2000;21:2347-59.
13. Caplan AI. Mesenchymal stem cells. *J Orthop Res* 1991;9:641-50.
14. Pittenger MF, Mackay AM, Beck SC, Jaiswal RK, Douglas R, Mosca JD, *et al.* Multilineage potential of adult human mesenchymal stem cells. *Science* 1999;284:143-7.
15. Schimming R, Schmelzeisen R. Tissue-engineered bone for maxillary sinus augmentation. *J Oral Maxillofac Surg* 2004;62:724-9.
16. Montesani L, Schulze-Späte U, Dibart S. Sinus augmentation in two patients with severe posterior maxillary height atrophy using tissue-engineered bone derived from autologous bone cells: A case report. *Int J Periodontics Restorative Dent* 2011;31:391-9.
17. Beaumont C, Schmidt RJ, Tatakis DN, Zafropoulos GG. Use of engineered bone for sinus augmentation. *J Periodontol* 2008;79:541-8.

How to cite this article: Deshmukh A, Kalra R, Chhadva S, Shetye A. Bilateral maxillary sinus floor augmentation with tissue-engineered autologous osteoblasts and demineralized freeze-dried bone. *Contemp Clin Dent* 2015;6:243-6.

Source of Support: Nil. **Conflict of Interest:** None declared.