

Acquired pure red cell aplasia in a patient with ankylosing spondylitis- a case report and literature review

Xianfang Shao, MD^a, Wei Wei, MD, PhD^b, Yangzhi Zhao, MD^a, Xinyue Liang, MD^a, Qiuju Liu, MD, PhD^{a,*}

Abstract

Rationale: Acquired pure red cell aplasia (PRCA) can be a secondary response to some autoimmune disorders. However, there is no data about the possibility of acquired PRCA being a secondary complication to ankylosing spondylitis (AS).

Patient concerns: A 42-year-old male who had a history of AS for 14 years. He got serious anemia 17 months ago. Bone marrow smear indicated PRCA.

Diagnose: He was diagnosed with acquired PRCA secondary to AS.

Intervention: The combination treatment of immunosuppressants with hematopoiesis stimuli was successful.

Outcomes: The patient recovered from PRCA, and showed improvement in his AS.

Lessons: Acquired PRCA can be secondary to AS. Cyclosporine is effective in controlling AS arthritis syndrome and in addition to immunosuppressants, promotion of erythroid hematopoiesis is equally important.

Abbreviations: AA = aplastic anemia, AS = ankylosing spondylitis, CRP = C-reactive protein, ESR = erythrocyte sedimentation rate, HLA-B27 = human leucocyte antigen-B27, NSAIDs = non-steroidal anti-inflammatory drugs, PRCA = Pure red blood cell aplasia, rHuEPO = recombinant human erythropoietin, SLE = systemic lupus erythematosus, TNFi = inhibitors of tumor necrosis factors.

Keywords: acquired pure red cell aplasia, ankylosing spondylitis, cyclosporine, glucocorticoid, recombinant human erythropoietin

1. Introduction

Pure red blood cell aplasia (PRCA) is characterized by purely normocytic, normochromic anemia, a very low level of reticulocytes, and a marked reduction or absence of an erythroid precursor in the bone marrow. PRCA is divided into two subtypes according to its causes: congenital PRCA and acquired PRCA. Acquired PRCA may be primary or secondary to some

autoimmune/collagen vascular disorders, inflammatory bowel disease, infections, leukemia, thymoma, drugs, or toxins.^[1-3] Ankylosing spondylitis (AS) is one autoimmune disorder with an insidiously progressive and debilitating form of arthritis involving the axial skeleton. However, there is no data about whether AS can complicate with PRCA. Herein, we first report a case of acquired PRCA in one AS patient.

Editor: N/A.

XS and WW contributed equally to this paper.

This case report received the institutional review board approval. Written informed consent was obtained from the patient for publication of this case report and any accompanying images.

This research was financially supported by Science and Technology department of Jilin province (No. 20180101132JC).

The authors have no conflicts of interest to disclose.

^a Hematology Section, Cancer Center, ^b Department of Urology, the First Hospital of Jilin University, Changchun, JL, China.

* Correspondence: Qiuju Liu, Hematology section, Cancer Center, the First Hospital of Jilin University, No. 71 Xinmin street, Changchun, 130021, China (e-mail: 327016544@qq.com).

Copyright © 2019 the Author(s). Published by Wolters Kluwer Health, Inc. This is an open access article distributed under the terms of the Creative Commons Attribution-Non Commercial License 4.0 (CCBY-NC), where it is permissible to download, share, remix, transform, and buildup the work provided it is properly cited. The work cannot be used commercially without permission from the journal.

Medicine (2019) 98:27(e16160)

Received: 5 January 2019 / Received in final form: 26 April 2019 / Accepted: 31 May 2019

<http://dx.doi.org/10.1097/MD.00000000000016160>

2. Case report

A 42-year-old male was diagnosed with AS after 15-years with lumbosacral pain followed by limited spinal activity and femoral head necrosis that required bilateral hip replacement surgery in 2003 (Fig. 1A). To alleviate his progressive arthritis symptoms, he had taken non-steroidal anti-inflammatory drugs (NSAIDs) for 21 years, including sulfasalazine (detailed dosage was unknown) and tripterygium wilfordii tablets (48 µg/day) for 7 years. In June 2016, he changed regimens and began to take a compound of traditional Chinese medicine containing tripterygium wilfordii (approximately 5 g/day) and leflunomide (20 mg/day). During that year, he felt fatigued and experienced gradual palpitations as well as a transient loss of consciousness with severe anemia (hemoglobin 3.5 g/dL) in July 2017. He stopped all anti-ankylosing spondylitis drugs for 2 months but without improvement in his anemia. As a result, he became dependent on transfusions to maintain his hemoglobin levels at approximately 7.0 g/dL. Physical signs showed anemia countenance, no lymphadenopathy or splenomegaly, swollen left elbow and right wrist joints, spinal bending deformation and limited activity, the patient was positive for sacroiliac joint tenderness, pillow wall

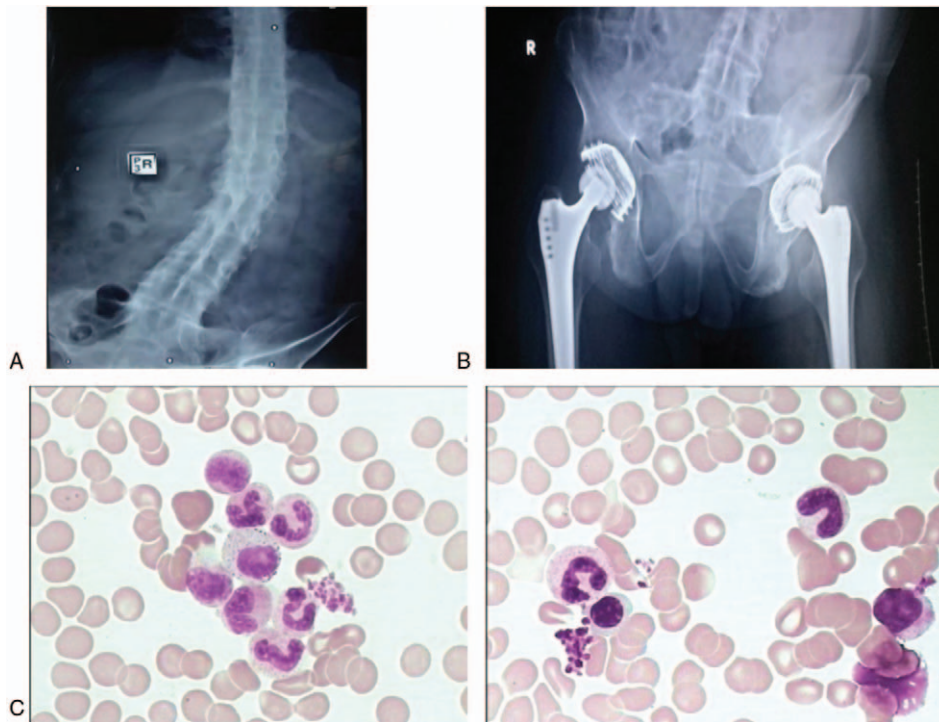


Figure 1. (A) In 2003, spine X-ray photograph showing a square cone and bamboo-like coalition spine. (B) In September 2017, articulationes sacroiliaca X-ray of the patient showing bilateral articulationes sacroiliaca bone fusion. (C) In September 2017, 400 \times , Hematoxylin-eosin stain of bone marrow showing hypoplasia, erythroid precursor absence and mature red blood cells were variant in size.

test, and the bilateral 4 word test. Laboratory examinations showed a leukocyte count of 4190/ μ L with an absolute neutrophil count of 2520/ μ L, hemoglobin level of 7.5 g/dl (after ten units of red blood cell transfusions), erythrocyte mean cell volume of 91.6 fl (82–100), mean cell hemoglobin of 29.2 pg (27–34), mean cell hemoglobin concentration of 318 g/L (316–354), and platelet level of 240,000/ μ L. The reticulocyte percentage and count were 0.39% (0.67–1.9%) and 9000/ μ l (30,400–93,500/ μ L), respectively. Bone marrow morphology showed hypoplasia, absence of erythroid precursor and mature red blood cells were variant in size (Fig. 1C). The marrow biopsy also showed the absence of immature erythrocytes. Serum ferritin level was 1650 μ g/L (22–322 μ g/L). Serum erythropoietin (EPO) level was 750 IU/L (5.4–31.0 IU/L). The hemolytic tests including direct and indirect Coombs were negative. Chest CT scan showed no signs of thymoma.

To clarify the patient's AS diagnosis and activity, he completed the relevant tests as follows: positive human leucocyte antigen-B27 (HLA-B27), C-reactive protein (CRP) 131.07 mg/L (0–5 mg/L), erythrocyte sedimentation rate (ESR) 76 mm/1 hour (0–15 mm/1 hour). Articulationes sacroiliaca X-ray showed bilateral articulationes sacroiliaca bone fusion, a reduced joint space and lumbar interspinous ligament ossification (Fig. 1B). Ultrasound examination of the left elbow joint showed left elbow joint synovitis and left ulnar olecranon bone erosion. Neither chest CT nor tuberculosis T-spot showed any active tuberculosis. Liver and kidney function tests were all within the normal range. The T-lymphocyte subpopulation showed the ratio of CD4/CD8 was 0.43 (0.64–2.92).

The diagnoses of acquired PRCA and active stage of AS (the degree of arthritis was grade IV) were established. After

consultation with a rheumatologist, we began treatment of PRCA with cyclosporine 200 mg/d and prednisone 30 mg/d (0.5 mg/kg/d).^[11] Then, the cyclosporine dose was adjusted according to the serum concentration level, which reached a reasonable level after 1 week. Ten days later, the patient improved significantly with regard to his arthritis syndrome, and he could walk independently, but he was still dependent on transfusions with an increasing serum ferritin level of 2701.8 μ g/L, which indicated iron overload. The patient received deferasirox to remove iron, but the treatment was halted 3 months later because of increasing ferritin levels and intolerable diarrhea. Due to untreatable anemia and a successful effect in PRCA associated with systemic lupus erythematosus (SLE),^[4] we added danazol 200 mg twice per day and then rHuEPO (40,000 IU/w) via subcutaneous injection. Two months later, the patient's reticulocyte percentage was 1.48% and the absolute reticulocyte count 33,300/ μ L. Consequently, the patient was transfusion-independent and his hemoglobin increased gradually. When his hemoglobin was 9.3 g/dL, rHuEPO dose decreased to 10,000 IU once a week. When his hemoglobin level was 14.0 g/dL, he stopped rHuEPO injections. During the treatment, the patient gained weight and exhibited a mildly elevated creatinine level, but experienced significant reduction in pain and could walk independently. After 18 months, the patient's hemoglobin and reticulocyte levels remained normal, so the response evaluation was complete remission.^[2] We gradually reduced the dose of prednisone to 7.5 mg/d as a maintenance measure, while adjusting the dose of cyclosporine to maintain the serum level above 100 ng/ml (Fig. 2). Meanwhile, the T lymphocyte subpopulation showed a better ratio of CD4/CD8 (0.52) with 3.31% (3.91–9.73%) Treg cells. The cytokine level of

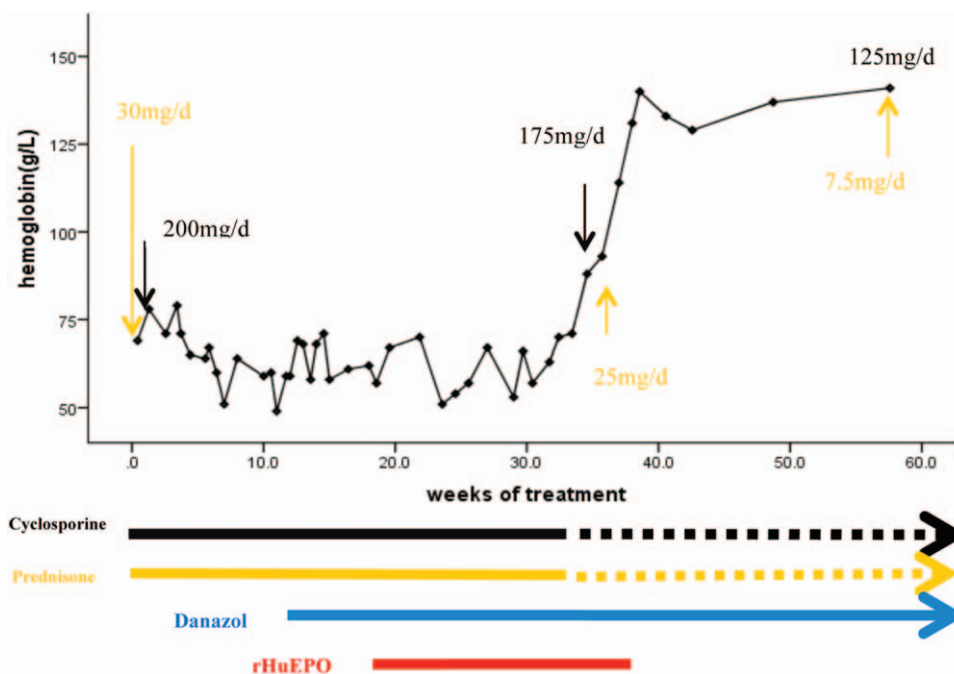


Figure 2. Timeline of treatment and changes of hemoglobin. The black, yellow and blue arrows indicated the continued taking of cyclosporine, prednisone and danazol respectively. The red line indicated the treatment duration of rHuEPO.

IL-10 was 9.02 pg/ml (0–5 pg/ml) while TNF- α and IL-4 levels were normal.

3. Discussion

In this case, there was no evidence of other causes of PRCA such as thymoma, lymphoproliferative diseases, hemolysis, infection, or serious malnutrition. Acquired PRCA can be immunological, although not always antibody-mediated. Since other autoimmune/collagen vascular disorders can result in PRCA, we postulated that AS itself or the related drugs can also cause PRCA. A review of literature revealed 6 cases of drugs induced pure red cell aplasia or aplastic anemia (including sulfasalazine, tripterygium wilfordii, and leflunomide).^[5–8] The clinical data of these cases were summarized in Table 1. According to the literature, among the drugs used by this patient, sulfasalazine could induce acquired PRCA,^[1,5,6,9] while tripterygium wilfordii and leflunomide could induce aplastic anemia (AA), which was associated with a drug-induced hematotoxic effect or T-cell-independent mechanism.^[7,8,10] This patient had taken sulfasalazine (dosage unknown), tripterygium wilfordii tablets (48 μ g/day) for 7 years. During that period his hemoglobin was nearly normal. Meanwhile, according to the data these drugs resulted in an acute reversible AA with an average of 30 days.^[8,10] Therefore, we concluded that his PRCA was not related to sulfasalazine or tripterygium wilfordii tablets. During the 1-year treatment with traditional Chinese medicine that contained leflunomide (20 mg/day), the patient gradually showed moderate to severe anemia. Long-term application of leflunomide can cause AA, but not PRCA, with a dose of more than 20 mg/day and is usually reversible after stopping the drug.^[7] However, 5 months after cessation of these 3 drugs, there was no sign of auto-recovery of hemoglobin or reticulocytes. In this case, the possibility of drug-induced acquired PRCA was small.

Studies have shown that Th1 (IFN- γ , TNF- α) is significantly increased with Th2 (IL-4, IL-10) and that Treg cells decrease in an active AS group compared with a normal control group, but this can be reversed after treatment.^[11,12] Since cytokines of IFN- γ and TNF- α are hematopoietic negative regulators they can inhibit bone marrow hematopoiesis, which may lead to PRCA. We regret that we did not measure the cytokine level at initial diagnosis, but with the recovery of PRCA and control of AS, the cytokine results showed that the IL-10 level was higher, while TNF- α and IL-4 levels were normal, which indicated a correction with Th1/Th2 cells. We also cannot exclude that there was an antibody-mediated mechanism in this case since we did not detect EPO autoantibodies.

Above all, active AS itself can induce PRCA, and abnormal T-cell immunity is the main pathogenesis of PRCA. After immunosuppressive treatment with cyclosporine and steroid, and hematopoietic stimulation therapy with danazol and rHuEPO, the patient had better control over his AS pain and PRCA. The use of rHuEPO in PRCA is still inconclusive, but De Marchi PN et al^[13] believe that rHuEPO can be administered in cases where the immunosuppressants do not provide the desired effect. The literature reports that although the serum EPO level of patients with chronic disease anemia increases with the severity of anemia, it is still relatively insufficient.^[13] The patient had a history of AS for many years and had been suffering from anemia since 2016. We could not exclude the existence of chronic anemia caused by autoimmune diseases, so we administered rHuEPO to this patient after 118 days of immunosuppressive treatment. In the end, it was an effective treatment and the patient recovered from his PRCA. Since we postulated that it was active AS-induced PRCA, we suggested that the patient participate in clinical trials with inhibitors of tumor necrosis factors (TNFi) or other target therapies to treat his AS; however, it was reported that cyclosporine was consistently effective in controlling the

Table 1
Characteristics of patients with drug-induced pure red cell aplasia or aplastic anemia in the literature.

Source	Age/Sex	Pathogenic drugs	Drugs duration and dosage	Dignosis	Treatment given	Outcome
Dunn ^[5]	31/F	Sulphasalazine	3 g/d for 6 weeks	Drug-induced PRCA	Sulphasalazine was withdrawn and gave transfusions.	Survived
Sheehan ^[6]	22/F	Sulphasalazine	2 g/d for 8 weeks and 4 g/d for 5 weeks	Drug-induced PRCA	Gave transfusions and stopped sulphasalazine. The hemoglobin level reached normal at day 140 after discontinuation of the drug.	Survived
Wüsthof ^[7]	32/F	Leflunomide	20 mg/d for 30 days	Drug-induced AA	Stopped leflunomide and started cholestyramine. Gave transfusions, antibiotics and antifungal agents. Because of severe aplasia over months, allo-HSCT was taken and clinical symptoms improved.	Survived
Feng ^[8]	70/M	Tripterygium wilfordii	90 mg/d for 22 days	Drug-induced AA	After 10 days of stopped tripterygium wilfordii, the blood routine returned to normal.	Survived
	26/M	Tripterygium wilfordii	60 mg/d for 30 days	Drug-induced AA	Stopped medications, gave transfusions and antibiotics. Ten days later, the blood routine started recover.	Survived
	35/F	Tripterygium wilfordii	60 mg/d for 4 months	Drug-induced AA	Gave transfusions, G-CSF, CsA. After 3 months, the bone marrow returned to normal.	Survived

AA=aplastic anemia, F=female, M=male, PRCA=pure red blood cell aplasia.

peripheral arthritis associated with ankylosing spondylitis just alike this patient.^[14]

In summary,

1. acquired PRCA can be secondary to AS,
2. cyclosporine is effective in controlling AS arthritis syndrome and
3. in addition to immunosuppressants, promotion of erythroid hematopoiesis is equally important.

However, the mechanism by which AS resulted in PRCA is unclear and may be related to AS activity and the induced T-cell immune dysfunction.

Author contributions

Data curation: Wei Wei, Yangzhi Zhao, Xinyue Liang.

Writing – original draft: Xianfang Shao.

Writing – review & editing: Wei Wei, Qiuju Liu.

References

- [1] Means RT Jr. Pure red cell aplasia. *Blood* 2016;128:2504–9.
- [2] Balasubramanian SK, Sadaps M, Thota S, et al. Rational management approach to pure red cell aplasia. *Haematologica* 2018;103:221–30.
- [3] De Marchi PN, Sueur Vieira ANL, Antunes Ribeiro JF, et al. Use of nandrolone decanoate in treatment of pure red cell aplasia secondary to diclofenac administration: a case report. *Top Companion Anim Med* 2017;32:44–7.
- [4] Chan AY, Li EK, Tam LS, et al. Successful treatment of pure red cell aplasia associated with systemic lupus erythematosus with oral danazol and steroid. *Rheumatol Int* 2005;25:388–90.
- [5] Dunn AM, Kerr GD. Pure red cell aplasia associated with sulphasalazine. *Lancet* 1981;2:1288.
- [6] Sheehan T, Tansey P, Cochran KM, et al. Inflammatory bowel disease, anaemia and sulphasalazine. *Clin Lab Haematol* 1985;7:275–8.
- [7] Wüsthof M, Smirnova A, Bacher U, et al. Severe aplastic anaemia following leflunomide therapy. *Rheumatology (Oxford)* 2010;49:1016–7.
- [8] Feng Guoan, Guo Nongjian, Dong Xuefu, et al. Report of 3 cases of aplastic anemia caused by tripterygium wilfordii and literature review. *J Clin Hematol* 2005;18:42–4.
- [9] Thompson DF, Gales MA. Drug-induced pure red cell aplasia. *Pharmacotherapy* 1996;16:1002–8.
- [10] Pyatt DW, Yang Y, Mehos B, et al. Hematotoxicity of the chinese herbal medicine Tripterygium wilfordii hook f in CD34-positive human bone marrow cells. *Mol Pharmacol* 2000;57:512–8.
- [11] Wang C, Liao Q, Hu Y, et al. T lymphocyte subset imbalances in patients contribute to ankylosing spondylitis. *Exp Ther Med* 2015;9:250–6.
- [12] Dao AT, Yamazaki H, Takamatsu HC, et al. Cyclosporine restores hematopoietic function by compensating for decreased Tregs in patients with pure red cell aplasia and acquired aplastic anemia. *Ann Hematol* 2016;95:771–81.
- [13] Kato Y, Takagi C, Tanaka J, et al. Effect of daily subcutaneous administration of recombinant erythropoietin on chronic anemia in rheumatoid arthritis. *Intern Med* 1994;33:193–7.
- [14] Géher P, Gömör B. Repeated cyclosporine therapy of peripheral arthritis associated with ankylosing spondylitis. *Med Sci Monit* 2001;7:105–7.