

Superficial Temporal Artery Pseudoaneurysm following Midface Thread-lift

Yosuke Niimi, MD, PhD*
 Nami Hayakawa, MD*
 Wataru Kamei, MD, PhD*
 Keijiro Hori, MD, PhD*
 Yu Niimi, MD†
 Takashi Honda, MD, PhD*
 Hiroyuki Sakurai, MD, PhD*

Summary: Facial thread-lifting has been popular because of its ease and safety with short down time. However, many physicians perform the procedure in cosmetic clinics, which can result in several complications. This report describes the surgical treatment of iatrogenic superficial temporal artery pseudoaneurysm (STAP) following thread-lifting. A 27-year-old man developed a painless, pulsating soft mass in the pre-auricular region after undergoing a thread-lift in a private cosmetic clinic 3 months before being referred to the authors' hospital. The mass was diagnosed as a STAP, using magnetic resonance imaging. The pseudoaneurysm was resected completely, and the superficial temporal artery was microsurgically reconstructed. Although there are some surgical procedures for treating STAP, such as surgical resection and embolization, the former is considered the first choice. Physicians should be trained before performing thread-lifting and must know the possibility of an iatrogenic STAP appearing after the procedure and the face and neck anatomy to prevent complications. (*Plast Reconstr Surg Glob Open* 2021;9:e3524; doi: 10.1097/GOX.0000000000003524; Published online 15 April 2021.)

Although thread-lifting is indicated for patients with temporarily improved mild facial ptosis, those with early laxity may not be good candidates or may choose not to undergo the surgery. Thread-lifting has become popular, as it features minimal invasiveness and a shortened down time and allows physicians to easily perform surgery.¹ There are wide selections of threads, including barb and cone types, as well as various thread-handling procedures that allow surgeons to select the direction of the threads' cogs and the direction of the inserted thread.²

Although the thread-lifting procedure is considered easy, numerous complications have been reported. This case report describes the surgical treatment of a rare iatrogenic superficial temporal artery (STA) pseudoaneurysm (STAP) following a facial thread-lifting cosmetic procedure and details measures that can prevent complications.

From the *Department of Plastic and Reconstructive Surgery, Tokyo Women's Medical University, Tokyo, Japan; and †Center for Multiphasic Health Testing and Services, Mitsui Memorial Hospital, Tokyo, Japan.

Received for publication October 4, 2020; accepted February 14, 2021.

Copyright © 2021 The Authors. Published by Wolters Kluwer Health, Inc. on behalf of The American Society of Plastic Surgeons. This is an open-access article distributed under the terms of the Creative Commons Attribution-Non Commercial-No Derivatives License 4.0 (CCBY-NC-ND), where it is permissible to download and share the work provided it is properly cited. The work cannot be changed in any way or used commercially without permission from the journal.

DOI: 10.1097/GOX.0000000000003524

CASE PRESENTATION

A 27-year-old man with no contributory history, including connective tissue disease or hematologic disease such as von Willebrand disease, developed a soft pulsating mass measuring 20 × 20 mm in the left pre-auricular region (Fig. 1). He had undergone midface thread-lifts using a total of 4 barb-type threads in a private cosmetic clinic 3 months before being referred to the authors' hospital. The threads were inserted from the temporal region to the cheek. Light ecchymosis was visible only around the auricular region. One week after the procedure, he felt a mass pulsating at the pre-auricular region. He visited another hospital, and the mass was examined by enhanced magnetic resonance imaging. Thereafter, he was referred to the authors' hospital. The mass was diagnosed as a STAP with thrombus on enhanced MRI (Fig. 2). Therefore, surgical resection of the STAP was planned under general anesthesia because the mass had rapidly increased in size over the previous 2 weeks. A pre-auricular incision was made on the left side of the face, and the subcutaneous tissue on the mass was undermined widely. The pulsating mass was connected to the STA with a thrombus, a thread pierced the pulsating mass (Fig. 3), and the mass was diagnosed as a pseudoaneurysm. After the STA was ligated at the proximal and distal sides of the pseudoaneurysm, the mass was resected completely from the superficial temporal fascia and end-to-end anastomosis of the

Disclosure: The authors have no financial interest to declare in relation to the content of this article.

Related Digital Media are available in the full-text version of the article on www.PRSGlobalOpen.com.

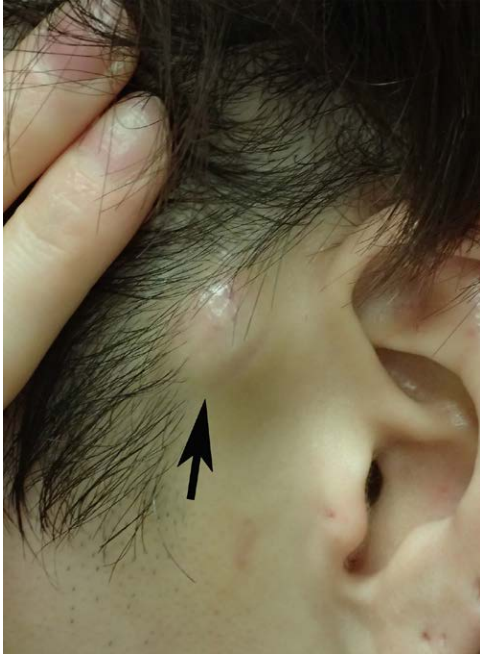

Fig. 1. Appearance of a soft mass on the left pre-auricular region of a 27-year-old man. A pulsatile soft cutaneous mass measuring 20 × 20 mm was found on the left pre-auricular region (black arrow).

STA was microsurgically performed with 9-0 nylon but no vein grafting (Fig. 4). No recurrence was observed for 3 months after surgery, and reperfusion was confirmed by enhanced computed tomography (CT) 2 weeks after surgery. (See figure, Supplemental Digital Content 1, which displays postoperative findings and enhanced CT. CT shows the reperfusion of superficial temporal artery (yellow arrow). <http://links.lww.com/PRSGO/B622>.)

DISCUSSION

This report describes a rare case of iatrogenic STAP following a thread-lifting procedure. STAP is a rare

pseudoaneurysm that mainly appears in the temporal region.³ In this study, STAP appeared in the main STA, which was quite rare. A pseudoaneurysm is a deformation of the disrupted arterial wall caused by blunt and penetrating trauma or can have iatrogenic reasons.⁴ In this study, because the thread pierced through at the point where the mass was found, the diagnosis was pseudoaneurysm. A few iatrogenic pseudoaneurysms are found in the femoral artery, radial artery, and forearm venous following blood sampling.⁵ An iatrogenic STAP may appear during surgery for scaphocephaly, tumor resection, mandibular condylar fracture, and nerve stimulator placement for trigeminal nerve examination.⁶ In the field of cosmetic medicine, although there are a few cases of STAP following face-lifting surgery⁷ and botulinum toxin injection,⁸ only 1 report described the diagnosis of STAP appearing after a thread-lift.⁹ Although thread-lifts reportedly feature minimal complications, mild complications such as skin dimpling and visible threads to severe complications such as infection and Stenson's duct rupture have been reported.¹⁰

The possible mechanism of STAP formation with threads is as follows: An STA, which might preexist in the subcutaneous tissue on the superficial layer of the temporal fascia in the auricular region, was injured by an inserted thread, resulting in a hematoma. Temporal muscle movement induced by chewing in daily life could allow the thread to move deeply into the STA, the internal pressure of the STA to increase, and the vessel wall of the damaged artery to be dysfunctional, resulting in a pseudoaneurysm. In this study, the patient reported bleeding from the insertion point immediately after thread insertion and light ecchymosis, and during STAP resection surgery, the thread pierced the artery, indicating that the artery could be injured by the inserted thread.

In 1977, Inoue et al reported the usefulness of imaging instruments (including CT, magnetic resonance imaging, Duplex scan, and selective angiography) for diagnosing STAP.³ Corvino et al also showed the usefulness of duplex ultrasound imaging devices because of

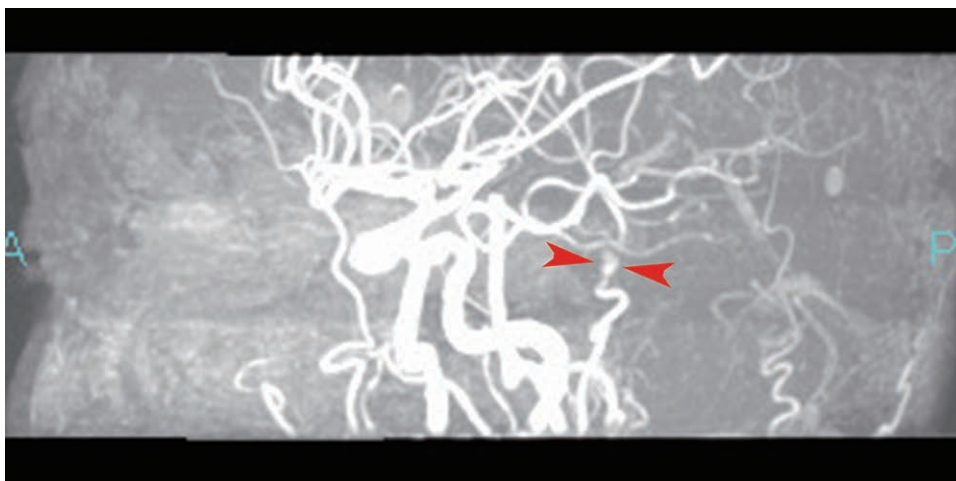


Fig. 2. Preoperative enhanced magnetic resonance imaging taken by the previous hospital. The 2 red arrowheads show a pseudoaneurysm in the left STA. A and P indicate the anterior and posterior sides of head, respectively.

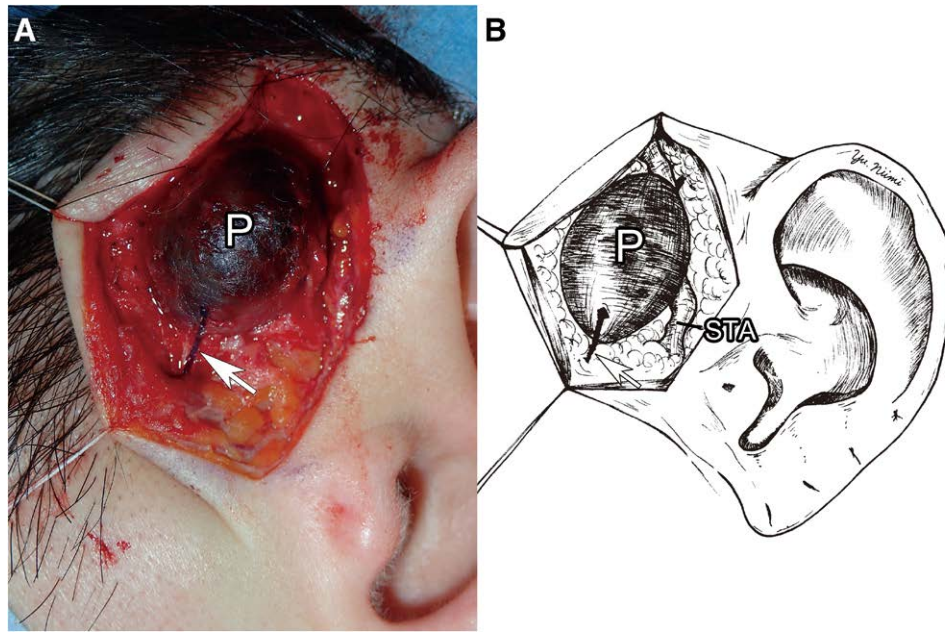


Fig. 3. Intraoperative findings during the soft mass resection. A, Pulsating STA pseudoaneurysm (P) with thrombus was observed after making the pre-auricular incision. A thread was found to penetrate the pseudoaneurysm (white arrows). B, Schematic illustration shows the geometry of STA and P.

their noninvasiveness for diagnosing STAP.⁹ Hong et al reported that selective angiography is useful for diagnosing STAP.¹¹

Symptoms of STAP (including pulsatile pain, hemorrhage, headache, ear discomfort, and cosmetic defects)

have been reported.¹² Treatments for STAP include manual compression, embolization, and surgical removal. Although Hong et al reported a successful coil embolization for treating STAP in the posterior branch in the temporal region,¹¹ the surgical method was not applicable to the STAP in this study because of the appearance of a conspicuous unfavorable scar in the temporal region.

Therefore, the present case was treated with surgical resection because (1) STAP was located in the subcutaneous layer, making a surgical approach easy; (2) venous clots were already identifiable in the STAP, and embolization was considered contraindicated; and (3) the scar of the pre-auricular region is known to give a good outcome. Although a true facelift incision is used for cosmetic patients, this patient had a pierce hole in the tragus where a possible face line incision would be made. The pre-auricular incision is frequently used for parotidectomy as a variation of Blair's incision, and the resulting scar is inconspicuous. As the purpose of the surgery was to completely remove a pseudoaneurysm and the incision allowed surgeons to more easily approach it, we selected a pre-auricular incision. The surgical resection of a STAP can be considered the treatment of choice.

With a high collateral circulation, STAs have been used as donor and recipient vessels in reconstructive and neurological surgeries.^{13,14} To prevent STAP following thread-lifting, when bleeding from the STA was observed during the procedure, immediate thread removal and STA compression were recommended.

To prevent STA injury, this study made the following recommendations for physicians who attempt to perform thread-lifting. Physicians should always (1) search for STAs by palpation before inserting the threads; (2) prevent the thread from piercing the STAs; and (3) attend a

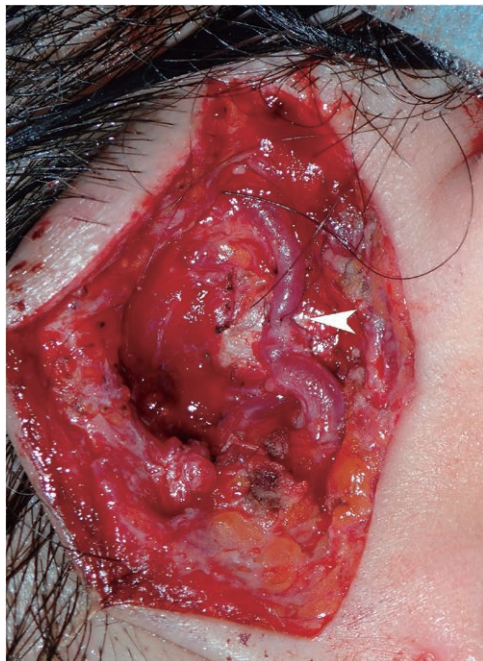

Fig. 4. Intraoperative findings after STA was anastomosed. After the aneurysm was resected, STA was anastomosed by the end-to-end anastomosing technique with a 9-0 nylon, using a microscope. Favorable reperfusion was found after anastomosis (white arrowhead).

thread-lift seminar in which certified esthetic surgeons or trained physicians teach them how to perform the thread-lift procedure safely.

As a limitation, this study reported only 1 case. To determine the rates of complications and their prevention, multiple institutional studies should be performed with larger numbers of cases.

CONCLUSIONS

We reported a rare case of iatrogenic STAP following thread-lifting. Surgical excision and reconstruction of the STA were the most appropriate treatments for STAP. All physicians practicing cosmetic medicine should be mindful of STAP as a possible complication of thread-lifting procedures and should be properly trained to perform them.

Yosuke Niimi, MD, PhD

Department of Plastic and Reconstructive Surgery
Tokyo Women's Medical University
8-1 Kawada-cho, Shinjuku-ku
Tokyo 162-8666
Japan
E-mail: niimi.yosuke@twmu.ac.jp

ACKNOWLEDGMENTS

This study was carried out in accordance with the World Medical Association Declaration of Helsinki (June 1964) and subsequent amendments. The patients voluntarily gave written informed consent to participate in this study.

REFERENCES

- Gülbitti HA, Colebunders B, Pirayesh A, et al. Thread-lift sutures: still in the lift? A systematic review of the literature. *Plast Reconstr Surg*. 2018;141:341e–347e.
- Paul MD. Barbed sutures in aesthetic plastic surgery: evolution of thought and process. *Aesthet Surg J*. 2013;33(3 suppl):17S–31S.
- Inoue Y, Iwamoto T, Kitoh M, et al. Traumatic aneurysm of the temporal artery: a report of five cases. *J Dermatol*. 1997;24:246–248.
- Isaacson G, Kochan PS, Kochan JP. Pseudoaneurysms of the superficial temporal artery: treatment options. *Laryngoscope*. 2004;114:1000–1004.
- Niimi Y, Yamaki T, Hori K, et al. Successful surgical resection of iatrogenic antecubital venous pseudoaneurysm following venipuncture: a 2-case report. *Clin Med Insights Case Rep*. 2017;10:1179547617737790.
- Ellis JA, Gill BJ, Pisapia D, et al. Superficial temporal artery pseudoaneurysm following trigeminal nerve stimulator placement. *Neuromodulation*. 2014;17:788–790.
- Lin K, Matarasso A, Edelstein DR, et al. Superficial temporal artery pseudoaneurysm after face lift. *Aesthet Surg J*. 2004;24:28–32.
- Prado A, Fuentes P, Guerra C, et al. Pseudoaneurysm of the frontal branch of the superficial temporal artery: an unusual complication after the injection of botox. *Plast Reconstr Surg*. 2007;119:2334–2335.
- Corvino A, Catalano O, Corvino F, et al. Superficial temporal artery pseudoaneurysm: what is the role of ultrasound? *J Ultrasound*. 2016;19:197–201.
- Winkler E, Goldan O, Regev E, et al. Stensen duct rupture (sialocele) and other complications of the Aptos thread technique. *Plast Reconstr Surg*. 2006;118:1468–1471.
- Hong JT, Lee SW, Ihn YK, et al. Traumatic pseudoaneurysm of the superficial temporal artery treated by endovascular coil embolization. *Surg Neurol*. 2006;66:86–88.
- De Vogelaere K. Traumatic aneurysm of the superficial temporal artery: case report. *J Trauma*. 2004;57:399–401.
- Hansen SL, Foster RD, Dosanjh AS, et al. Superficial temporal artery and vein as recipient vessels for facial and scalp microsurgical reconstruction. *Plast Reconstr Surg*. 2007;120:1879–1884.
- Vilela MD, Newell DW. Superficial temporal artery to middle cerebral artery bypass: past, present, and future. *Neurosurg Focus*. 2008;24:E2.