

Review

Maxillary artery based flaps for oral cavity reconstruction, a review

Amin Rahpeyma^a, Saeedeh Khajehahmadi^{b,*}^a Oral and Maxillofacial Diseases Research Center, Mashhad University of Medical Sciences, Mashhad, Iran^b Dental Research Center, Mashhad University of Medical Sciences, Mashhad, Iran

HIGHLIGHTS

- Flaps based on maxillary artery branches can be used for oral cavity reconstruction but there is any review in this topic.
- Seven soft tissue flaps based on the maxillary artery branches are available.
- Flaps based on the maxillary artery branches are strongly recommended when the facial artery has been ligated/sacrificed.
- Soft tissue flaps derived from maxillary artery, can be used for facial reconstruction even after radiotherapy to the face.
- Face lymphatic is always along the facial vein, so maxillary artery based flaps are oncological safe flaps.

ARTICLE INFO

Article history:

Received 10 January 2017

Received in revised form

12 June 2017

Accepted 17 June 2017

Keywords:

Maxillary artery

Temporal flap

Palatal flap

ABSTRACT

Background: There are different flaps based on the branches of the maxillary artery. Flaps based on the maxillary artery branches can be used for oral cavity reconstruction in selected cases, but there is lack of comprehensive review in this topic.

Methods: A literature review was performed on Medline for maxillary artery based flaps and oral cavity reconstruction. Surgical techniques for each possible variant of maxillary artery based flaps and an example of each situation for oral cavity reconstruction is explained.

Result: Five variants of soft tissue flaps based on maxillary artery branches are presented. Some of them such as temporal flap, superiorly based masseter flap, palatal flap and posteriorly based buccinator myomucosal flap are famous flaps, while posteriorly based inferior turbinate flap is less noticed for oral cavity reconstruction. Nasoseptal and infraorbital based flaps are two other maxillary artery based flaps but have no role in oral cavity reconstruction.

Conclusion: Maxillary artery based flaps should be considered as an option especially in previously radiotherapy/surgically operated patients with facial vessels sacrifice.

© 2017 The Authors. Published by Elsevier Ltd on behalf of IJS Publishing Group Ltd. This is an open access article under the CC BY-NC-ND license (<http://creativecommons.org/licenses/by-nc-nd/4.0/>).

Contents

1. Introduction	33
2. Material and methods	33
3. Result	33
4. Discussion	35
5. Conclusion	36
Ethical approval	36
Funding	36
Author contribution	36
Conflict of interest	36
Guarantor	36
Consent	36

* Corresponding author. Dental Research Center of Mashhad University of Medical Sciences, Vakilabad Blvd, Mashhad, Iran.

E-mail address: khajehahmadis@mums.ac.ir (S. Khajehahmadi).

Registration of research studies	36
References	36

1. Introduction

Axial pattern pedicled flaps, uses the tissue with guaranteed blood supply, by including a named artery in flap base and along the flap length [1]. Maxillary artery is deeply located in the face, so remains intact for vascularization of the face even in the case of neck dissection and radiotherapy [2]. Flaps based on the maxillary artery branches can be used for orofacial reconstruction in selected cases, but there is lack of comprehensive review in this topic. Facial artery nourishes the face from the anterior direction and is correlated with blood supply of expression muscles. End branches may penetrate facial bones while maxillary artery nourishes the face deeply and contains nutrient vessels of masticator muscles and jaw bones. These two arteries anastomose with each other extensively. Maxillary artery branches are often accompanying with sensory nerve branches of maxillary or mandibular nerves, so pedicled flaps based on these arteries are neurovascular flaps with benefits of sense perceptions if there is no plan to do pedicle division. In this article, all possible variants of the soft tissue flaps based on the maxillary artery branches, are presented.

2. Material and methods

A literature review was performed on Medline for maxillary artery based flaps and oral cavity reconstruction. Surgical techniques, possible variants of maxillary artery based flaps; Indications, limitations and oncologic safety of these flaps were focused on. Authors experience with these flaps also is presented.

3. Result

Five variants of soft tissue flaps based on maxillary artery branches with an example for each situation are presented:

The patient was 55 year old male patient with post trauma palatal fistula adjacent to the right maxillary posterior edentulous space. Nasal side coverage was obtained from palatal turn over flaps. Posteriorly based buccinator myomucosal flap was used for oral side coverage (Fig. 1). Boundaries of this flap was one centimeter behind oral commissure anteriorly, beneath stensen duct superiorly and above mucobuccal fold inferiorly. Depth of dissection was just below the buccinator muscle.

The patient was 40-year female patient with maxillary odontogenic myxoma in left upper quadrant that had perforated cortical plates and invaded to soft tissue. Posteriorly based inferior turbinate flap was used for one-layer closure of palatal fistula from nasal side after surgical resection of pathologic lesion (Fig. 2). Inferior turbinate bone was removed from flap. Raw surface was faced toward the nasal cavity and flap boundaries were sutured to palatal and buccal mucosa edge to edge.

The patient was 68 year old male patient with mandibular ameloblastoma that had invaded to the soft tissue mucosa in retromolar region. Lateral mandibular defect with soft tissue loss was reconstructed with titanium reconstruction plate covered with the whole palatal mucosa, pedicled on the left greater palatal artery. Crestal incision was used in this edentulous patient and palatal mucosa was reflected in full thickness. Pivotal point of this flap was considered in left greater palatine foramen area. Incisive vessels as well as right greater palatine artery were ligated. This flap was

rotated 180° to cover the soft tissue defect (Fig. 3). Donor site healing was slow but uneventful.

The patient was 60 year old male patient with large oronasal fistula resulted from resection of the maxilla in posterior region. Hemicoronal incision was used to get access to temporal muscle. This muscle and overlying fascia was elevated from temporal fossa attached only to coronoid process. Temporal flap was harvested and anterior part was used for palatal reconstruction. Posterior half was transposed anteriorly to prevent temporal hollowing (Fig. 4).

The patient was 55 year female with buccal mucosa squamous cell carcinoma, extended to the mandibular alveolar ridge. After surgical resection with wide margins, the resected mucosa was reconstructed with superiorly based masseter flap (Fig. 5). Inferior head of masseter muscle was detached from mandibular bone by blunt end of a periosteal elevator. Outer surface of this muscle was dissected from overlying tissue by long beaked hemostat.

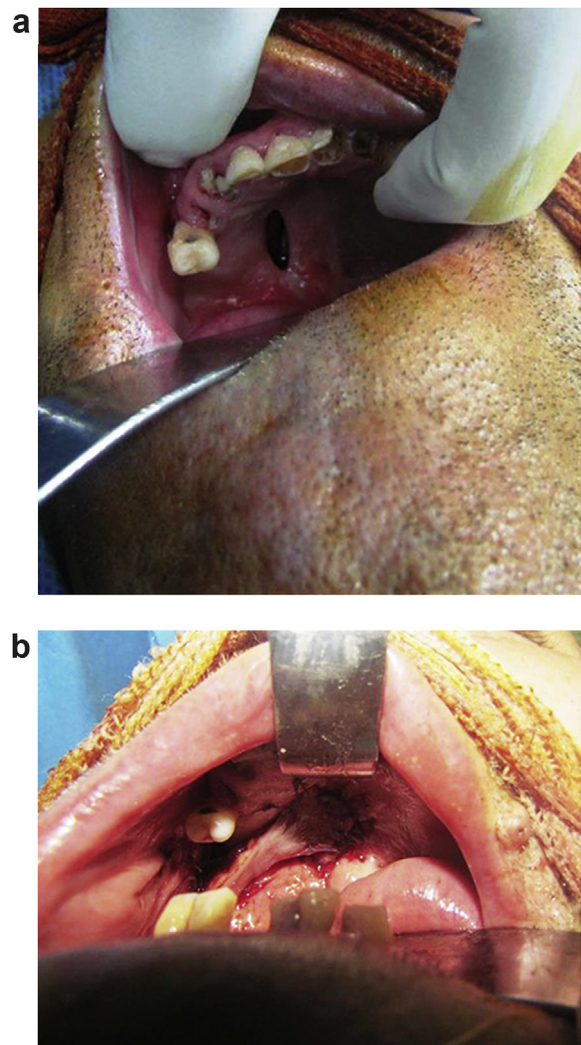


Fig. 1. a) Palatal fistula from palatal fracture in a trauma patient. b) Posteriorly based buccinator myomucosal flap is used for reconstruction. This flap needs pedicle division.

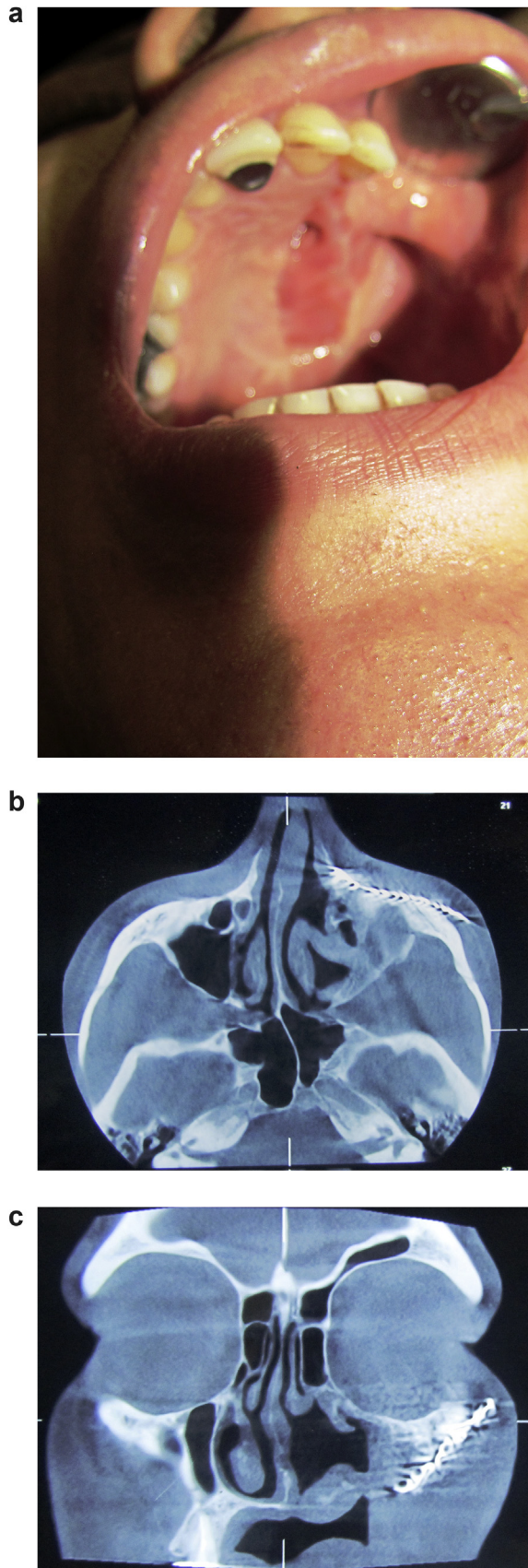


Fig. 2. a) Repaired palatal fistula with inferior turbinate flap. b) Posteriorly based inferior turbinate flap. c) Fistula is closed in one layer by this flap from nasal side.

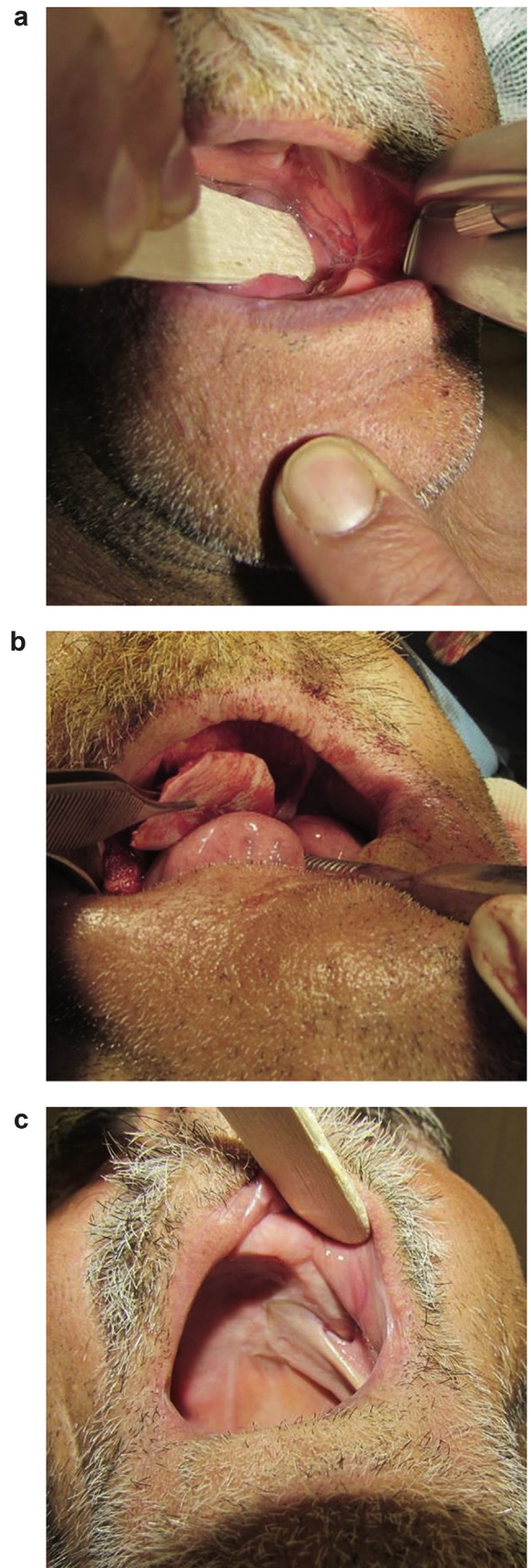


Fig. 3. a) Soft tissue invasion of retromolar region. b) Palatal flap hinged on the left greater palatine artery. The right greater palatine artery is ligated. c) The flap is rotated and transpositioned to cover the mucosal defect. Note to the healed palatal Donor site.

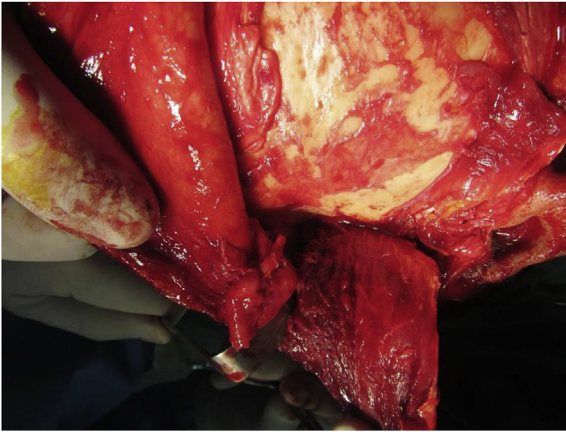


Fig. 4. Temporal muscle is elevated from the temporal bone.

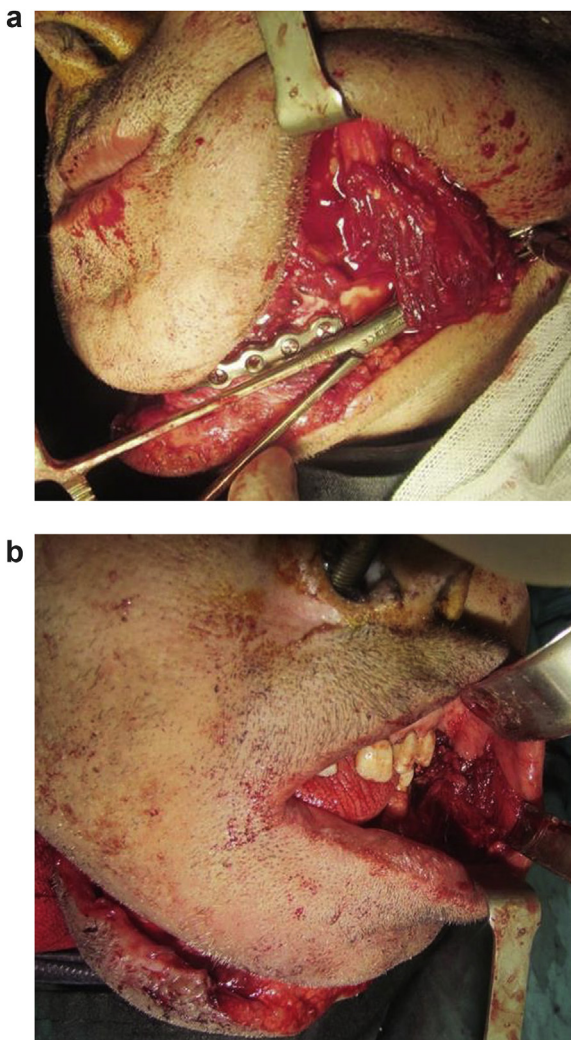


Fig. 5. a) Detaching the insertion of the masseter muscle to the mandibular ramus. b) Reconstructed inner cheek.

4. Discussion

There are seven soft tissue flaps based on the maxillary artery branches [3–8]. Five flaps can be used for oral cavity reconstruction. Table 1 shows these flaps and their nutrient arteries. Based on

limited arch of rotation, these flaps are used for posterior oral cavity reconstructions.

Maxillary artery is one of the end branches of external carotid artery with the largest diameter [3]. It travels along the branches of the mandibular and maxillary nerves and nourishes oral, nasal and pharyngeal cavities as well as part of the skin in anterior face [4]. Maxillary artery branches extensively anastomosed with facial and transverse facial arteries [5,6]. Maxillary artery has three main segments including; mandibular, pterygoid and sphenopalatine [7]. Branches that can be used for flap elevation all are derived from second and third parts (pterygoid and sphenopalatine).

Posteriorly based buccinator myomucosal flap was first introduced in 1989 by Bozola [8]. Pivotal point is near the pterygomandibular raphe and mainly is used for post palatoplasty oronasal fistula closure or correction of velopharyngeal insufficiency in cleft patients [9,10]. This flap could pass to palate through edentulous gap or by the aid of bite block in closed arch mouth [11]. Accompanying of buccinator branch of mandibular nerve and buccal artery gives this flap unique: a neurovascular flap. Mucosal island variant of this flap increases flap mobility slightly.

Temporal flap can be used in the form of muscle, myofascial and myo-osseous flaps for orofacial reconstruction. When it is transferred to the oral cavity, healing is through secondary epithelialization of the muscle that is covered by granulation tissue. Soft tissue contraction is the result [12]. Blood supply is from deep temporal arteries and vertical splitting of the muscle is possible in between these two arteries [13].

Inferior turbinate flap is commonly used in skull base surgeries to prevent CSF leakage after neurosurgical procedures or trauma [14]. In oral cavity posteriorly pedicled variant of this flap can be used for reconstruction of medium sized palatal defect [15]. It has another role in nasal floor reconstruction in wide alveolar gap in cleft patients [16].

Palatal flap is a mucoperiosteal flap based on greater palatine artery. It can be used for palatal, tonsillar and retromolar reconstruction [17]. This flap has vital role in management of chronic persistent oroantral fistula [18]. Delayed donor site healing is drawback of this flap.

Masseter muscle is nourished by seven arteries [19]. This muscle flap is called superiorly based when inferior attachment of this muscle is released from outer mandibular angle cortex and nourished mainly by masseteric artery. It can be used for buccal and posterior alveolar ridge reconstruction [20]. Superiorly based and island variant can be used for repairing oropharyngeal defects. Split masseter transposition flap can be used for facial animation and oral commissure reconstruction [21].

Flaps based on the maxillary artery branches are strongly recommended when the facial artery has been ligated/sacrificed [22]. Thanks to deep location, maxillary artery is also resistance to the side effect of radiotherapy on endothelial cells [23]. So soft tissue flaps derived from maxillary artery, can be used for facial reconstruction even after radiotherapy to the face [24].

Head and face lymphatic is always along the facial vein, so maxillary artery based flaps are oncological safe flaps in the case of malignancy [25]. Maxillary artery supports both hard and soft tissue in the maxillofacial region, while the facial artery is mainly focused on nourishing soft tissue of the face [26]. Maxillary artery based flaps are not reliable when external carotid artery is ligated or internal maxillary artery is clamped [27].

Nasoseptal and infraorbital based flaps are two other maxillary artery based flaps but have no role in oral cavity reconstruction. Nasoseptal flap is based on posterior septal artery. It is a branch of sphenopalatine artery; intranasal end branch of maxillary artery. This flap is commonly used for skull base reconstruction [19]. Infraorbital artery based flap is an axial pattern superiorly based

Table 1
Soft tissue flaps based on the maxillary artery branches used for oral cavity reconstruction.

Maxillary artery branch	Flap name	Flap composition	Example
Buccal artery	Posteriorly based buccinator flap (Bozola flap)	Myomucosal	Patient 1
Sphenopalatine artery	Posteriorly based inferior turbinate flap	Mucoperiosteal	Patient 2
Greater palatine artery	Palatal flap	Mucoperiosteal	Patient 3
Deep temporal arteries. (Anterior and posterior)	Temporal flap	Muscle flap	Patient 4
Superior masseteric artery	Masseter muscle cross over flap, superiorly based Masseter muscle island flap	Muscle flap	Patient 5

nasolabial flap that commonly is used for nasal reconstruction.

5. Conclusion

Maxillary artery based flaps should be considered as an option for oral cavity and facial reconstruction, especially in the previously radiotherapy/surgically operated patients with facial artery sacrifice.

Ethical approval

No needed.

Funding

This study was supported by a grant from the Vice Chancellor of Research of Mashhad University of Medical Sciences.

Author contribution

Study concept or design: Dr Rahpeyma.
Data collection: Dr Rahpeyma.
Writing the paper: Dr Rahpeyma.
Surgeon: Dr Rahpeyma.
Pathologist: Dr Khajehahmadi.
Corresponded: Dr Khajehahmadi.

Conflict of interest

No conflicts of interest.

Guarantor

This study was supported by a grant from the Vice Chancellor of Research of Mashhad University of Medical Sciences (grant number :922446).

Consent

Written patient consent has been obtained to publish clinical photographs.

Registration of research studies

2055.

References

- [1] T. Fabrizio, Facial artery flaps in facial oncoplastic reconstruction, *Facial Plast. Surg.* FPS 29 (2013) 333–339.
- [2] I. Dallan, R. Lenzi, S. Sellari-Franceschini, M. Tschabitscher, L. Muscatello, Temporalis myofascial flap in maxillary reconstruction: anatomical study and clinical application, *J. Cranio-Maxillo-Facial Surg. Off. Publ. Eur. Assoc. Cranio-Maxillo-Facial Surg.* 37 (2009) 96–101.
- [3] H. Orbay, M. Kerem, R.E. Unlu, A. Comert, E. Tuccar, O. Sensoz, Maxillary artery: anatomical landmarks and relationship with the mandibular subcondyle, *Plastic Reconstr. Surg.* 120 (2007) 1865–1870.
- [4] K. Antoniadis, N. Lasaridis, K. Vahstevanos, L. Hadjipetrou, V. Antoniadis, D. Karakasis, Superiorly based and island masseter muscle flaps for repairing oropharyngeal defects, *J. Cranio-Maxillo-Facial Surg. Off. Publ. Eur. Assoc. Cranio-Maxillo-Facial Surg.* 33 (2005) 334–339.
- [5] Z. Zhao, S. Li, Y. Yan, Y. Li, M. Yang, L. Mu, et al., New buccinator myomucosal island flap: anatomic study and clinical application, *Plast. Reconstr. Surg.* 104 (1999) 55–64.
- [6] N. Samman, L.K. Cheung, H. Tideman, The buccal fat pad in oral reconstruction, *Int. J. Oral Maxillofac. Surg.* 22 (1993) 2–6.
- [7] O. Akiyama, A. Gungor, E.H. Middlebrooks, A. Kondo, H. Arai, *Microsurgical Anatomy of the Maxillary Artery for Extracranial-intracranial Bypass in the Pterygopalatine Segment of the Maxillary Artery*, Clinical Anatomy, New York, NY, 2017.
- [8] A.R. Bozola, J.A. Gasques, C.E. Carriquiry, M. Cardoso de Oliveira, The buccinator musculomucosal flap: anatomic study and clinical application, *Plast. Reconstr. Surg.* 84 (1989) 250–257.
- [9] D. Franco, D. Rocha, M. Arnaut Jr., R. Freitas, N. Alonso, Versatility of the buccinator myomucosal flap in atypical palate reconstructions, *J. Cranio-Maxillo-Facial Surg. Off. Publ. Eur. Assoc. Cranio-Maxillo-Facial Surg.* 42 (2014) 1310–1314.
- [10] A. Rahpeyma, S. Khajehahmadi, Closure of huge palatal fistula in an adult patient with isolated cleft palate: a technical note, *Plast. Reconstr. Surg. Glob. Open* 3 (2015) e306.
- [11] A. Rahpeyma, S. Khajehahmadi, The posterior-based buccinator myomucosal flap (Bozola's flap), *Eur Ann Otorhinolaryngol Head Neck Dis.* (2017 May 24), <http://dx.doi.org/10.1016/j.anorl.2017.01.003> pii: S1879-7296(17)30094-7, Epub ahead of print.
- [12] A.O. Abubaker, M.B. Abouzgia, The temporalis muscle flap in reconstruction of intraoral defects: an appraisal of the technique, *Oral Surg. Oral Med. Oral Pathol. Oral Radiol. Endod.* 94 (2002) 24–30.
- [13] H. Nakajima, N. Imanishi, T. Minabe, The arterial anatomy of the temporal region and the vascular basis of various temporal flaps, *Br. J. Plast. Surg.* 48 (1995) 439–450.
- [14] M. Amit, J. Cohen, I. Koren, Z. Gil, Cadaveric study for skull base reconstruction using anteriorly based inferior turbinate flap, *Laryngoscope* 123 (2013) 2940–2944.
- [15] A. Rahpeyma, S. Khajehahmadi, Inferior turbinate flap for nasal-side closure of palatal fistula in cleft patients: technical note, *Plast. Reconstr. Surg. Glob. Open* 2 (2014) e265.
- [16] A. Rahpeyma, S. Khajehahmadi, The last resort for reconstruction of nasal floor in difficult-to-repair alveolar cleft cases: a retrospective study, *J. Cranio-Maxillo-Facial Surg. Off. Publ. Eur. Assoc. Cranio-Maxillo-Facial Surg.* 42 (2014) 995–999.
- [17] J.A. Jamali, Palatal flap, *Oral Maxillofac. Surg. Clin. N. Am.* 26 (2014) 305–311.
- [18] M.N. Awang, Closure of oroantral fistula, *Int. J. Oral Maxillofac. Surg.* 17 (1988) 110–115.
- [19] S.Y. Won, D.Y. Choi, H.H. Kwak, S.T. Kim, H.J. Kim, K.S. Hu, Topography of the arteries supplying the masseter muscle: using dissection and Sihler's method, *Clin. Anat. (New York, NY)* 25 (2012) 308–313.
- [20] C.R. Bande, A. Mishra, M.K. Gupta, M. Goel, M.J. Gawande, Utility of superiorly based masseter muscle flap for postablative retromaxillary reconstruction, *J. Oral Maxillofac. Surg. Off. J. Am. Assoc. Oral Maxillofac. Surg.* 75 (2017) 224 e1–e9.
- [21] Y. Demir, O. Latifoglu, R. Yavuzer, K. Atabay, Oral commissure reconstruction with split masseter muscle transposition and cheek skin flap, *J. Cranio-Maxillo-Facial Surg. Off. Publ. Eur. Assoc. Cranio-Maxillo-Facial Surg.* 29 (2001) 351–354.
- [22] V. Mani, A.K. Panda, Versatility of temporalis myofascial flap in maxillofacial reconstruction—analysis of 30 cases, *Int. J. Oral Maxillofac. Surg.* 32 (2003) 368–372.
- [23] M.M. Hanasono, D.S. Utley, R.L. Goode, The temporalis muscle flap for reconstruction after head and neck oncologic surgery, *Laryngoscope* 111 (2001) 1719–1725.
- [24] J.E. Smith, Y. Ducic, R. Adelson, The utility of the temporalis muscle flap for oropharyngeal, base of tongue, and nasopharyngeal reconstruction, *Otolaryngol. Head Neck Surg. Off. J. Am. Acad. Otolaryngol. Head Neck Surg.* 132 (2005) 373–380.
- [25] S.P. Edwards, S.E. Feinberg, The temporalis muscle flap in contemporary oral and maxillofacial surgery, *Oral Maxillofac. Surg. Clin. N. Am.* 15 (2003) 513–535 vi.
- [26] A. Rahpeyma, S. Khajehahmadi, Submental artery island flap in intraoral reconstruction: a review, *J. Cranio-Maxillo-Facial Surg. Off. Publ. Eur. Assoc. Cranio-Maxillo-Facial Surg.* 42 (2014) 983–989.
- [27] M.H. Rigby, R.E. Hayden, Regional flaps: a move to simpler reconstructive options in the head and neck, *Curr. Opin. Otolaryngol. Head Neck Surg.* 22 (2014) 401–406.