



Available online at www.sciencedirect.com

ScienceDirect

journal homepage: <http://ees.elsevier.com/jot>



ORIGINAL ARTICLE

Discordance in diagnosis of osteoporosis by quantitative computed tomography and dual-energy X-ray absorptiometry in Chinese elderly men



Xiao-ming Xu ^a, Na Li ^a, Kai Li ^a, Xiao-Yu Li ^b, Ping Zhang ^b, Yan-jiao Xuan ^a, Xiao-guang Cheng ^{a,*}

^a Department of Radiology, Beijing Jishuitan Hospital, No. 31 Xijiekoudongjie Street, Xicheng District, Beijing 100035, China

^b Department of Geriatric, Beijing Jishuitan Hospital, China

Received 30 May 2018; received in revised form 19 September 2018; accepted 28 November 2018
Available online 21 December 2018

KEYWORDS

Bone mineral density;
Dual X-ray
absorptiometry;
Osteoporosis;
Quantitative
computed
tomography

Abstract Objective: The objective of this study was to investigate the diagnostic discordance of osteoporosis by quantitative computed tomography (QCT) and dual-energy X-ray absorptiometry (DXA) in Chinese elderly men.

Methods: A total of 313 males older than 60 years, who underwent both spinal QCT and lumbar spine and hip DXA in our department, were included. The diagnostic criteria established by the World Health Organisation in 1994 were used for DXA to diagnose osteoporosis, and the criteria recommended by the International Society of Clinical Densitometry were used for QCT. The osteoporosis detection rate by the two techniques was calculated, and the difference was compared. The minor discordance was considered present when the different diagnostic classes between the two techniques were adjacent. Major discordance was present when the diagnosis by one technique was osteoporosis and the other was normal. The computed tomography images were reviewed by radiologists to assess whether vertebral fracture, aorta calcification or degeneration was present.

Results: In the 313 participants (mean age, 79.6 ± 7.2 years), the osteoporosis detection rate was 10.9% for DXA (lumbar spine and hip) and 45.1% for QCT, a significant difference ($p < 0.001$). The major discordance, minor discordance and concordance of diagnosis between the two techniques were seen in 8.3%, 50.8% and 40.9%, respectively. QCT detected osteoporosis better than DXA. The causes of this discordance were degeneration of spine, abdominal aorta calcification and vertebral fractures.

Conclusion: Our study demonstrated that discordance was common when using QCT and DXA to diagnose osteoporosis and that spinal degeneration, aorta calcification and fracture obscure

* Corresponding author.

E-mail address: xiao65@263.net (X.-g. Cheng).

the bone mineral density measurement of spine by DXA. QCT is a more sensitive method of choice to identify osteoporosis in elderly Chinese men.

The translational potential of this article: This study investigated the diagnostic discordance of osteoporosis by quantitative computed tomography (QCT) and dual-energy X-ray absorptiometry (DXA) in Chinese elderly men. The results demonstrated that QCT is a more sensitive method of choice to identify osteoporosis in elderly Chinese men. This work may help clinicians make an appropriate choice of technique for the accurate diagnosis of osteoporosis and identify the patients at high risk of osteoporosis who should be treated early to prevent fractures. This may influence the therapeutic plan and the overall prognosis of patients.

© 2018 The Authors. Published by Elsevier (Singapore) Pte Ltd on behalf of Chinese Speaking Orthopaedic Society. This is an open access article under the CC BY-NC-ND license (<http://creativecommons.org/licenses/by-nc-nd/4.0/>).

Introduction

Osteoporosis is defined as a systemic skeletal disease characterized by low bone mass and microarchitectural deterioration of bone tissue, with a consequent increase in bone fragility and susceptibility to fracture [1]. Osteoporotic fracture is one of the most severe diseases in the elderly with high morbidity and seriously decreased quality of life [2]. There are many similarities between male osteoporosis and female osteoporosis, but there are still significant gender differences in aetiology, pathology and epidemiology. Most studies have focused on osteoporosis in postmenopausal women, whereas male osteoporosis is relatively ignored and undiagnosed.

With the ageing population in China, the prevalence of osteoporosis-related fractures, including spine, hip and forearm fractures, might increase dramatically [3]. Patients at high risk of osteoporosis should be identified and treated early to prevent fractures. Osteoporotic fracture results from loss of bone strength, which relates to bone quality, bone density and bone geometry. Bone mineral density (BMD) is considered to be a surrogate for bone strength and is now regarded as the most important measurement for predicting osteoporotic fractures [4,5].

Measurement of BMD is a central component in the diagnosis of osteoporosis. Dual-energy X-ray absorptiometry (DXA) is a well-established technique for BMD assessment and has been widely used in clinical diagnosis. However, it expresses the results as areal density, including both cortical bone and trabecular bone. Quantitative computed tomography (QCT) is a truly three-dimensional technique for quantifying volumetric trabecular bone density that is not affected by spine degeneration and abdominal aortic calcification. Recently, QCT has been generally recognized for the diagnosis of osteoporosis [6,7].

The BMD results measured by DXA and QCT cannot be compared directly, and sometimes, the diagnosis indicated by BMD findings differs between the two techniques. This discordance may affect the diagnosis and therapeutic plan in an individual person. Therefore, we investigated the diagnostic discordance of osteoporosis between QCT and DXA in Chinese elderly men.

Materials and methods

Participants

The participants of our study were a convenience sample from the outpatients and inpatients of the Geriatrics department of Beijing Jishuitan Hospital between October 2011 and September 2014. A total of 313 consecutive elderly men underwent both spinal QCT and DXA in the spine and hip in our department within two months. All participants completed a standardized questionnaire before their scan (including age, medical history, drugs, smoking, etc.). Height, weight and body mass index (BMI, kg/m²) were measured. Study exclusion criteria included use of a bone active agent or hormone therapy, a history of multiple myeloma, rheumatoid arthritis, ankylosing spondylitis, systemic lupus erythematosus, connective tissue disease, metabolic and endocrine diseases and bone tumours.

BMD measurements by DXA

BMD data were obtained using a Prodigy DXA scanner (GE Healthcare, Madison, WI, USA) and analyzed using the manufacturer's software. Vertebrae from L1 to L4 and the left hip were scanned in the supine position using posterior-anterior projections. The femoral neck and total hip were selected as the regions of interest in BMD measurement in the hip. T-scores were based on the reference ranges published by Cheng et al. in 2007 [8]. The lumbar spine T-score and the lower T-score at the femoral neck and total hip sites were used to diagnose osteoporosis.

QCT measurements

Spine QCT images were obtained by using Aquilion 64-slice CT scanner (Toshiba Medical Systems, Tokyo, Japan) with a Mindways QCT Pro system (Mindways Software Inc., Austin, TX). Vertebrae from L1 to L4 were scanned in the supine position. Images were analyzed using the Mindways software. The BMD of L2-4 vertebral body was measured separately, and the mean value was calculated. An elliptical region of interest was placed in the central plane

with a thickness of 9 mm of the vertebral body in the trabecular bone area, avoiding the cortical bone of the vertebrae and the vertebral veins. Fractured vertebrae were excluded. The computed tomography raw images were reviewed by two experienced radiologists blinded to the DXA or QCT BMD results to assess whether spinal degeneration, abdominal aortic calcification (AAC) or vertebral fractures were present. Any divergence was resolved by consensus.

Diagnosis of osteoporosis

We used the diagnostic criteria established by the World Health Organisation in 1994 for DXA (T-score ≤ -2.5 standard deviation (SD) indicates osteoporosis; -1.0 SD to -2.5 SD indicates osteopenia; ≥ -1 SD indicates normal) [9]. The criteria suggested by the International Society for Clinical Densitometry in 2007 [6] and by the American College of Radiology in 2008 were used for QCT [7]. For the spinal trabecular BMD, the thresholds were <120 mg/cm³ for osteopenia (equivalent to a DXA T-score of -1.0 SD) and <80 mg/cm³ for osteoporosis (equivalent to a DXA T-score of -2.5 SD).

Discordance in the diagnosis of osteoporosis between DXA and QCT was divided into two groups: minor and major according to Woodson's definition [10]. Minor discordance happens when the different diagnostic classes are adjacent, i.e., the patient was diagnosed with osteoporosis by one technique and osteopenia by the other or osteopenia by one technique and normal by the other one. Major discordance was defined when the diagnosis by one technique was osteoporosis and the other was normal.

Statistical analysis

SPSS for Windows statistical software (version 19.0 SPSS Inc., Chicago, IL, USA) was used for statistical analyses. The difference between the detection rates of osteoporosis for DXA versus QCT was analyzed using the Chi-square test. A p value < 0.05 was taken to indicate statistical significance.

Results

The 313 male participants ranged in age from 60 to 97 years (mean, 79.6 ± 7.2 years). BMI ranged from 13.4 to 31.5 (mean, 24.3 ± 3.2). Thirty-four participants were diagnosed with osteoporosis by DXA at either the lumbar spine and/or hip, and 141 were diagnosed with osteoporosis by lumbar spine QCT. The detection rate for osteoporosis was 10.9% for DXA (at either the lumbar spine and/or hip) and 45.1% for QCT, a statistically significant difference ($p < 0.001$). The comparison of the detection rate of osteoporosis between QCT and DXA is presented in Table 1.

Among all 313 participants, a diagnostic discordance between DXA and QCT was observed in 185 (59.1%) participants, including 26 (8.3%) cases of major discordance and 159 (50.8%) of minor discordance. The other 128 (40.9%) participants had concordant findings. Among the 26 participants with major discordance, 25 were diagnosed with osteoporosis by QCT but normal by DXA, and only one was diagnosed with osteoporosis by DXA and normal by QCT

Table 1 Comparison of the detection rate of osteoporosis between QCT and DXA.

Measurement	Osteoporosis (%)	Osteopenia (%)	Normal (%)
DXA			
Lumbar spine	8 (2.6)	41 (13.1)	264 (84.3)
Hip	31 (9.9)	159 (50.8)	123 (39.3)
Either spine or hip	34 (10.9)	159 (50.8)	120 (38.3)
QCT			
Lumbar spine	141 (45.1)	110 (35.1)	62 (19.8)

DXA = dual-energy X-ray absorptiometry; QCT = quantitative computed tomography.

Table 2 Distribution of diagnostic discordances.

Diagnostic discordance	No.
Major discordance, QCT, osteoporosis; DXA, normal	25
26 (8.3%) QCT, normal; DXA, osteoporosis	1
Minor discordance, QCT, osteoporosis; DXA, osteopenia	89
159 (50.8%) QCT, osteopenia; DXA, osteoporosis	6
QCT, osteopenia; DXA, normal	49
QCT, normal; DXA, osteopenia	15
Concordance, QCT and DXA, osteoporosis	27
128 (40.9%) QCT and DXA, osteopenia	55
QCT and DXA, normal	46

DXA = dual-energy X-ray absorptiometry; QCT = quantitative computed tomography.

(Table 2). A total of 114 (36.4%) were diagnosed with osteoporosis by QCT but not by DXA (DXA osteopenia or normal). Of these, 17 (17/114) were found to have severe vertebral compression (the vertebral compression rate was more than 40%) or vertebral fractures. All 114 (114/114) had degeneration of lumbar spine (osteophytes, end-plate sclerosis, ossification of the spinal ligament or facet joint osteoarthritis), and 74 (74/114) had AAC. Some examples of diagnostic discordance of osteoporosis by DXA and QCT are presented in Figure 1.

Discussion

DXA and QCT are the most commonly used clinical techniques for BMD measurement [11]. The BMD value obtained from DXA is the areal bone mineral density measured in g/cm², and QCT allows measurement of volumetric bone mineral density measured in mg/cm³. Several studies have focused on the comparisons between DXA and QCT applications [12–14]. Li et al [15] found that the detection rate of osteoporosis in postmenopausal women was significantly higher by QCT than by DXA. Our study demonstrated that a discordance in the diagnosis of osteoporosis between DXA and QCT was observed in 185 (59.1%) elderly men, and spinal QCT detected osteoporosis more frequently than spinal and hip DXA in elderly men (45.1% versus 10.9%).

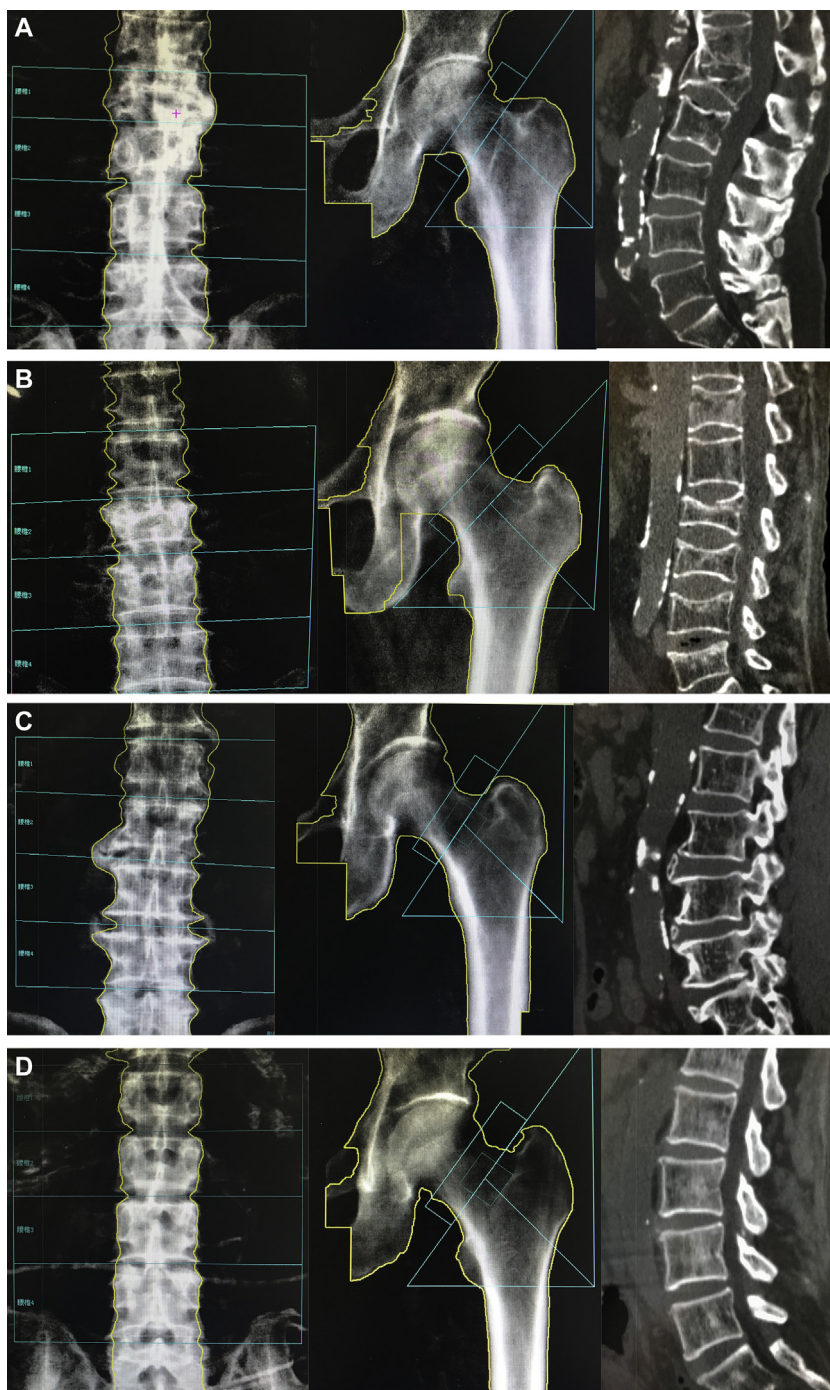


Figure 1 (A) An 82-year-old patient; the T-scores for lumbar spine DXA and hip DXA were 1.45 and -2.35 , respectively, and the diagnosis by DXA was osteopenia. The BMD measured by QCT was 34.0 mg/cm^3 , the diagnosis by QCT was osteoporosis and the diagnostic discordance was minor discordance. The image obtained by QCT showed compression fracture of L1 and AAC. (B) A 70-year-old patient; the T-scores for lumbar spine DXA and hip DXA were -1.36 and -1.92 , respectively, and the diagnosis by DXA was osteopenia. The BMD measured by QCT was 37.5 mg/cm^3 , the diagnosis by QCT was osteoporosis and the diagnostic discordance was minor discordance. The image obtained by QCT showed multiple vertebral compression and fractures and AAC. (C) An 81-year-old patient; the T-scores for lumbar spine DXA and hip DXA were 1.01 and 0.38, respectively, and the diagnosis by DXA was normal. The BMD measured by QCT was 76.2 mg/cm^3 , the diagnosis by QCT was osteoporosis and the diagnostic discordance was major discordance. The image obtained by QCT showed osteophytes, ossification of anterior longitudinal ligament and AAC. (D) a 72-year-old patient, the T-scores for lumbar spine DXA and hip DXA were -1.52 and -2.65 , respectively, and the diagnosis by DXA was osteoporosis. The BMD measured by QCT was 126.2 mg/cm^3 , the diagnosis by QCT was normal and the diagnostic discordance was major discordance.

AAC = abdominal aortic calcification; BMD = bone mineral density; DXA = dual-energy X-ray absorptiometry; QCT = quantitative computed tomography.

There are some possible causes for the occurrence of discordance: (1) The DXA measurement includes both cortical and trabecular bone, whereas QCT quantifies the trabecular bone density. Trabecular bone is known to have a more rapid rate of age-related loss than cortical bone. This may diminish the sensitivity of DXA for assessing osteoporosis [16,17]. (2) The BMD measurement by QCT is in the central plane of the vertebral body (a thick slice of 9 mm). The measured results may be affected by an uneven distribution of trabecular bone in the whole vertebral body. (3) Previous studies have shown that spinal degeneration and AAC may be associated with the overestimation of BMD and the underestimation of osteoporosis by posterior-anterior spine DXA [18–20]. Given the effect on lumbar spine DXA BMD, some researchers have suggested that DXA of the hip should be used for identification of osteoporosis in the elderly [21]. In our study, the detection rate of osteoporosis by hip DXA was significantly higher than that obtained by lumbar spine DXA ($p < 0.001$), demonstrating that the hip is a particularly important site for DXA measurement to diagnose osteoporosis. But, in this research, neither hip DXA nor lumbar spine DXA was superior to QCT for detecting osteoporosis. In addition, our results show that all the 114 participants diagnosed with osteoporosis by QCT but not by DXA had degeneration of lumbar spine (osteophytes, end-plate sclerosis, ossification of the spinal ligament or facet joint osteoarthritis) and that 74 (74/114) had AAC (Fig. 1A,B,C). This indicates that QCT performs better than DXA in detecting osteoporosis in elderly men with lumbar spine degeneration and AAC.

In our study, the concordance rate for the diagnosis of osteoporosis between QCT and DXA in elderly men was 40.9%, and diagnostic discordance was observed in 185 (59.1%) participants. Most of these discordances (50.8%) are minor discordance, presenting a difference of only one class. Among the 26 participants with major discordance, 25 were diagnosed with osteoporosis by QCT but normal by DXA (Fig. 1C), about 8.0% (25/313) of our total cases. Only one was diagnosed with osteoporosis by DXA with a diagnosis of normal by QCT (Fig. 1D). Seventeen cases with severe vertebral compression or vertebral fractures were diagnosed with osteoporosis by QCT but not by DXA (Fig. 1A and B). This discordance may influence the therapeutic plan and the overall prognosis of patients. This indicates that using DXA alone to diagnose osteoporosis may lead to the condition being missed and DXA is not sufficient to account for all spectra of fracture risks in elderly men.

Recently, some researchers have been studying the application of computed tomography in measuring bone strength and predicting fracture [22–24]. These studies have shown that in addition to measuring BMD for detecting osteoporosis, QCT has the unique ability to provide information on anatomical morphology and get many quantitative parameters about bone health with a single scan, without causing pain due to movement especially in the elderly and those with fractures (such as identifying the details of vertebral fractures [25]).

This study has some limitations. The first is that we could not rule out the possibility of referral bias for this study. As the study was performed in a hospital in Beijing, it limited the interpretation of the results to other regions

and nations in China. The second is we did not perform the statistical analysis about the possible risk factors to the diagnostic discordance. And, the importance of existing discordance on the prognosis and fracture risk of patients needs further prognostic studies with long follow-up designs.

In summary, our study demonstrated that discordance was common when using QCT and DXA to diagnose osteoporosis and that spinal degeneration, aorta calcification and fracture obscure the BMD measurement of spine by DXA. In Chinese elderly men, QCT is the more sensitive method of choice for measuring BMD.

Conflicts of interest statement

The authors have no conflicts of interest relevant to this article.

Ethics approval

Ethics approval was received by the author's institution to conduct this study.

Acknowledgements

XC acknowledges financial support from the Beijing Bureau of Health 215 program (grant number: 2009-2-03) and from the Capital Characteristic Clinic Project (grant number: 2014-2-1122).

Appendix A. Supplementary data

Supplementary data to this article can be found online at <https://doi.org/10.1016/j.jot.2018.11.003>.

References

- [1] Cauley JA. Public health impact of osteoporosis. *Gerontol A Biol Sci Med Sci* 2013;68(10):1243–51.
- [2] Cummings SR, Melton LJ. Epidemiology and outcomes of osteoporotic fractures. *Lancet* 2002;359(9319):1761–7.
- [3] Chen P, Li Z, Hu Y. Prevalence of osteoporosis in China: a meta-analysis and systematic review. *BMC Publ Health* 2016 Oct 3;16(1):1039.
- [4] Wade SW, Strader C, Fitzpatrick LA, et al. Estimating prevalence of osteoporosis: examples from industrialized countries. *Arch Osteoporos* 2014;9(1):182.
- [5] World Health Organization. Assessment of fracture risk and its application to screening for postmenopausal osteoporosis. In: Technical report series 843. Geneva: WHO; 1994.
- [6] Engelke K, Adams JE, Armbrecht G, Augat P, Bogado CE, Bouxsein ML, et al. Clinical use of quantitative computed tomography and peripheral quantitative computed tomography in the management of osteoporosis in adults: the 2007 ISCD Official Positions. *J Clin Densitom* 2008;11(1):123–62.
- [7] American College of Radiology. Reston, "ACR practice guideline for the performance of quantitative computed tomography (QCT) bone densitometry (resolution 33). 2008. Available from: <http://www.acr.org/~media/ACR/Documents/Pgts/guidelines/QCT.pdf>.

- [8] Cheng XG, Yang DZ, Zhou Q, Zhou TJ, Zhang HC, Hong JX, et al. Age-related bone mineral density, bone loss rate, prevalence of osteoporosis, and reference database of women at multiple centers in China. *J Clin Densitom* 2007;10(3):276–84.
- [9] Kanis JA, Melton III LJ, Christiansen C, Johnston CC, Khaltaev N. The diagnosis of osteoporosis. *J Bone Miner Res* 1994;9(8):1137–41.
- [10] Woodson G. Dual X-ray absorptiometry T-score concordance and discordance between the hip and spine measurement site. *J Clin Densitom* 2000;3(4):319–24.
- [11] Oei L, Koromani F, Rivadeneira F, Zillikens MC, Oei EH. Quantitative imaging methods in osteoporosis. *Quant Imag Med Surg* 2016;6(6):680–98.
- [12] Mylona M, Leotsinides M, Alexandrides T, Zoumbos N, Dimopoulos PA. Comparison of DXA, QCT and trabecular structure in beta-thalassaemia. *Eur J Haematol* 2005;74(5):430–7.
- [13] Yu W, Gluer CC, Grampp S, Jergas M, Fuerst T, Wu CY, et al. Spinal bone mineral assessment in postmenopausal women: a comparison between dual X-ray absorptiometry and quantitative computed tomography. *Osteoporos Int* 1995;5(6):433–9.
- [14] Engelke K, Libanati C, Liu Y, Wang H, Austin M, Fuerst T, et al. Quantitative computed tomography (QCT) of the forearm using general purpose spiral whole-body CT scanners: accuracy, precision and comparison with dual-energy X-ray absorptiometry (DXA). *Bone* 2009;45(1):110–8.
- [15] Li N, Li XM, Xu L, Sun WJ, Cheng XG, Tian W, et al. Comparison of QCT and DXA: osteoporosis detection rates in postmenopausal women. *Int J Endocrinol* 2013;ID:895474.
- [16] Eastell R. Treatment of postmenopausal osteoporosis. *N Engl J Med* 1998;338:736–46.
- [17] Moayyeri A, Soltani A, Tabari NK, Sadatsafavi M, Hosseinneghad A, Larijani B, et al. Discordance in diagnosis of osteoporosis using spine and hip bone densitometry. *BMC Endocr Disord* 2005;5. <https://doi.org/10.1186/1472-6823-5-3>.
- [18] Ito M, Hayashi K, Yamada M, Uetani M, Nakamura T. Relationship of osteophytes to bone mineral density and spinal fracture in men. *Radiology* 1993;189(2):497–502.
- [19] Rand T, Seidl G, Kainberger F, Resch A, Hittmair K, Schneider B, et al. Impact of spinal degenerative changes on the evaluation of bone mineral density with dual energy Xray absorptiometry (DXA). *Calcif Tissue Int* 1997;60(5):430–3.
- [20] Reid IR, Evans MC, Ames R, Wattie DJ. The influence of osteophytes and aortic calcification on spinal mineral density in postmenopausal women. *J Clin Endocrinol Metabol* 1991;14(6):1372–4.
- [21] Schneider DL, Bettencourt R, Barrett-Connor E. The clinical utility of spine bone density in elderly women. *J Clin Densitom* 2006;9(3):255–60.
- [22] Shirvaikar M, Huang N, Dong XN. The measurement of bone quality using gray level co-occurrence matrix textural features. *J Med Imaging Health Inform*. 2016 Oct;6(6):1357–62.
- [23] Nardone V, Tini P, Croci S, Carbone SF, Sebaste L, Carfagno T, et al. 3D bone texture analysis as a potential predictor of radiation-induced insufficiency fractures. *Quant Imag Med Surg* 2018;8(1):14–24.
- [24] Yu AH, Carballido-Gamio J, Wang L, Lang TF, Su YB, Wu XB, et al. Spatial differences in the distribution of bone between femoral neck and trochanteric fractures. *J Bone Miner Res* 2017;32(8):1672–80.
- [25] Wáng YXJ, Santiago FR, Deng M, Nogueirabarbosa MH. Identifying osteoporotic vertebral endplate and cortex fractures. *Quant Imag Med Surg* 2017;7(5):555–91.