

# Case Report: Diagnosis of Hemolytic Anemia from Babesia and Secondary Multi-Pathogen Pneumonia Using a Metagenomic Next-Generation Sequencing Approach

Yun Lu<sup>1,2,\*</sup>, Dan Zhang<sup>2-4,\*</sup>, Dongsheng Han<sup>2-4</sup>, Fei Yu<sup>2-4</sup>, Xingnong Ye<sup>5</sup>, Shufa Zheng<sup>2-4</sup>

<sup>1</sup>Department of Clinical Laboratory, The Children's Hospital, Zhejiang University School of Medicine, National Clinical Research Center for Child Health, National Children's Regional Medical Center, Hangzhou, People's Republic of China; <sup>2</sup>Department of Laboratory Medicine, the First Affiliated Hospital, Zhejiang University School of Medicine, Hangzhou, People's Republic of China; <sup>3</sup>Key Laboratory of Clinical in vitro Diagnostic Techniques of Zhejiang Province, Hangzhou, People's Republic of China; <sup>4</sup>Institute of Laboratory Medicine, Zhejiang University, Hangzhou, People's Republic of China; <sup>5</sup>Department of Hematology, the First Affiliated Hospital, Zhejiang University School of Medicine, Hangzhou, People's Republic of China

\*These authors contributed equally to this work

Correspondence: Shufa Zheng, Department of Laboratory Medicine, the First Affiliated Hospital, Zhejiang University School of Medicine, No. 79, Qingchun Road, Hangzhou, 310003, People's Republic of China, Email zsfzheng@zju.edu.cn; Xingnong Ye, Department of Hematology, the First Affiliated Hospital, Zhejiang University School of Medicine, No. 79, Qingchun Road, Hangzhou, 310003, People's Republic of China, Email xingnong@zju.edu.cn

**Abstract:** Babesiosis, as a vector-borne infectious disease, remains relatively rare and is prone to being overlooked and misdiagnosed. Therefore, understanding the epidemiological characteristics and clinical manifestations of babesiosis is crucial for the prompt detection and treatment of the disease. We reported a 63-year-old male patient presenting with spontaneous fever and chills. Laboratory investigations revealed erythrocytopenia, reduced hemoglobin levels, and increased reticulocytes and total bilirubin. Bone marrow examination indicated vigorous cell proliferation, a decreased granulocyte to red cell ratio, and predominant erythroid cell proliferation, with a higher prevalence of intermediate and late-stage juvenile granulocyte and erythroid cells. Initial treatment focused on hemophagocytic syndrome triggered by Epstein-Barr virus infection yielded unsatisfactory results, leading to secondary multiple pulmonary infections. Metagenomic next-generation sequencing (mNGS) of sputum samples pointed to hemolytic anemia induced by Babesia infection, which was subsequently confirmed through peripheral blood smear analysis. The patient responded well to prompt administration of atovaquone and azithromycin, with symptoms resolving and laboratory parameters normalizing. Hemolytic anemia resulting from babesiosis should be distinguished from hemophagocytic syndrome caused by Epstein-Barr virus and other hematologic conditions. mNGS represents an efficient technique for Babesia detection.

**Keywords:** Babesia, Hemolytic anemia, mNGS, Pneumonia

## Introduction

Human babesiosis is an increasingly recognized zoonotic disease with a global footprint, attributed to protozoan parasites of the genus *Babesia*, transmitted via Ixodes ticks.<sup>1-3</sup> The infection has been mainly reported in America but also in other regions of the world, notably Europe, Australia, and South America.<sup>4-6</sup> In recent years, the number of babesia infections in China has continued to rise, with confirmed cases reported in Beijing, Zhejiang and Fujian.<sup>7-9</sup> The babesiosis specifically targets human or other vertebrate red blood cells, leading to symptoms such as intermittent fever, spleen enlargement, jaundice, and hemolysis.<sup>10</sup> As a relatively rare vector-borne disease, babesiosis is susceptible to being overlooked and misdiagnosed in clinical practice. Hence, a thorough understanding of its epidemiological trends and clinical manifestations is essential for the timely detection and management of the disease.

## Case Presentation

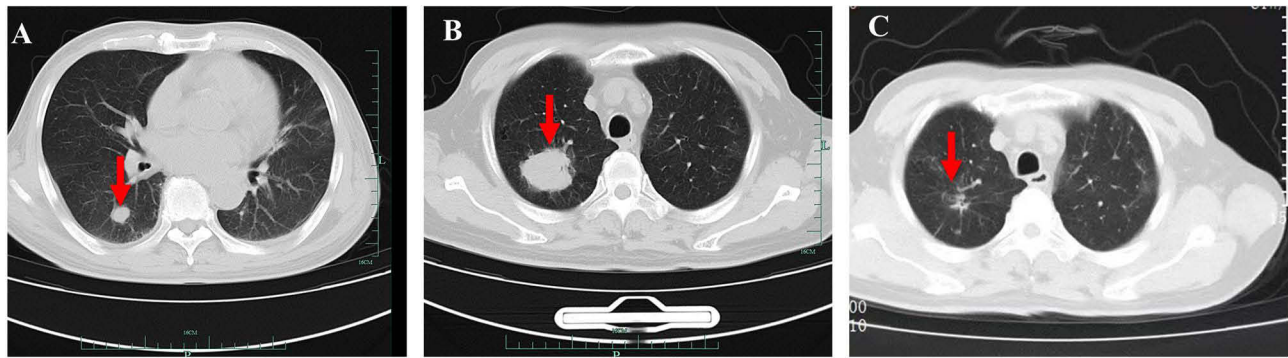
In May 2023, a 63-year-old man presented with a fever peaking at 38°C, chills, fatigue, and poor overall well-being. Laboratory results indicated erythrocytopenia, with red blood cell (RBC) count at  $2.2 \times 10^{12}/L$ , hemoglobin (Hb) at 72g/L, and platelet count (PLT) at  $80 \times 10^9/L$ ; reticulocyte percentage was notably high at 9.7%. Elevated levels of C-reactive protein (CRP) at 63.6mg/L, erythrocyte sedimentation rate (ESR) at 80mm/h, ferritin at 1469ng/mL, and lactate dehydrogenase (LDH) at 1103U/L were observed (Table 1). The patient tested positive for Epstein-Barr virus (EBV) IgM, with both urine occult blood and hemosiderin tests returning positive results. Ultrasonography revealed splenomegaly. A bone marrow biopsy indicated active hyperplasia, with a decreased granulocyte to nucleated erythrocyte ratio, and erythroid hyperplasia being predominant, featuring occasionally hemophagocytic cells. Initially treated for hemophagocytic syndrome induced by EBV infection, the patient received ciprofloxacin, cyclosporine, dexamethasone, and etoposide in local hospital. Despite some improvement, weakness persisted.

In July 2023, the patient was readmitted with a low-grade fever. Routine laboratory tests revealed the following: RBC count at  $1.58 \times 10^{12}/L$ , Hb level at 61g/L, PLT count at  $76 \times 10^9/L$ , Reticulocyte percentage at 15.71%, CRP count at 19.6mg/L, ESR at 66mm/h, Serum total bilirubin at 35.0 $\mu$ mol/L, Serum direct total bilirubin at 22.4 $\mu$ mol/L, and blood EBV DNA at  $5.26 \times 10^3$  copies /mL (Table 1). A chest CT scan identified scattered nodules across both lungs, with a notably larger one located in the lower right lung (Figure 1A). Bone marrow smear analysis indicated that phagocytic reticulum cells constituted 0.5%, while the bone marrow biopsy did not reveal any abnormal cells. PET-CT showed that the metabolism of Fluoro-Deoxy-Glucose (FDG) in bone marrow cavity was slightly increased, and the spleen was full with FDG metabolism. Although lymphoma could not be entirely ruled out based on the existing diagnostic evidence, the primary concern was hemolytic anemia in conjunction with the confirmed EBV infection. Consequently, the patient

**Table 1** Clinical Blood Biochemistry Tests

Variable	Normal Range	Detection Time			
		May 2023	Jul 2023	Sep 2023	Jan 2024
Leukocyte Count, 10E9/L	3.5–9.5	6.09	5.91	9.83	4.89
Lymphocyte Count, 10E9/L	1.1–3.2	1.72	0.80	1.2	1.93
Monocytes Count, 10E9/L	0.1–0.6	1.44	0.44	0.71	0.77
Red Blood Cell, 10E12/L	4.09–5.74	2.20	1.58	1.81	4.73
Hemoglobin, g/L	130–175	72	61	63	149
Platelet count, 10E9/L	125–350	80	76	206	172
Reticulocyte Percentage, %	0.5–1.5	9.7%	15.71	15.80	ND
C-reactive Protein, mg/L	0.00–5.00	63.6	19.6	76.2	0.84
Erythrocyte Sedimentation Rate, mm/h	0–15	80	66	99	ND
Thrombin Time, s	14.5–21.5	14.5	14.7	14.8	16.4
Prothrombin Time, s	10.0–13.5	12.5	11.3	12.6	10.7
Fibrinogen, g/L	2.00–4.00	4.96	4.17	5.82	2.15
D-dimer, $\mu$ g/L FEU	0–700	ND	1010	1670	ND
Ferritin, ng/mL	7.0–323.0	1469	1517	3127.19	ND
Albumin, g/L	40–55	ND	27	ND	47.1
Alanine Transaminase, IU/L	9–50	ND	53	115	23
Aspartate Transaminase, IU/L	15–50	ND	88	68	26
Blood Urea Nitrogen, mmol/L	3.1–8.0	ND	10.1	ND	8.04
Serum Total Bilirubin, $\mu$ mol/L	0.0–26.0	ND	35.9	28.3	7.6
Serum Direct Total Bilirubin, $\mu$ mol/L	0.0–8.0	ND	22.4	14.8	2.1
Creatine Kinase, IU/L	40–200	115	34	38	ND
Creatine Kinase-MB, IU/L	2–25	ND	16	19	ND
Lactate Dehydrogenase, IU/L	120–250	1103	2198	2769	ND
Interleukin-6, pg/mL	0–5.30	67.7	8.17	28.19	ND
Interleukin-10, pg/mL	0–4.91	ND	63.4	112.37	ND

**Abbreviation:** ND, No Detection.



**Figure 1** Chest CT of the patient (July 2023 in (A) picture, September 2023 in (B) picture, November 2023 in (C) picture, red arrows indicate pulmonary mass shadow).

received treatment with dexamethasone and cyclosporine to manage the hemolytic condition, in addition to galiximab, before being discharged.

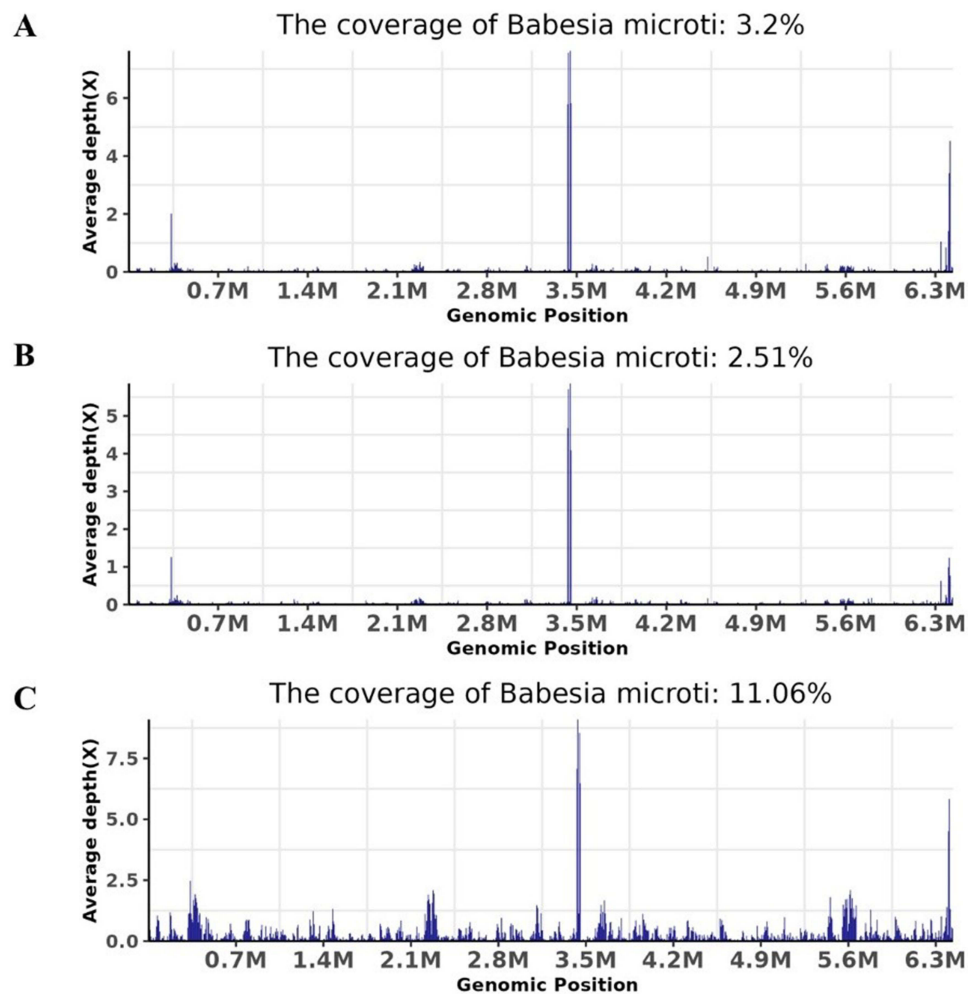
In September 2023, the patient was rehospitalized due to an exacerbation of symptoms, including a severe cough with sputum production, chest tightness, and acute shortness of breath following physical activity. Laboratory investigations showed RBC count of  $1.81 \times 10^{12}/L$ ; Hb level at 63g/L; PLT count at  $206 \times 10^9/L$ ; Reticulocyte percentage at 15.8%; CRP level at 76.2mg/L and ESR at 99mm/h (Table 1). A CT scan of the lungs revealed a new mass in the upper lobe of the right lung (Figure 1B). Tests for fungal and bacterial infections, including fungal culture, bacterial culture, TB smear, *Cryptococcus neoformans* capsular antigen, *Mycobacterium tuberculosis* DNA, respiratory virus screening, and fungal immunofluorescence staining, returned negative results. Metagenomic next-generation sequencing (mNGS) of sputum identified *Babesia microti*, *Nocardia cyriacigeorgica*, *Pneumocystis yersii*, and human herpesvirus. Additional mNGS testing of alveolar lavage fluid and blood samples also detected *Babesia microti* (Figure 2). Examination of a peripheral blood Giemsa smear showed 27.9% parasitaemia with *Babesia microti* (Figure 3).

Upon inquiring about the patient's history of exposure, it was discovered that the patient had been bitten on the neck by ticks six months earlier while working in a mountainous area, though no significant bite marks or lesions were observed, and no treatment had been administered at that time. Treatment was initiated with atovaquone 750 mg orally Q12h plus azithromycin 500 mg intravenous injection Q24h for *Babesia*, sulfamethoxazole-trimethoprim for *Pneumocystis jirovecii* and *Nocardia*, along with human immunoglobulin to bolster immunity. Following this regimen, the chest CT scan in November 2023 and routine laboratory tests in January 2024 both showed that the patient had recovered.

## Discussion and Conclusions

Babesiosis is a zoonotic disease caused by *Babesia* parasitizing mammalian red blood cells.<sup>1,10</sup> The primary pathology of Babesiosis is the destruction of the host's red blood cells. Most cases are transmitted through tick bites, but can also lead to person-to-person infection through blood transfusion and vertical transmission.<sup>11,12</sup> The clinical symptoms of human babesiosis depend on the species of babesiosis and the immune status of the host, and can be asymptomatic, subclinical infection and acute explosive infection. Hemolytic anemia may manifest when the infection rate of RBCs exceeds 10%.<sup>13</sup> Severe cases, typically in immunocompromised individuals, can lead to hemolytic anemia, central nervous system involvement, secondary disseminated intravascular coagulation, multiple organ failure, and other life-threatening complications.<sup>14,15</sup>

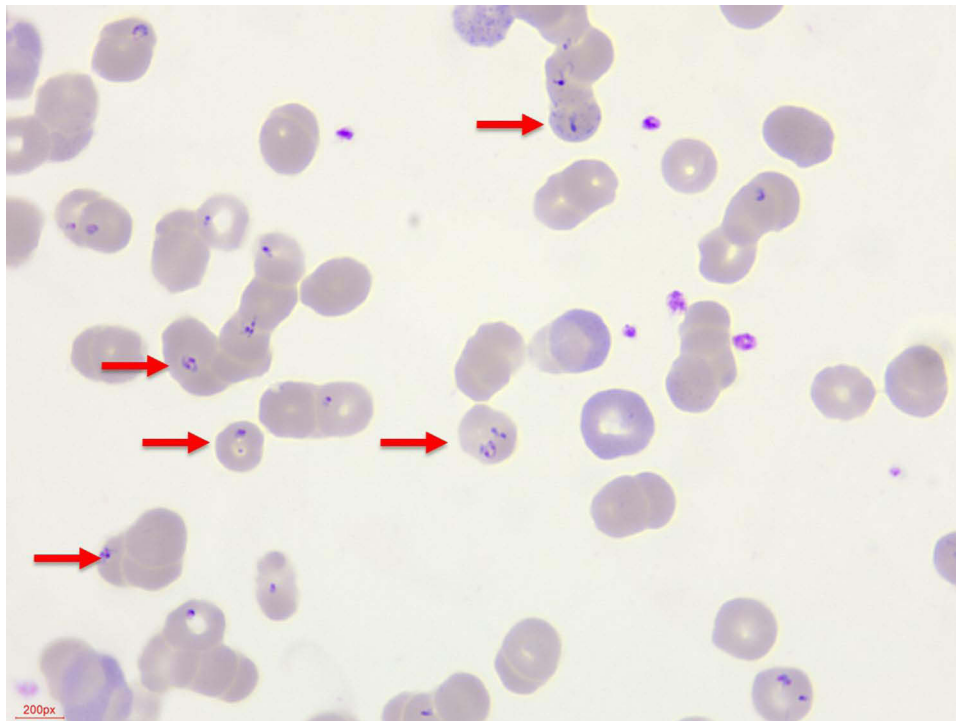
Diagnosing babesiosis is essential for treatment and disease control. Currently, microscopic detection of primordium *babesiae* is considered to be the gold standard for diagnosis of the disease, however, it requires high experience of the inspectors and is prone to false negatives in chronic or subclinical infections.<sup>16,17</sup> Antibody and PCR detection are promising diagnostic avenues for babesiosis, but because *babesia* infections are rare, clinical laboratories rarely prepare relevant detection kits.<sup>18,19</sup> In this study, we identified the pathogen through mNGS. mNGS is a nucleic acid detection technology that does not rely on microbial culture, especially in the identification of rare, new and mixed infection pathogens.<sup>20</sup> The process included nucleic



**Figure 2** Genomic coverage maps of *Babesia* detected by mNGS in different sample types (A): sputum, (B) bronchoalveolar lavage fluid, (C) blood.

acid extraction, library construction, sequencing, bioinformatics analysis, and result interpretation. Detailed experimental parameters and quality controls are comprehensively covered in our previous studies.<sup>21–23</sup> We primarily used the QIAamp<sup>®</sup> nucleic acid extraction kits to extract nucleic acids. The Nextera XT DNA Library Prep Kit (Illumina, San Diego, CA) was used for library construction. Sequencing was performed on the Illumina Nextseq CN500 platform using SE-75 or SE-50 protocols, generating approximately 20 million reads per sample. Low-quality reads were filtered out, and human sequences were removed using a predefined bioinformatics pipeline, followed by alignment to a specialized microbial database for species identification. Result interpretation guidelines are outlined in our previous work.<sup>21</sup> For Babesiosis detection, specific non-repeating reads greater than 5 were reported as detected. If fewer than 5 reads were found, repeat testing was required. A positive result on retesting confirmed detection, while a negative result led to further assessment based on the patient's medical history and clinical judgment. The reported unit for detected pathogens is SMRN (reads per pathogen at a sequencing depth of 20 million reads).<sup>21</sup>

The American Infectious Diseases Society's guidelines recommend treating mild to moderate babesiosis with oral medications for 7–10 days, either atovaquone with azithromycin (preferred) or clindamycin with quinine (alternative). For severe patients, azithromycin intravenous drip combined with atovaquone oral (preferred) or clindamycin intravenous drip combined with quinine oral (alternative) can be transferred to oral therapy after symptom improvement. Treatment duration is typically 7–10 days but may extend if parasitemia or symptoms persist. Severely immunocompromised patients should continue treatment for 2 weeks post-negative blood smear, totaling at least 6 weeks. For patients with high parasitemia, severe hemolytic anemia, immunodeficiency, or organ failure, red blood cell exchange is



**Figure 3** Microscopic examination of Giemsa stained peripheral blood smears, shows 27.9% parasitaemia with *Babesia microti* (red arrows indicate intraerythrocytic ring forms).

a crucial rescue strategy.<sup>24,25</sup> In this study, we used atovaquone combined with azithromycin to treat *Babesia*, and the peripheral blood smears were normal after treatment.

This case involved a patient with a history of insect bites presenting with fever, fatigue, and poor tolerance, characterized mainly by hemolytic anemia and hematuria, alongside decreased erythrocytes, low hemoglobin, and elevated reticulocytes, accompanied by hemophagocytic syndrome. Babesiosis was diagnosed through mNGS and peripheral blood smear, with mNGS also confirming multi-pathogen mixed infection pneumonia. In addition, the use of immunosuppressive therapy to consider hemophagocytic syndrome before the etiology of the disease is not clear, delaying the treatment of the disease. Therefore, for patients with relevant epidemiological history, combining traditional detection methods with mNGS for pathogen identification is crucial, alongside monitoring the patient's immune status and potential complications for timely intervention and treatment.

## Ethical Statement and Informed Consent

The study was reviewed and approved by the Research Ethics Committee of the First Affiliated Hospital College of Medicine, Zhejiang University and was conducted in accordance with the principles of the Declaration of Helsinki (IIT20240830A).

## Consent Statement

Written informed consent was obtained from the patient and his immediate family members for the publication of any potentially identifiable images or data included in this case report prior to inclusion.

## Acknowledgments

We acknowledge the contributions of other clinical and laboratory staff in the First Affiliated Hospital, Zhejiang University School of Medicine.

## Author Contributions

All authors made a significant contribution to the work reported, whether that is in the conception, study design, execution, acquisition of data, analysis and interpretation, or in all these areas; took part in drafting, revising or critically reviewing the article; gave final approval of the version to be published; have agreed on the journal to which the article has been submitted; and agree to be accountable for all aspects of the work.

## Funding

The Zhejiang Provincial Natural Science Foundation for Distinguished Young Scholar (grant number LR23H200002).

## Disclosure

The authors declare that they have no competing interests in this work.

## References

1. Renard I, Ben Mamoun C. Treatment of human babesiosis: then and now. *Pathogens*. 2021;10(9):1120. doi:10.3390/pathogens10091120
2. Vannier E, Krause PJ. Human babesiosis. *N Engl J Med*. 2012;366(25):2397–2407. doi:10.1056/NEJMra1202018
3. Waked R, Krause PJ. Human Babesiosis. *Infect Dis Clin North Am*. 2022;36(3):655–670. doi:10.1016/j.idc.2022.02.009
4. Gray EB, Herwaldt BL. Babesiosis surveillance - United States, 2011–2015. *MMWR Surveill Summ*. 2019;68(6):1–11. doi:10.15585/mmwr.ss6806a1
5. Hildebrandt A, Gray J, Montero E. Characteristics of human babesiosis in Europe. *Pathogens*. 2023;12(2):323. doi:10.3390/pathogens12020323
6. Gabrielli S, Totino V, Macchioni F, et al. Human babesiosis, Bolivia, 2013. *Emerg Infect Dis*. 2016;22(8):1445–1447. doi:10.3201/eid2208.150195
7. Chen Z, Li H, Gao X, et al. Human babesiosis in China: a systematic review. *Parasitol Res*. 2019;118(4):1103–1112. doi:10.1007/s00436-019-06250-9
8. Xu D. Babesiosis concurrent with multiple abscesses from staphylococcus aureus infection: a case report. *Heliyon*. 2023;9(8):e18563. doi:10.1016/j.heliyon.2023.e18563
9. Huang S, Zhang L, Yao L, et al. Human babesiosis in southeast China: a case report. *Int J Infect Dis*. 2018;68:36–38. doi:10.1016/j.ijid.2018.01.004
10. Yune PS, Islam I, Dicipinigaitis PV, et al. A case report and literature review of babesiosis-induced acute respiratory distress syndrome. *Case Rep Infect Dis*. 2022;2022:4318731. doi:10.1155/2022/4318731
11. Krause PJ. Human babesiosis. *Int J Parasitol*. 2019;49(2):165–174. doi:10.1016/j.ijpara.2018.11.007
12. Pashankar R, Prabalos AM, Feder HM Jr. A woman pregnant with twins has fever, haemolysis, and thrombocytopenia caused by babesiosis: could be confused with HELLP syndrome. *Lancet*. 2022;399(10327):e10. doi:10.1016/S0140-6736(22)00315-4
13. Herwaldt B, Persing DH, Précigout EA, et al. A fatal case of babesiosis in Missouri: identification of another piroplasm that infects humans. *Ann Intern Med*. 1996;124(7):643–650. doi:10.7326/0003-4819-124-7-199604010-00004
14. Dermawan JK, Mukherjee S. Hemophagocytic lymphohistiocytosis secondary to babesiosis. *Blood*. 2020;135(10):779. doi:10.1182/blood.2019004149
15. Spichler-Moffarah A, Ong E, O'Bryan J, et al. Cardiac Complications of Human Babesiosis. *Clin Infect Dis*. 2023;76(3):e1385–e1391. doi:10.1093/cid/ciac525
16. Primus S, Akoolo L, Schlachter S, et al. Screening of patient blood samples for babesiosis using enzymatic assays. *Ticks Tick Borne Dis*. 2018;9(2):302–306. doi:10.1016/j.ttbdis.2017.11.003
17. Annoscia G, Latrofa MS, Cantacessi C, et al. A new PCR assay for the detection and differentiation of *Babesia canis* and *Babesia vogeli*. *Ticks Tick Borne Dis*. 2017;8(6):862–865. doi:10.1016/j.ttbdis.2017.07.002
18. Lira-Amaya JJ, Martínez-García G, Santamaria-Espinosa RM, et al. Comparative study of indirect fluorescent antibody, ELISA, and immunochromatography tests for serological diagnosis of bovine babesiosis caused by *Babesia bovis*. *Animals*. 2021;11(12):3358. doi:10.3390/ani11123358
19. Zhou X, Li SG, Wang JZ, et al. Emergence of human babesiosis along the border of China with Myanmar: detection by PCR and confirmation by sequencing. *Emerg Microbes Infect*. 2014;3(8):e55. doi:10.1038/emi.2014.55
20. Han D, Li Z, Li R, et al. mNGS in clinical microbiology laboratories: on the road to maturity. *Crit Rev Microbiol*. 2019;45(5–6):668–685. doi:10.1080/1040841X.2019.1681933
21. Han D, Yu F, Zhang D, et al. The real-world clinical impact of plasma mNGS testing: an observational study. *Microbiol Spectr*. 2023;11(2):e0398322. doi:10.1128/spectrum.03983-22
22. Zhang X, Chen H, Han D, et al. Clinical usefulness of metagenomic next-generation sequencing for *Rickettsia* and *Coxiella burnetii* diagnosis. *Eur J Clin Microbiol Infect Dis*. 2023;42(6):681–689. doi:10.1007/s10096-023-04586-w
23. Chen R, Xie M, Wang S, et al. Secondary infection surveillance with metagenomic next-generation sequencing in COVID-19 patients: a cross-sectional study. *Infect Drug Resist*. 2023;16:6463–6472. doi:10.2147/IDR.S424061
24. Krause PJ, Auwaerter PG, Bannuru RR, et al. Clinical practice guidelines by the Infectious Diseases Society of America (IDSA): 2020 Guideline on Diagnosis and Management of Babesiosis. *Clin Infect Dis*. 2021;72(2):185–189. doi:10.1093/cid/ciab050
25. Vidyam P, Pal AC, Renard I, et al. Tafenoquine-atovaquone combination achieves radical cure and confers sterile immunity in experimental models of human babesiosis. *J Infect Dis*. 2024;229(1):161–172. doi:10.1093/infdis/jiad315

Infection and Drug Resistance

Dovepress

### Publish your work in this journal

Infection and Drug Resistance is an international, peer-reviewed open-access journal that focuses on the optimal treatment of infection (bacterial, fungal and viral) and the development and institution of preventive strategies to minimize the development and spread of resistance. The journal is specifically concerned with the epidemiology of antibiotic resistance and the mechanisms of resistance development and diffusion in both hospitals and the community. The manuscript management system is completely online and includes a very quick and fair peer-review system, which is all easy to use. Visit <http://www.dovepress.com/testimonials.php> to read real quotes from published authors.

Submit your manuscript here: <https://www.dovepress.com/infection-and-drug-resistance-journal>