

## Chorioretinal Coloboma Complications: Retinal Detachment and Choroidal Neovascular Membrane

Rehan M. Hussain<sup>1</sup>, MD; Ashkan M. Abbey<sup>2</sup>, MD; Ankoor R. Shah<sup>2</sup>, MD; Kimberly A. Drenser<sup>2</sup>, MD, PhD  
Michael T. Trese<sup>2</sup>, MD; Antonio Capone Jr<sup>2</sup>, MD

<sup>1</sup>Department of Ophthalmology, Indiana University School of Medicine, Indianapolis, Indiana, USA

<sup>2</sup>Department of Ophthalmology, Associated Retinal Consultants, Oakland University William Beaumont School of Medicine, Royal Oak, Michigan, USA

### Abstract

**Purpose:** To report the chorioretinal coloboma, and its association with increased risk of retinal detachment (RD) and choroidal neovascularization (CNV).

**Methods:** This retrospective case series included eyes with chorioretinal coloboma diagnosed between 1995 and 2014 with a focus on RD and CNV as related complications. Cases of CNV were managed with laser photocoagulation or intravitreal injection of bevacizumab. For eyes with CNV, therapeutic success was defined as resolution of the subretinal hemorrhage on fundus examination and resolution of the subretinal and intraretinal fluid on optical coherence tomography (OCT). For eyes with RD, anatomic success following surgical intervention was defined as attachment of the retina at the last follow-up visit.

**Results:** Fifty-one eyes of 31 patients with chorioretinal coloboma were identified for review. Bilateral chorioretinal coloboma was present in 64.5% of subjects. RD developed in 15 eyes (29.4%). Among 15 eyes with RD, 4 eyes (27%) had retinal breaks identified within the coloboma, 5 eyes (33%) had retinal breaks outside the coloboma, 2 eyes (13%) showed retinal breaks both inside and outside the coloboma, and in 4 eyes (27%) the causative retinal break was not localized. The overall rate of anatomic success after RD repair was 85.7%. CNV developed in 7 eyes (13.7%) and was located along the margin of the coloboma in all cases. CNV was bilateral in 2 of the 5 affected individuals (40%).

**Conclusion:** RD and CNV were present in a high percentage of eyes with chorioretinal coloboma in these series. The frequent finding of retinal breaks outside the coloboma bed suggests that vitreoretinal interface abnormalities may play a role in development of RD in these eyes.

**Keywords:** Choroidal Coloboma; Choroidal Neovascular Membrane; Retinal Detachment

*J Ophthalmic Vis Res* 2017; 12(1): 3-10

### Correspondence to:

Rehan M. Hussain, MD. Department of Ophthalmology,  
Indiana University School of Medicine,  
1160 W. Michigan St, Indianapolis,  
Indiana 46202, USA.  
E-mail: rhussain27@gmail.com

Received: 31-01-2016

Accepted: 07-08-2016

### INTRODUCTION

Chorioretinal coloboma is an uncommon congenital anomaly of the posterior segment occurring as a consequence of incomplete closure of the embryonic fissure during fetal development. Anatomical alterations in colobomatous eyes include atrophic retina,

This is an open access article distributed under the terms of the Creative Commons Attribution-NonCommercial-ShareAlike 3.0 License, which allows others to remix, tweak, and build upon the work non-commercially, as long as the author is credited and the new creations are licensed under the identical terms.

For reprints contact: reprints@medknow.com

**How to cite this article:** Hussain RM, Abbey AM, Shah AR, Drenser KA, Trese MT, Capone Jr A. Chorioretinal coloboma complications: retinal detachment and choroidal neovascular membrane. *J Ophthalmic Vis Res* 2017;12:3-10.

### Access this article online

#### Quick Response Code:



Website:  
[www.jovr.org](http://www.jovr.org)

DOI:  
10.4103/2008-322X.200163

staphylomatous sclera, and absence of retinal pigment epithelium (RPE), Bruch's membrane, choriocapillaris, and choroid. RPE is thickened at the edge of the colobomas.<sup>[1]</sup>

Patients with posterior segment colobomas are at risk for retinal detachment (RD) occurring as a consequence of retinal breaks located: (a) Outside the area of the coloboma, (b) inside the anomalous retinal tissue within the coloboma, or (c) both.<sup>[2]</sup> Colobomatous eyes are also at greater risk for choroidal neovascularization (CNV) caused by breaks in Bruch's membrane at the margin of the colobomas.<sup>[3]</sup> Herein, we retrospectively review a series of eyes with chorioretinal coloboma seen at our practice between 1995 and 2014, with a focus on the related complications of RD and CNV.

## METHODS

This is an Institutional Review Board approved retrospective chart review of 31 patients (51 eyes) with a diagnosis of chorioretinal coloboma seen at Associated Retinal Consultants in Royal Oak, Michigan, USA between 1995 and 2014. All procedures were in line with the tenets of the Declaration of Helsinki. Patient demographics, clinical ophthalmic features, best corrected Snellen visual acuities (BCVA), and type of interventions were recorded. For eyes with RD, anatomic success following surgical intervention was defined as attachment of the retina at the last follow-up visit. For eyes with CNV, therapeutic success was defined as resolution of the subretinal hemorrhage on fundus examination and resolution of the subretinal and intraretinal fluid on optical coherence tomography (OCT).

## RESULTS

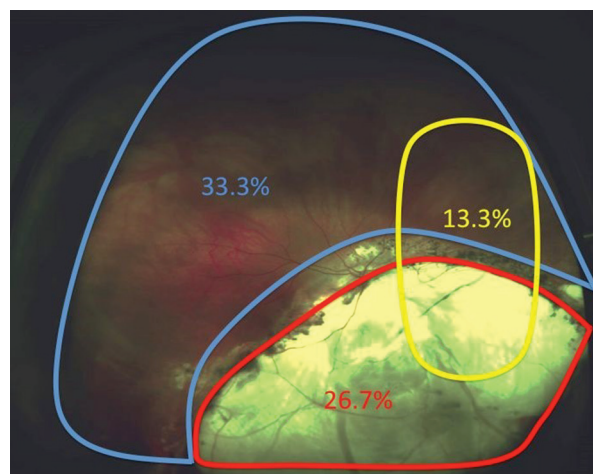
Thirty-one patients with chorioretinal coloboma were identified. Since chorioretinal coloboma was present bilaterally in 20 (64.5%) patients, 51 eyes were included in this series. The male:female ratio was 14:17. Among patients with unilateral chorioretinal coloboma, 8 and 3 were affected in the right and left eyes, respectively. The chorioretinal colobomas were mostly located in the typical inferonasal location, though macular and optic nerve involvement was noted in 14/51 (27.4%) and 35/51 (68.7%) of eyes, respectively. An isolated peripapillary chorioretinal defect was present in 15/51 (29.4%) eyes. The mean and median duration of follow-up for the total pool of patients was 43 and 11 months, respectively.

An isolated retinal tear without RD was present in 2/51 (4%) of eyes in this series. Both tears were located in periphery, outside of the bed of the coloboma. One retinal tear was treated with laser, and for the treatment of the other cryotherapy was performed. Retina was attached

in both eyes at the last follow-up evaluation. BCVA of the eye treated with laser was 20/400 both pre- and post-retinopexy. The eye treated with cryotherapy had final BCVA of 20/30, with no pretreatment BCVA recorded due to the patient's young age.

RD was present in 29.4% (15/51) of eyes at the initial referral visit. Mean age at presentation was 11 years (median 5 years; range, 6 weeks to 69 years). In eyes with RD, 27% (4/15) had retinal breaks identified within the coloboma, 33% (5/15) had retinal breaks outside the coloboma, 13% (2/15) had retinal breaks both inside and outside the coloboma, and in 27% (4/15) the causative retinal break was not localized [Figure 1]. One eye presented with a concurrent choroidal detachment. Of 15 eyes with RD, 6 eyes (40%) subsequently developed proliferative vitreoretinopathy (PVR). The information pertaining to each eye with RD is summarized in Table 1.

Of 15 eyes with RD, surgical repair was attempted in 14 eyes (93.3%). One eye was already phthisical at the time of presentation and did not undergo RD surgery. The total number of retinal reattachment procedures performed in this group was 28, with a mean of 2 interventions per eye. The initial surgical approach was generally pars plana vitrectomy with intraocular tamponade (93%, 13/14 eyes). Silicone oil was used as the intraocular tamponade in primary surgeries in 8 out of 13 eyes (61.5%). Finally, silicone oil was used in 77% (10/13) of eyes. The oil was ultimately removed in 30% (3/10) of eyes in which it was employed. One eye with silicone oil tamponade was complicated by migration of the oil into the anterior chamber with resultant glaucoma, zonular dehiscence, and band keratopathy (10%). Endolaser



**Figure 1.** Location of retinal breaks in eyes with colobomatous retinal detachments. Four RDs (26.7%) had retinal breaks that originated within the bed of the coloboma. Five RDs (33.3%) had retinal breaks outside of the coloboma. Two RDs (13.3%) had retinal breaks identified both inside and outside the coloboma. The origin of the detachment was uncertain in 4 RDs (26.7%).

Table 1. Demographics, treatment details, and visual outcomes of patients who underwent retinal detachment repair

Age at time of RD (mos)/ Sex	Coloboma involvement	Location of retinal break	Surgery	Laser around coloboma	Anatomic Result	Preop V/A	Postop V/A	Follow up (mos)	Comment
83/M	ONH	Inferior to ONH coloboma OD, edge of coloboma OS	1. SB/APE/Air OS 2. V/MP/FAX/APE OS 3. V/MP/APE/SO OS	No	Not attached	N/A	N/A	81	Failed SB initially
54/M	ONH	Break not identified	1. V/MP/APE/EL/SO 2. V/SO exchange/AFX/EL OS 3. EL of subretinal cyst OS	Yes	6Attached	N/A	HM	66	
33/M	Chorioretinal, macula	Break not identified	V/MP/APE/drain choroidals/SO OS	No	Attached	N/A	N/A	11	Hemorrhagic choroidal and retinal detachment
105/M	ONH	Superotemporal to ONH coloboma edge	V/MP/EL/SO OS	Yes	Not attached	LP	LP	109	
36/F	ONH/iris OU	Outside of coloboma	SB OD	No	Attached	N/A	20/80	67	Possible FEVR OU. Bilateral RD, though OS was phthisical and did not undergo SB procedure
28/M	Chorioretinal, iris	Along edge of coloboma	1. V/SO/EL OS and laser demarcation OD 2. V/CE/SO removal/MP/AFX OS 3. V/IOL/SO removal OS 4. Laser demarcation OD	Yes	Attached	N/A	LP	18	
851/F	Chorioretinal, ONH, macula	Superotemporal to coloboma edge	V/SO injection OD	No	Attached	N/A	HM	24	
5/F	ONH	Edge of coloboma	1. V/APE/MP/drain SR fluid/EL/MP/SO OS 2. V/SO removal/MP/retinectomy/FAX/C3F8/EL 3. EUA/C3F8 OS	Yes	Attached	N/A	N/A	18	Developed PSC OS after multiple surgeries

Contd..

Table 1. Contd...

Age at time of RD (mos)/ Sex	Coloboma involvement	Location of retinal break	Surgery	Laser around coloboma	Anatomic Result	Preop VA	Postop VA	Follow up (mos)	Comment
299/M	ONH	Superotemporal to coloboma edge	SB/V/EL/FAX/SF6 OS	Yes	Attached	20/25	20/25	0.7	Superotemporal Giant retinal tear
84/F	ONH, macula, iris	Break not identified	V/PPL/FAX/SO OD	No	Attached	N/A	N/A	Lost to follow up	Avascular zone outside of coloboma, glaucoma OU
67/M	Chorioretinal, ONH	Within bed of coloboma	V/PPL/partial FAX OS	No	Attached	N/A	HM	2.25	MPPC Syndrome, Esotropia OS
55/M	ONH	Multiple breaks inside and outside coloboma	1. V/APE/EL/FAX/SO OD 2. V/PPL/capsulotomy/retinotomy/drainage of SR C3F8/SO (temponade agent) exchange/EL/Inf PI 3. Capsulectomy/Remove SO and SR fluid/serial FAX/MP/EL/FAX/SO/inf PI 4. EUA/Oil-air exchange	Yes	Attached	CF OD	LP	7	Developed zonular dehiscence and ACG after SO migrated into AC. Developed PVR and band keratopathy
46/F	Chorioretinal, ONH, iris	Multiple breaks inside and outside coloboma	1. V/MP/FGX/EL OD 2. V/PPL/C3F8 exchange OD 3. V/APE/MP/SR band removal/AFX/EL/SO injection OD	Yes	Attached	unknown	CF 2 inches	7	Developed PSC, pupillary membrane, and PVR. High astigmatism OU. Esotropia, nystagmus, amblyopia OD
109/F	Chorioretinal, ONH, iris	Outside of coloboma in periphery	APE/SB/cryo/C3F8/diathermy to break	No	Attached	20/300	20/400	7	Same patient as above

Total

RD, retinal detachment; mos, months; M, male, F, female; OD, right eye; OS, left eye; OU, both eyes; ONH, optic nerve head; SB, scleral buckle; APE, autologous plasmin enzyme; V, vitrectomy; MP, membranectomy; FAX, fluid air exchange; FGX, fluid gas exchange; C3F8, perfluorocarbon gas; SO, silicone oil; SF6, sulfur hexafluoride gas; EL, endolaser; CE, cataract extraction, PPL, pars plana lensectomy; IOL, intraocular lens; SR, subretinal; EUA, examination under anesthesia; PI, peripheral iridotomy; LP, light perception; HM, hand motion; CF, count fingers; N/A, not available; FEVR, familial exudative vitreoretinopathy; PSC, posterior subcapsular cataract; AC, anterior chamber; ACG, angle closure glaucoma; PVR, proliferative vitreoretinopathy; MPPC Syndrome, microcornea posterior megaleniconus; PFVS, persistent fetal vasculature syndrome

photocoagulation was performed around the margin of the coloboma in 50% (7/14) of eyes with retinal detachment.

Anatomic success in this series was defined as the retina remaining attached at the last follow-up visit, irrespective of the number of surgeries. The overall rate of anatomic success achieved after RD repair was 86% (12/14 eyes). Out of the 13 eyes that underwent vitrectomy, 11 (85%) had reattached retinas at the last follow-up visit. Of the 10 eyes that received silicone oil tamponade, 8 (80%) maintained anatomic success up to the last follow-up visit. Mean and median follow-up length for all surgeries was 40.8 and 11 months, respectively.

Final BCVA data were available for 10 out of 14 eyes with RD, as age was a limiting factor for measuring the BCVA in some children. Sixty percent (6/10) of eyes had the final vision of hand motion (HM) or light perception (LP). One eye had the final BCVA of 20/80 after scleral buckling. Another eye presenting with a macula-sparing giant retinal tear away from the margin of the coloboma showed the final BCVA of 20/25 after scleral buckling and pars plana vitrectomy (PPV) with gas tamponade.

Fourteen percent (7/51) of eyes with chorioretinal coloboma developed CNV. Two of the five (40%) affected individuals had bilateral CNV. Mean age at presentation was 21.8 years (range, 10.5 months to 67 years). The CNV was located at the margin of the coloboma and within the macula in all eyes. Management of CNV in this series consisted of either laser photocoagulation (5/7, 71.4% of eyes), intravitreal bevacizumab (1/7, 14.3% of eyes), or observation (1/7, 14.3% of eyes). The eye treated pharmacologically received two monthly intravitreal bevacizumab (IVB) injections over a 10-week period. Only one eye was observed. All eyes showed resolution of subretinal hemorrhage and intraretinal and subretinal fluid at the last follow-up visit. Final BCVA was available for 3 out of 5 patients. The information pertaining to each case of CNV, along with comparison to other cases reported in the literature, is summarized in Table 2. Mean and median follow up lengths for all CNV cases were 85.3 and 12 months, respectively.

The most common associated ocular feature was iris coloboma in 33% (16/49) of eyes. Other associated findings were CHARGE syndrome (coloboma, heart defects, atresia of the choanae, retardation of growth, genitourinary and ear abnormalities) in 7% (2/31) of patients, and MPPC syndrome (microcornea, posterior megalolenticonus, persistent fetal vasculature syndrome, coloboma) in 7% (2/31) of patients. Oculo-digital-dental syndrome (1/31 patients, 3%) and chromosome 22q11 gene deletion (1/31 patients, 3%) were noted as well.

## DISCUSSION

### Retinal Detachment in Eyes with Chorioretinal Coloboma

The incidence of RD in our series (31%) was within the range (2.4–42%) reported by prior studies.<sup>[1,4-6]</sup> The high rate of RD in our series is likely a consequence of sequestration bias, as our center is a tertiary referral center for vitreoretinal diseases.

RD occurring in the setting of chorioretinal coloboma is particularly challenging to repair.<sup>[1]</sup> In our study, 43% of eyes with RDs required multiple procedures to achieve anatomic success. Of the eyes that underwent surgery, 86% showed successful reattachment of the retina at the last follow-up visit (mean follow-up period,  $3.4 \pm 3.0$  years). Other reports in the literature cite success rates that range from 35–100% at last follow up visit.<sup>[5,7-18]</sup> Most notably, Gopal *et al* reported a 75% reattachment rate in the largest review of surgical management of RD in 85 colobomatous eyes.<sup>[9]</sup>

Previous authors have postulated that the area of neurosensory retina within the coloboma (referred to as the intercalary membrane) is the most common area for breaks and detachments.<sup>[1,9]</sup> In the current study, only 40% of RDs had tears within or at the margin of the coloboma, which falls on the lower end of previously reported rates of 38–100%.<sup>[7-10,12,13,19]</sup> Two colobomatous eyes in our study presented with a retinal tear without detachment, and both retinal breaks were located outside the colobomas. This may indicate the possibility of an abnormal vitreoretinal interface in colobomatous eyes that is not necessarily limited to the area of the coloboma and its margins. It also underscores the importance of conducting regular dilated funduscopy examinations focusing on the peripheral retina, in addition to the coloboma itself, for the identification of retinal tears.

Eyes with retinal breaks and detachment identified outside the margin of the coloboma may be managed with conventional scleral buckling techniques, though anatomical success rates are not encouraging, ranging from 35 to 57%.<sup>[8,10]</sup> Breaks that occur within or along the margin of the coloboma present a more complex surgical challenge.<sup>[7,13,19]</sup> PPV, intraocular tamponade with either silicone oil or gas, and endophotocoagulation over the margin of the coloboma are common techniques for managing such detachments.

PPV offers the ability to identify and treat breaks in the intercalary membrane by endophotocoagulation, cryotherapy, or cyanoacrylate glue.<sup>[12,17]</sup> In a review of surgical management of RD related to colobomas, Gopal and colleagues performed PPV and intraocular tamponade with either silicone oil (94%) or perfluoropropane (6%) in 85 eyes. They found that 81.2% of the retinas were still attached with a mean follow up of 13.4 months, and 69.4% of patients had final VA equal to or better than

**Table 2. Demographics, treatment details, and visual outcomes of patients who developed choroidal neovascular membranes**

Author	Case	Age (years)	Extent of coloboma involvement	CNVM along edge of coloboma	Treatment	Regression of CNVM	Initial VA	Final VA	Follow-up
Hussain et al	1	15	ONH, mac, iris OD	Yes	laser OD	Yes	20/200 OD	20/320 OD	16.25 years
	2	0.88	ONH, mac OU	Yes	laser OU	Yes	F+F OU	20/150 OD, HM OS	17.25 years
	3	1	ONH, mac OU	Yes	laser OU	Yes	F+F OU	F+F OU	10 months
	4	67	ONH, mac OU	Yes	IVB OS x2	Yes	CF OS	20/200 OS	2.4 months
	5	25	ONH, mac OU	Yes	observation	Yes	HM	HM	1 year
Goodwin et al <sup>[3]</sup>	6	1.5		Yes	IVR x2+laser	Yes	NR	NR	12 years
Naithani et al <sup>[31]</sup>	7	5	ONH, mac OD	Yes	IVB x2	Yes	3/60 OD	6/12	2 years
	8	8	ONH, mac OU	Yes	IVB	Yes	6/18 OS	6/12	2 years
Rajendran et al <sup>[30]</sup>	9	36	ONH, mac OD	Yes	IVB	Yes	6/36 OD	6/9	1 year
Bhende et al <sup>[32]</sup>	10	56	ONH, mac OU, iris OD	Yes	PDT+IVB	Yes	20/63 N6	20/32 N6	39 months
	11	21	ONH, mac, iris OU	Yes	PDT+IVB	Yes	20/120 N6	20/86 N6	11 months
	12	35	ONH, mac OS	Yes	PDT	Yes	20/32 N8	20/20 N6	5 months
Von Eicken et al <sup>[33]</sup>	13	5.5	ONH, mac	Yes	PDT	Yes	0.04	0.2	5.5 years
Maberley et al <sup>[24]</sup>	14	57	ONH, mac, iris OU	Yes	laser	Yes	20/50	20/50	NR
Brodsky et al <sup>[25]</sup>	15	1	ONH, mac, iris OD	Yes	laser		NR	NR	3 months
Steahly et al <sup>[26]</sup>	16	29	ONH, mac OU	Yes	laser x2	Yes	20/200	20/30	33 months
Guirgis et al <sup>[27]</sup>	17	1.75	ONH, mac OD	Yes	laser	Yes	N/A	20/100	63 months
Dailey et al <sup>[28]</sup>	18	48	ONH, mac OD	Yes	laser	Yes	20/50 OD	20/40	>1 year
Spitzer et al <sup>[29]</sup>	19	28	ONH, mac OU	Yes	laser x2	Yes	20/400 OS	20/160	12 years
Leff et al <sup>[34]</sup>	20	65	ONH and mac OU, iris OD	Yes	observation	NR	20/400 OD	NR	NR
	21	70	ONH, mac, iris OU	Yes	observation	NR	20/70 OD	NR	NR
Rouland et al <sup>[35]</sup>	22	26	ONH, mac, iris OU	Yes	observation		CF 6 feet	NR	NR
Gupta et al <sup>[23]</sup>	23	20	ONH, ma, iris colobomas OU	Yes	observation	NR	NR	NR	NR
Takenaka et al <sup>[22]</sup>	24	44	ONH, mac OU	Yes	observation	Yes	NR	0.2	6 years

Data from other papers is presented for comparison. OD, right eye; OS, left eye; OU, both eyes; VA, visual acuity; ONH, optic nerve head; Mac, macula; CNVM, choroidal neovascular membrane; RD, retinal detachment; IVB, intravitreal bevacizumab; IVR, intravitreal ranibizumab; PDT, photodynamic therapy; F+F, fix and follow; CF, count fingers; HM, hand motion; NR, not reported

10/200.<sup>[9]</sup> We believe that no single technique could be applied universally to all cases of chorioretinal coloboma with RD. The surgical planning should be individualized with careful preoperative assessment of the RD.

Colobomatous RD is difficult to repair successfully, and visual prognosis is guarded, particularly in cases involving the macula.<sup>[8]</sup> In our series, the visual outcomes of RD repair were similarly unfavorable, as 6 out of 10 eyes (60%) had BCVA of HM or worse. The four eyes with final BCVA better than HM developed retinal breaks outside the coloboma, and the detachments did not involve the macula. Only four eyes had preoperative BCVA measurements, and the postoperative BCVA for each eye was either stable or slightly worse at the last follow-up. The amblyogenic effects of RD at an early stage of visual pathway development must be considered when discussing the limited final visual acuities in these patients, some of them being very young.

Given the guarded visual prognosis and frequent need for multiple surgeries, some may question the utility of operating on eyes with colobomatous RDs. However, a previous review of pediatric RDs found that 38% of eyes that underwent surgical repair had equal or better BCVA compared to their fellow eye at the final follow-up.<sup>[20]</sup> Furthermore, 89% of those patients had bilateral involvement of ocular abnormalities that could potentially limit vision. In our series, 65% of patients had bilateral chorioretinal colobomas, placing them at heightened risk of potential vision loss from RD and CNV in both eyes. Within the context of potential future vision loss in the currently uninvolved eye, the decision to operate on such complicated eyes with generally guarded prognoses remains appropriate.

The difficult management of colobomatous RDs and the heightened risk of RD in the setting of colobomas compel us to consider the need for prophylactic laser in all patients with chorioretinal colobomas. A recent review of chorioretinal colobomas in a pediatric population found a prevalence of 2.9% for RD in eyes that received prophylactic laser around the margin of the coloboma, as compared to 24.9% in eyes that did not receive laser.<sup>[21]</sup> In our series, only 40% (6/15) of RDs had tears within or at the margin of the coloboma, and the two colobomatous eyes in our study that presented with a retinal tear without detachment had retinal breaks located outside the coloboma. Given our findings, if one were to decide to perform prophylactic laser in eyes with chorioretinal colobomas, a greater benefit may be provided by lasering both around the margin of the coloboma and around the vitreous base (360°). If the margin of the coloboma extends significantly into the macula or abuts the fovea, the risk for significant visual impairment caused by laser may outweigh the benefit of prophylaxis for RD. This issue must also be carefully considered intraoperatively during repair of a colobomatous RD.

## Choroidal Neovascularization in Eyes with Chorioretinal Colobomas

The literature regarding coloboma associated CNV is currently limited to case reports and small case series. To the authors' knowledge, the current series of 7 eyes (5 patients) with chorioretinal colobomas and associated CNV represent the largest series reported to date.

The untreated natural history of coloboma associated CNV ranges from spontaneous resolution<sup>[22]</sup> to progressive worsening of visual acuity.<sup>[23]</sup> The primary modalities available for treatment of CNV are intravitreal injections of anti-vascular endothelial growth factor (anti-VEGF), focal laser photocoagulation, and photodynamic therapy (PDT). Laser photocoagulation is the most frequently used method reported in the literature and has consistently resulted in regression of the CNV and improvement of visual acuity in these cases.<sup>[24-29]</sup> It is generally avoided in cases of juxtafoveal or subfoveal CNV due to the high risk of iatrogenic vision loss.

In this series, CNV generally developed at a young age (median age of 15 years). The three children treated with laser had a mean age of 5.6 years (range, 10 months to 15 years). All five eyes treated with laser showed regression of CNV at the last follow-up examination (mean follow-up period, 11.3 ± 8.8 years). Visual acuity data was available for one patient treated with laser, and BCVA remained stable at 20/200 two months after treatment. Other studies have reported improvements in BCVA of 20/200 to 20/30 (33-month follow-up), 20/50 to 20/40 (>1-year follow-up) and 20/400 to 20/160 (12-year follow-up).<sup>[26,28,29]</sup>

All eyes treated for CNV in our study showed regression of subretinal hemorrhage and fluid. Several authors have reported the use of anti-VEGF injections and/or PDT in treating coloboma related CNV, summarized in Table 2.<sup>[3,30-35]</sup> In the current series, intravitreal bevacizumab was used to successfully treat coloboma associated CNV in a 67-year-old patient with subfoveal hemorrhage and CNV. She had successful resolution of the hemorrhage and improvement in BCVA from CF to 20/200 at 2-month follow-up. The one patient who did not receive an intervention in our study had spontaneous regression of CNV after one month, and fluorescein angiography did not show evidence of leakage 12 months later.

Limitations of this study include its retrospective nature and limited patient population. Sequestration bias may skew the percentages toward a higher rate of CNV and RD, as patients with complex retinal pathology are more likely to be referred to a tertiary care center for management. Visual acuity data are limited in this study, as many patients were young children in whom visual acuity could not be reliably tested in the clinic setting.

In conclusion, chorioretinal colobomas are rare congenital anomalies that have potential to result in

complications of RD and CNV. In cases of coloboma associated RD, often times multiple surgeries are necessary to achieve anatomic success. It is possible that an abnormality of the vitreoretinal interface may play a role in RD, given that a high percentage of retinal breaks were not found within the coloboma boundaries in this study. Coloboma associated CNV usually arises on the border of the colobomas. These cases can be successfully managed with laser or anti-VEGF therapy.

## Financial Support and Sponsorship

Nil.

## Conflicts of Interest

There are no conflicts of interest.

## REFERENCES

- Jesberg DO, Schepens CL. Retinal detachment associated with coloboma of the choroid. *Arch Ophthalmol* 1961;65:163-173.
- Michaels RG, Wilkinson CP, Rice T. Retinal Detachment. St. Louis: The C.V. Mosby Company; 1990.
- Goodwin P, Shields CL, Ramasubramian A, Brown GC, Shields JA. Ranibizumab for coloboma-related choroidal neovascular membrane in a child. *J AAPOS* 2009;13:616-617.
- Maumenee IH, Mitchell TN. Colobomatous malformations of the eye. *Trans Am Ophthalmol Soc* 1990;88:123-132.
- Daufenbach DR, Ruttum MS, Pulido JS, Keech RV. Chorioretinal colobomas in a pediatric population. *Ophthalmology* 1998;105:1455-1458.
- Patnaik B, Kalsi R. Retinal detachment with coloboma of the choroid. *Indian J Ophthalmol* 1981;29:345-349.
- McDonald HR, Lewis H, Brown G, Sipperley JO. Vitreous surgery for retinal detachment associated with choroidal coloboma. *Arch Ophthalmol* 1991;109:1399-1402.
- Ramezani A, Dehghan MH, Rostami A, Ahmadi H, Entezari M, Soheilian M, et al. Outcomes of retinal detachment surgery in eyes with chorioretinal coloboma. *J Ophthalmic Vis Res* 2010;5:240-245.
- Gopal L, Badrinath SS, Sharma T, Parikh SN, Shanmugam MS, Bhende PS, et al. Surgical management of retinal detachments related to coloboma of the choroid. *Ophthalmology* 1998;105:804-809.
- Wang K, Hilton GF. Retinal detachment associated with coloboma of the choroid. *Trans Am Ophthalmol Soc* 1985;83:49-62.
- Fu SJ, Weng NQ. Retinal detachment associated with coloboma of choroid. *Zhonghua yan ke za zhi* 1989;25:15-17.
- Hanneken A, de Juan E, Jr, McCuen BW, 2<sup>nd</sup>. The management of retinal detachments associated with choroidal colobomas by vitreous surgery. *Am J Ophthalmol* 1991;111:271-275.
- Jalali S, Das T. Selection of surgical technique for retinal detachment with coloboma of the choroid. *Indian J Ophthalmol* 1994;42:27-30.
- Corcostegui B, Guell JL, Garcia-Arumi J. Surgical treatment of retinal detachment in the choroidal colobomas. *Retina* 1992;12:237-241.
- Teoh SC, Mayer EJ, Haynes RJ, Grey RH, Dick AD, Markham RH. Vitreoretinal surgery for retinal detachment in retinochoroidal colobomata. *Eur J Ophthalmol* 2008;18:304-308.
- Unlu N, Kocaoglan H, Acar MA, Aslan BS, Duman S. Surgical management of retinal detachment with choroidal coloboma. *Eur J Ophthalmol* 2002;12:299-303.
- Hotta K, Hirakata A, Hida T. The management of retinal detachments associated with choroidal colobomas by vitrectomy with cyanoacrylate retinopexy. *Jpn J Ophthalmol* 1998;42:323-326.
- Pal N, Azad RV, Sharma YR. Long-term anatomical and visual outcome of vitreous surgery for retinal detachment with choroidal coloboma. *Indian J Ophthalmol* 2006;54:85-88.
- Gopal L, Kini M, Badrinath SS, Sharma T. Management of retinal detachment with choroidal coloboma. *Ophthalmology* 1991;98:1622-1627.
- Fivgas GD, Capone A, Jr. Pediatric rhegmatogenous retinal detachment. *Retina* 2001;21:101-106.
- Uhumwangho OM, Jalali S. Chorioretinal coloboma in a paediatric population. *Eye* 2014;28:728-733.
- Takenaka J, Yimane K, Minamoto A, Mishima HK, Hayashida H. Subretinal neovascularization associated with retinochoroidal coloboma. *Eur J Ophthalmol* 2005;15:815-817.
- Gupta V, Gupta A, Dogra MR. Subretinal neovascularization associated with retinochoroidal coloboma. *Indian J Ophthalmol* 1997;45:116-117.
- Maberley AL, Gottner MJ, Antworth MV. Subretinal neovascularization associated with retinochoroidal colobomas. *Can J Ophthalmol* 1989;24:172-174.
- Brodsky MC, Ford RE, Bradford JD. Subretinal neovascular membrane in an infant with a retinochoroidal coloboma. *Arch Ophthalmol* 1991;109:1650-1651.
- Steahly LP. Laser treatment of a subretinal neovascular membrane associated with retinochoroidal coloboma. *Retina* 1986;6:154-156.
- Guirgis MF, Lueder GT. Choroidal neovascular membrane associated with optic nerve coloboma in a patient with CHARGE association. *Am J Ophthalmol* 2003;135:919-920.
- Dailey JR, Cantore WA, Gardner TW. Peripapillary choroidal neovascular membrane associated with an optic nerve coloboma. *Arch Ophthalmol* 1993;111:441-442.
- Spitzer M, Grisanti S, Bartz-Schmidt KU, Gerlisen F. Choroidal neovascularization in retinochoroidal coloboma: Thermal laser treatment achieves long-term stabilization of visual acuity. *Eye* 2006; 20:969-972.
- Rajendran A, Gupta SR, Brahadeesh S, Ramasamy K. Intravitreal bevacizumab for choroidal neovascularization associated with a retinochoroidal coloboma. *Eye* 2010; 24:933-934.
- Naithani P, Vashisht N, Mandal S, Sankaran P, Garg S. Intravitreal bevacizumab in choroidal neovascularization associated with congenital choroidal and optic nerve coloboma in children: Long-term improvement in visual acuity. *J AAPOS* 2010;14:288-290.
- Bhende M, Suganeswari G, Gopal L, Bhende PS, Gopal L, Rao C. Choroidal neovascularization associated with coloboma of the choroid: A series of three cases. *Indian J Ophthalmol* 2011;59:148-151.
- von Eicken J, Hoh H, Rehfeldt K. Photodynamic therapy for choroidal neovascularisation due to choroidal coloboma in a 5 1/2-year-old child. *Klin Monbl Augenheilkd* 2007;224:140-145.
- Leff SR, Britton WA, Jr., Brown GC, Lucier AC, Brown JF. Retinochoroidal coloboma associated with subretinal neovascularization. *Retina* 1985;5:154-156.
- Rouland JF, Constantinides G. Retinochoroidal coloboma and subretinal neovascularization. *Ann Ophthalmol* 1991;23:61-62.