

Case Report

Response to Paclitaxel in an Adult Patient with Advanced Kaposiform Hemangioendothelioma

José Maurício Mota Mariana Scaranti Leonardo G. Fonseca
Diego Araújo Tolói Veridiana Pires de Camargo
Rodrigo Ramella Munhoz Olavo Feher Paulo M. Hoff

Medical Oncology Division, Instituto do Câncer do Estado de São Paulo, Universidade de São Paulo, São Paulo, Brazil

Keywords

Kaposiform hemangioendothelioma · Sarcoma · Paclitaxel

Abstract

Background: Kaposiform hemangioendothelioma (KHE) is a rare neoplasm of vascular origin that typically arises from the skin or soft tissues as a solitary tumor. The optimal therapy for this disease is still unknown. We report the case of an adult patient presenting with metastatic KHE of the spleen, who had a partial response after treatment with paclitaxel. **Case Presentation:** A 36-year-old man presented in November 2012 with a nontraumatic rupture of the spleen. A splenectomy was performed, and the pathology was consistent with a non-specific vascular proliferation. Follow-up scans revealed lytic bone lesions and liver metastasis. A biopsy of the liver was performed and confirmed KHE. The decision was made to proceed with treatment with gemcitabine and docetaxel, which was discontinued due to myelotoxicity. The patient was then transferred to our institution, and a pathology review supported the diagnosis of metastatic KHE. His disease remained stable until February 2014, when he developed progression in the liver. Chemotherapy was restarted with paclitaxel, and a partial response was documented after 3 cycles. Unfortunately, disease progression occurred after 24 weeks, and subsequent treatments included prednisone, doxorubicin, interferon- α , gemcitabine, and ifosfamide, without any response. The patient developed Kasabach-Merritt phenomenon and passed away 1 week later due to a major gastrointestinal bleeding. **Con-**

clusions: This case report suggests that paclitaxel could be considered as a treatment option for advanced KHE, a rare condition for which no standard treatment exists.

© 2016 The Author(s)
Published by S. Karger AG, Basel

Background

Kaposiform hemangioendothelioma (KHE) is a rare neoplasm of vascular origin typically arising from the skin or soft tissues, and it is more often described in children [1]. The term ‘kaposiform’ refers to its morphological resemblance to Kaposi sarcoma. The tumor is composed of irregular lobules of small malformed vessels with sheets of spindle cells and infiltrating nodules. Previously, KHE has been compared to other vascular abnormalities such as juvenile hemangiomas, tufted angiomas, capillary hemangiomas, and Kaposi sarcoma [2]. The immunohistochemistry assessment is crucial for a proper differential diagnosis. Tumor cells typically express endothelial markers, such as CD31 and CD34 [3].

In the largest cohort of patients with KHE including 107 cases, the disease occurred in infancy in 93% of cases; only 11% of patients presented with noncutaneous KHE, the majority of them in bone, mediastinum, or retroperitoneum [4]. KHE can be associated with the development of Kasabach-Merritt phenomenon (KMP) in up to 71% of the cases [4]. In this life-threatening syndrome, severe thrombocytopenia and hypofibrinogenemia occur as a result of intralesional platelet trapping [4]. Despite the locally aggressive behavior and the potential for lethal complications due to consumptive coagulopathy in the setting of KMP, metastatic spread of KHE seldom occurs [1].

Here, we present the case of a patient with KHE with several atypical features, namely onset in adulthood, primary presentation in the spleen, and metastatic spread to the liver and bones, with a partial response to treatment with paclitaxel.

Case Report

A 36-year-old Caucasian male presented to the Emergency Department with acute onset of abdominal pain in the left upper quadrant in November 2012. He denied fever, nausea, or any trauma in the previous days. There were no gastrointestinal or urinary complaints. Abdominal tenderness in the left upper quadrant was noteworthy. A computed tomography (CT) scan revealed a 16 × 11 × 24 cm splenic mass with signs of splenic rupture. Exploratory laparotomy was performed with an intraoperative finding of spontaneous splenic rupture and active subcapsular bleeding. A splenectomy was performed, and the patient was discharged without any additional complications. Initial external pathology assessment of the mass indicated a nonspecific vascular proliferation, and the patient started follow-up with his primary care physician.

Surveillance CT scans performed in January 2013 revealed enlarged cervical and mediastinal lymph nodes, lytic bone lesions in vertebral bodies, a 1.7-cm peritoneal node, and a punctate lesion in the skullcap. Short-interval imaging repeated in May 2013 detected additional vertebral lesions and multiple hepatic metastases. The initial recommendation included systemic treatment with gemcitabine and docetaxel, and treatment was started in July 2013, with significant hematological toxicity, leading to treatment discontinuation. The patient was then referred to our institution.

A pathology review showed endothelial cells with lobular-pattern proliferation; immunohistochemical staining revealed positivity for vimentin, CD34, and CD31 and negativity for HHV8, S-100, and smooth muscle actin. Ki-67 antigen was expressed in 5% of the cells (fig. 1a–d); the diagnosis was consistent with KHE. The decision was made to withhold the systemic treatment and periodically repeat the scans every 3 months, since there was no clear evidence of progression.

Although the patient remained asymptomatic for 6 months, CT scans showed an increase in the number and volume of hepatic lesions (fig. 2a), and paclitaxel was started. After 18 weeks, restaging CT scans revealed stability of the vertebral lesions and reduction of the hepatic lesions (table 1; fig. 2b), consistent with a 40% reduction based on investigator-assessed RECIST criteria. Paclitaxel was continued until October 2014 (total of 24 weeks), when restaging scans revealed disease progression. Table 2 summarizes the treatment lines and table 1 the sequence of imaging assessments.

Subsequent lines of treatment included oral prednisone, doxorubicin, interferon- α , gemcitabine, and ifosfamide, with no radiologic response or clinical benefit. Although the patient remained with mild to moderate symptoms and adequate performance status, the decision was made to offer best supportive care, and the patient was referred to a palliative care service. After 2 months, the patient had acute onset of thrombocytopenia, hypofibrinogenemia, petechiae, and epistaxis. One week after the presumptive diagnosis of KMP was made, the patient died due to a major episode of gastrointestinal bleeding.

Discussion

Atypical presentations of KHE have been reported in the bones, breast, thymus, thyroid, ductus choledochus, or retroperitoneum [1]. KHE from the spleen has been previously described in a single case by Yu and Yang [5], with long-term recurrence-free survival after splenectomy. The case reported here presents several atypical features, namely the age at onset and the pattern of distant spread. In addition, KMP was described in 70% of the cases in the largest published cohort of patients with KHE [3], usually in patients with muscle or fascia involvement, retroperitoneal disease, or mediastinal involvement [4]. Rare cases of metastatic KHE have been reported. Lisle et al. [6] described multilevel spinal involvement in a 6-year-old girl with KHE that responded to systemic therapy.

Due to the rarity of this condition, the optimal management of patients with KHE remains unclear, and treatment options are supported by small series and single case reports. Whenever feasible, complete surgical resection should be recommended. However, complete resection is not always possible due to the infiltrative and locally aggressive nature of KHE [1]. Medical therapies in the setting of unresectable/metastatic KHE aim to decrease the tumor size, revert KMP, and palliate symptoms. Corticosteroids are widely used. A consensus meeting suggested oral prednisolone 2 mg/kg/day as the first-line therapy for infant cases with enlarging, unresectable masses requiring intervention without KMP [7]. Additional responses were seen with vincristine [8], interferon- α [9], actinomycin D, cyclophosphamide, and sirolimus [1].

Based on the lack of prospective data addressing the optimal treatment for KHE, extrapolating the experience with the treatment of other vascular tumors was a strategy for the present case. Paclitaxel was recommended in the present case and resulted in partial response after 3 cycles. This semisynthetic taxane showed clinical benefit in a phase II trial in patients with angiosarcoma [10]. Interestingly, very low concentrations of paclitaxel proved

to inhibit endothelial cell proliferation in an in vitro environment [11]. Funato et al. [12] had previously described the first evidence of paclitaxel-based chemotherapy in a case of metastatic KHE. To the best of our knowledge, our report is the second KHE case in the literature documenting an objective response after treatment with paclitaxel. In a retrospective analysis from the Memorial Sloan Kettering Cancer Center, first-line doxorubicin, liposomal doxorubicin, or paclitaxel produced response rates of 25–31%, with equivalent overall survivals in patients with angiosarcoma. Improved survival did not result from combination therapies [13]. Molecular therapies may also benefit patients with vascular sarcomas. Despite disappointing results in a phase II study with nonselected patients with sarcomas [14], sorafenib led to clinically relevant responses in radiation-associated breast angiosarcomas with MYC and FLT4 amplifications [15]. Of note, tyrosine kinase or mTOR inhibitors or antiangiogenic agents were not offered to the present patient since these molecules are not available for routine use in our institution for this indication.

Conclusions

In summary, this case illustrates an unusual presentation of KHE with metastatic spread to the liver and bones, in which the patient experienced a partial response to paclitaxel-based chemotherapy. Due to the lack of prospective data, we consider reports such as ours of importance for improving the knowledge about this rare and challenging condition.

Statement of Ethics

Written informed consent was obtained from the patient for publication of this case report and accompanying images.

Disclosure Statement

The authors declare that they have no conflicts of interest regarding this article.

References

- 1 Drolet BA, Trenor CC, Brandão LR, Chiu YE, Chun RH, Dasgupta R, et al: Consensus-derived practice standards plan for complicated kaposiform hemangioendothelioma. *J Pediatr* 2013;163:285–291.
- 2 Mentzel T, Mazzoleni G, Dei Tos AP, Fletcher CDM: Kaposiform hemangioendothelioma in adults: clinicopathologic and immunohistochemical analysis of three cases. *Am J Clin Pathol* 1997;108:450–455.
- 3 Debelenko LV, Perez-Atayde AR, Mulliken JB, Liang MG, Archibald TH, Kozakewich HPW: D2-40 immunohistochemical analysis of pediatric vascular tumors reveals positivity in kaposiform hemangioendothelioma. *Mod Pathol* 2005;18:1454–1460.
- 4 Croteau SE, Liang MG, Kozakewich HP, Alomari AI, Fishman SJ, Mulliken JB, et al: Kaposiform hemangioendothelioma: atypical features and risks of Kasabach-Merritt phenomenon in 107 referrals. *J Pediatr* 2013;162:142–147.
- 5 Yu L, Yang SJ: Kaposiform hemangioendothelioma of the spleen in an adult: an initial case report. *Pathol Oncol Res* 2011;17:969–972.
- 6 Lisle JW, Bradeen HA, Kalof AN: Case report: kaposiform hemangioendothelioma in multiple spinal levels without skin changes. *Clin Orthop Relat Res* 2009;467:2464–2471.

- 7 Hardisson D, Prim MP, De Diego JL, Patrón M, Escribano A, Rabanal I: Kaposiform hemangioendothelioma of the external auditory canal in an adult. *Head Neck* 2002;24:614–617.
- 8 Haisley-Royster C, Enjolras O, Frieden IJ, Garzon M, Lee M, Oranje A, et al: Kasabach-Merritt phenomenon: a retrospective study of treatment with vincristine. *J Pediatr Hematol Oncol* 2002;24:459–462.
- 9 Barlow CF, Priebe CJ, Mulliken JB, Barnes PD, MacDonald D, Folkman J, et al: Spastic diplegia as a complication of interferon Alfa-2a treatment of hemangiomas of infancy. *J Pediatr* 1998;132:527–530.
- 10 Penel N, Bui BN, Bay JO, Cupissol D, Ray-Coquard I, Piperno-Neumann S, et al: Phase II trial of weekly paclitaxel for unresectable angiosarcoma: the ANGIOTAX study. *J Clin Oncol* 2008;26:5269–5274.
- 11 Pasquier E, Honore S, Pourroy B, Jordan MA, Lehmann M, Briand C, et al: Antiangiogenic concentrations of paclitaxel induce an increase in microtubule dynamics in endothelial cells but not in cancer cells. *Cancer Res* 2005;65:2433–2440.
- 12 Funato M, Fukao T, Sasai H, Hori T, Terazawa D, Kanda K, et al: Paclitaxel-based chemotherapy for aggressive kaposiform hemangioendothelioma of the temporomastoid region: case report and review of the literature. *Head Neck* 2013;35:691–696.
- 13 D'Angelo SP, Munhoz RR, Kuk D, Landa J, Hartley EW, Bonafede M, et al: Outcomes of systemic therapy for patients with metastatic angiosarcoma. *Oncology* 2015;89:205–214.
- 14 von Mehren M, Rankin C, Goldblum JR, Demetri GD, Bramwell V, Ryan CW, et al: Phase 2 Southwest Oncology Group-directed intergroup trial (S0505) of sorafenib in advanced soft tissue sarcomas. *Cancer* 2012;118:770–776.
- 15 Angelo SPD, Antonescu CR, Keohan ML, Carvajal RD, Dickson MA, Mrinal M, et al: Activity of sorafenib in radiation-associated breast angiosarcomas harboring MYC and FLT4 amplifications. *J Clin Oncol* 2012;30:9–11.

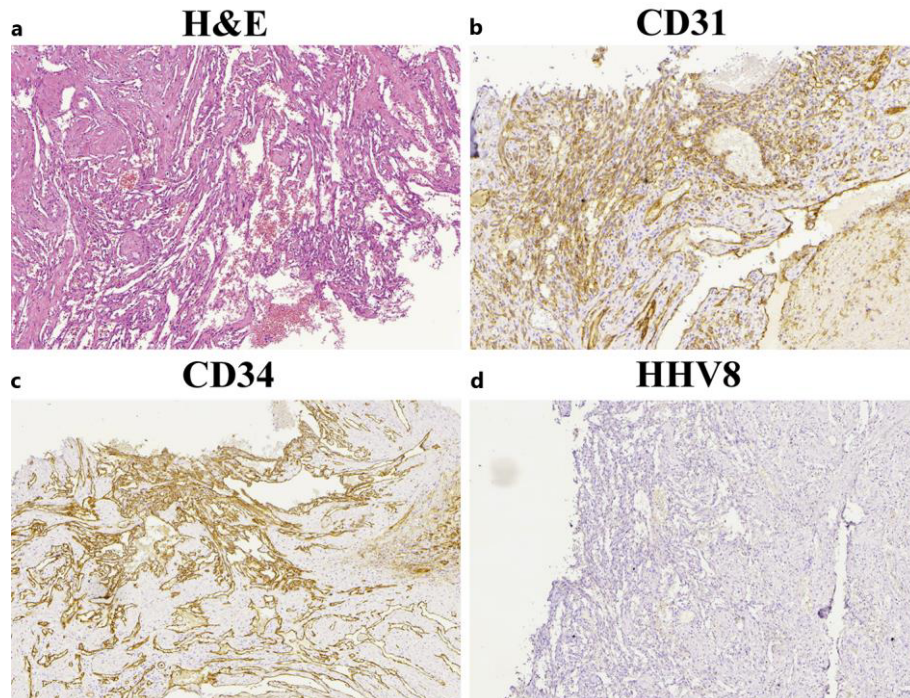


Fig. 1. Immunohistochemistry assessment of the primary splenic lesion. **a** HE-stained microphotograph reveals spindle-shaped cells growing in an apparent lobular pattern. Positivity to CD31 (**b**) and CD34 (**c**) in neoplastic cells. **d** Negativity to HHV8 for the differential diagnosing with Kaposi sarcoma. Microphotographs are amplified 5×.

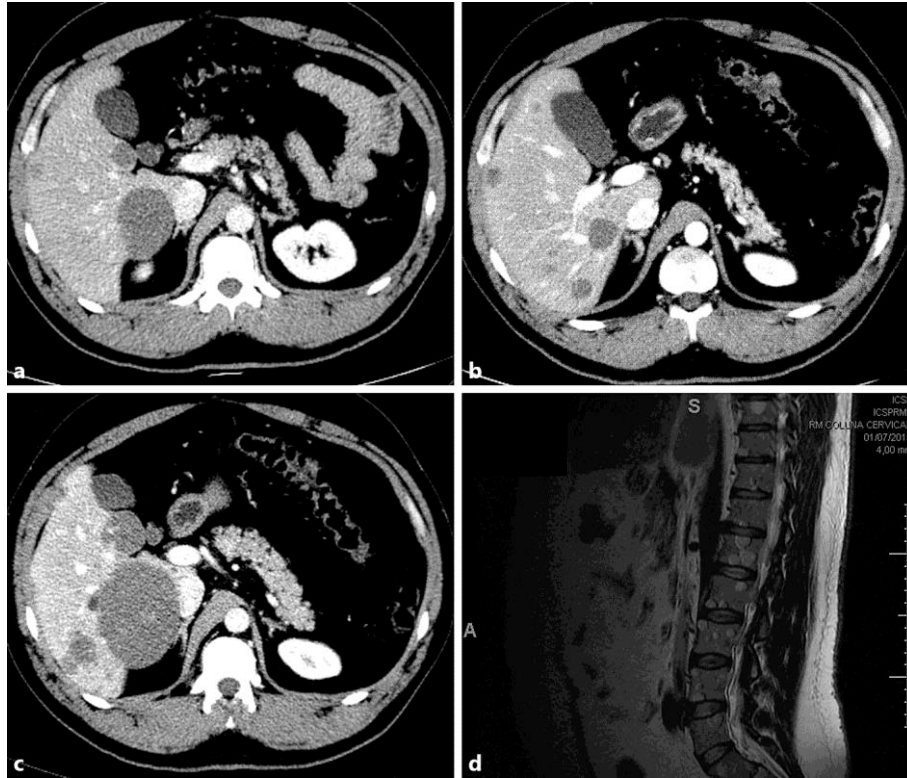


Fig. 2. Imaging of metastatic lesions and partial response after treatment with paclitaxel. **a** CT scans done on February 13, 2014, showed multiple hepatic lesions, the largest measuring 5.4 cm. **b** CT scans done on May 7, 2014, detected partial response after paclitaxel treatment for 9 weeks. **c** CT scans done on December 11, 2014, revealed disease progression after treatment with prednisone 1 mg/kg/day. **d** T2-weighted backbone magnetic resonance imaging done on July 1, 2015, revealed diffuse and multiple nodular lesions.

Table 1. Sequence of imaging assessments, size of the largest lesion, and best responses

Imaging	Date, month/day/year	Size of the largest hepatic lesion, cm	Novel lesions	Observation	Best response
CT	08/02/13	2.6	–	–	NA
CT	11/03/13	4.2	–	–	DP
CT	02/13/14	5.4	–	–	DP
CT	05/07/14	3.0	–	after paclitaxel for 9 weeks	PR
CT	08/05/14	3.0	–	after paclitaxel for 18 weeks	SD
CT	10/10/14	4.6	–	after paclitaxel for 24 weeks	DP
CT	12/11/14	8.0	–	after prednisone for 16 weeks	DP
CT	03/06/15	8.5	–	after doxorubicin for 9 weeks	DP
CT	06/10/15	6.0	right adrenal (4 cm)	after interferon- α for 12 weeks	PR
MRI	07/01/15	NA	–	multiple and diffuse backbone lesions	NA
CT	08/19/15	6.7	–	after gemcitabine for 4 weeks	DP

NA = Not applicable; CT = computed tomography of the thorax, abdomen, and pelvis, except for the CT made on 08/19/15 (only thorax); MRI = magnetic resonance imaging; PR = partial response; SD = stable disease; DP = disease progression.

Table 2. Treatment regimens and best outcomes obtained

Treatment	Regimen	Cycles	Duration, weeks	Best response
Gemcitabine and docetaxel ^a	unknown	unknown	unknown	unknown
Paclitaxel	80 mg/m ² weekly	8	24	PR
Prednisone	1 mg/kg o.d.	NA	16	DP
Doxorubicin	60 mg/m ² q21 days	3	9	DP
Interferon- α	3 million units t.i.w.	NA	12	DP
Gemcitabine	1,000 mg/m ²	1	4	DP
Ifosfamide	9 g/m ² divided in 5 doses q21 days	3	9	DP

NA = Not applicable; PR = partial response; DP = disease progression. ^a Outside our institution.