



Contents lists available at ScienceDirect

International Journal of Surgery Case Reports

journal homepage: www.casereports.comSplenic metastases from caecal carcinoma: Diagnostic considerations and therapeutic strategy[☆]T.P. Burke^a, P.S. Waters^a, J. Hanaghan^b, F. Bennani^c, W. Khan^a, K. Barry^{a,*}^a Department of Surgery, Mayo General Hospital, Mayo, Ireland^b Department of Radiology, Mayo General Hospital, Mayo, Ireland^c Department of Pathology, Mayo General Hospital, Mayo, Ireland

ARTICLE INFO

Article history:

Received 28 August 2013

Accepted 3 September 2013

Available online 9 September 2013

Keywords:

Caecal adenocarcinoma

Splenic metastases

Image guided biopsy

Carcinoembryonic antigen

ABSTRACT

INTRODUCTION: The spleen is a highly vascular organ and is in close proximity to many potential primary sites such as the stomach, breast, pancreas and colon. It is however an unusual site for metastatic disease. The reasons for this are not fully understood at the present time. A number of hypotheses have been postulated. Definitive diagnosis and subsequent treatment of metastatic disease to the spleen presents a number of challenges for the surgeon and the wider multi disciplinary team.

PRESENTATION OF CASE: A 60 year old male presented with a three week history of lower abdominal pain, distension, nausea and a palpable mass in the right iliac fossa. Imaging revealed a large circumferential caecal mass consistent with malignancy with secondary small bowel obstruction. The patient underwent an emergency right hemicolectomy and was subsequently treated with systemic chemotherapy for lymph node positive caecal adenocarcinoma. Two years following initial presentation, two suspicious lesions were noted within the spleen during routine surveillance imaging with computerised tomography of the thorax, abdomen and pelvis. Of note, one month prior to this the patient had a normal surveillance colonoscopy performed with multiple interval carcinoembryonic antigen (CEA) levels recorded within the normal range. Image guided splenic biopsy and subsequent histology confirmed metastatic caecal adenocarcinoma.

DISCUSSION: Splenic metastases from any source including the colon are a rare phenomenon.

CONCLUSION: This case questions the value of routine post operative CEA monitoring, underlines the importance of multimodal pathways of surveillance and highlights recent advances in image guided splenic biopsy techniques.

© 2013 The Authors. Published by Elsevier Ltd on behalf of Surgical Associates Ltd. All rights reserved.

1. Introduction

Metastases to the spleen from various sites are a rare occurrence and usually occur in the presence of widely disseminated disease.¹ Previously documented sites of primary disease include the ovaries, melanoma, breast, lung and the colon and are typically associated with high disease burden. Splenic metastases from the colon involving low levels of disease burden are rare in the literature and to date, there have been only two documented cases of metastases to the spleen originating from a caecal tumour^{2,3}.

2. Case report

A 60 year old male with no significant past medical history presented to the emergency department with a three week history of

lower abdominal pain, nausea and a palpable mass in the right iliac fossa. Computerised tomography (CT) of the abdomen and pelvis demonstrated a large circumferential obstructing tumour of the caecum without evidence of distant metastases (Fig. 1). The patient was prepared for surgery, consisting of a right hemicolectomy with an uncomplicated postoperative course. Histology from the excised specimen revealed a poorly differentiated adenocarcinoma with signet ring cell permeation through the muscularis propria. Lymph node analysis comprised twenty one lymph nodes, all noted to contain metastatic spread. Additional CT of thorax performed in the post operative period was reported as normal. The presenting tumour was therefore classified pathologically as stage III caecal adenocarcinoma (pT3N2M0). Carcinoembryonic antigen measured prior to surgery was recorded within normal limits (3 ng/L).

Two months post surgical resection, the patient underwent adjuvant chemotherapy utilising the FOLFOX protocol as discussed at the multidisciplinary conference. He received 12 cycles of chemotherapy however the dose of oxaliplatin was reduced after cycle six due to development of thrombocytopenia and a slight rise in CEA level, both of which were attributed to the chemotherapeutic agent (Table 1). He completed his course of adjuvant chemotherapy eight months after initial presentation. The patient was then

[☆] This is an open-access article distributed under the terms of the Creative Commons Attribution-NonCommercial-No Derivative Works License, which permits non-commercial use, distribution, and reproduction in any medium, provided the original author and source are credited.

* Corresponding author. Tel.: +353 94 9028044.

E-mail address: kbarsurg@eircom.net (K. Barry).

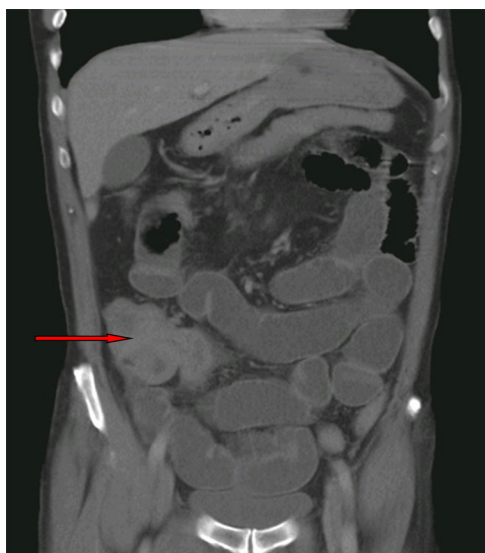

Fig. 1. CT image at presentation demonstrating a large caecal neoplasm with concurrent small bowel obstruction.

Table 1
Surveillance.

Test	Result (ng/ml)
CEA June 2011	3
CEA October 2011	6
CEA November 2011	5.2
CEA January 2012	5.7
Restaging CT May 2012	No evidence of metastatic disease
CEA May 2012	2.4
Colonoscopy	Normal
Follow up CT May 2013	Two splenic lesions

entered into a standard programme of routine surveillance consisting of regular clinical reviews, interval measurement of CEA levels, colonoscopy and yearly CT of thorax, abdomen and pelvis. Although surveillance studies proved negative initially for disease recurrence, a routine CT thorax, abdomen and pelvis at twenty three months post initial presentation revealed left sided para

aortic lymphadenopathy and two suspicious splenic lesions measuring 2.7×2.5 cm and 2.4×2.2 cm respectively which were not present on imaging, performed twelve months previously (Fig. 2 A and B). The patient was completely asymptomatic at the time of metastatic presentation.

The splenic lesions were biopsied under ultrasound guidance using an 18 gauge tru cut needle without complication (Fig. 3). Subsequent histology of the biopsied lesions revealed normal splenic parenchyma infiltrated by poorly differentiated adenocarcinoma with abundant signet ring cells, morphologically identical to the initial presentation with an obstructing caecal tumour (Fig. 3C). Further discussion at the multidisciplinary conference ensued. The disease although of low burden and primarily localised to the spleen was associated with the presence of suspicious para aortic lymphadenopathy prompting chemotherapy rather than operative intervention. The oncology team advised further systemic chemotherapy comprising 5 – fluorouracil, oxaliplatin and avastin. The patient remains well on chemotherapy and further imaging studies are planned in 4 months time to assess response to treatment.

3. Discussion

Metastases to the spleen from any primary tumour are rare despite the highly vascular nature of the organ and it’s proximity to many potential primary sites including the pancreas, stomach, lung, breast and the colon. A number of theories have been put forward to explain the “hostile” nature of the spleen preventing tumour implantation and proliferation of neoplastic cells. These encompass intrinsic anatomical, histological and immunological features of the spleen.^{4,5} Anatomical features thought to play a role include the sharp angle at the origin of the splenic artery with the coeliac axis, the rhythmic contraction of splenic sinusoids and the scarcity of lymphatic vessels extending to the intrasplenic parenchyma. Immunological factors considered to negatively impact on the rate of malignant cell implantation include the presence of abundant kupffer cells, immunoglobulin synthesis and opsonin production.

In most of the reported cases of colorectal metastases to the spleen, the primary tumour is located on the left side of the colon or in the rectum.⁶ This distribution of colorectal metastases favours the theory that neoplastic cells reach the spleen via retrograde

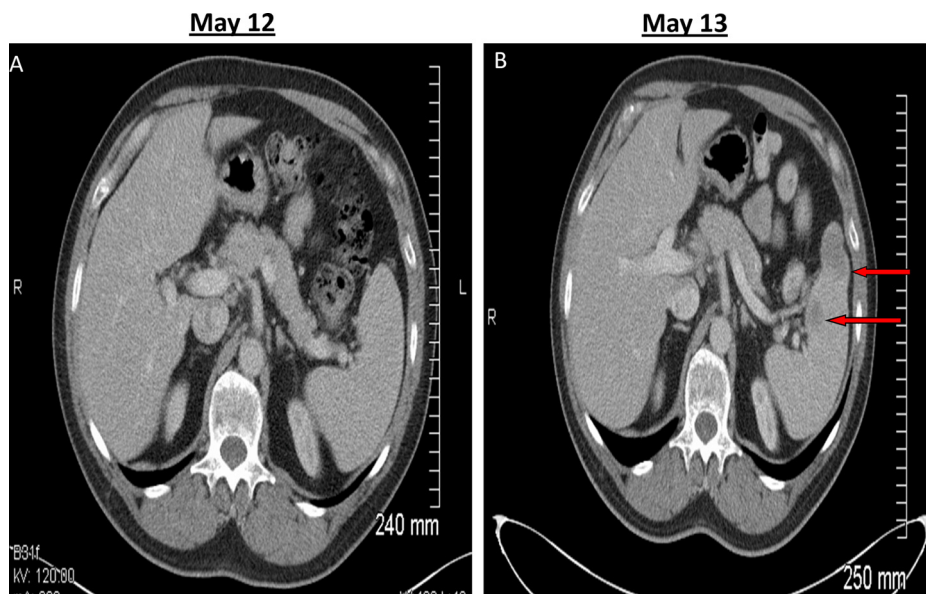


Fig. 2. Surveillance CT demonstrating a normal CT in May 2012 and abnormal CT with two splenic lesions 1 year later.

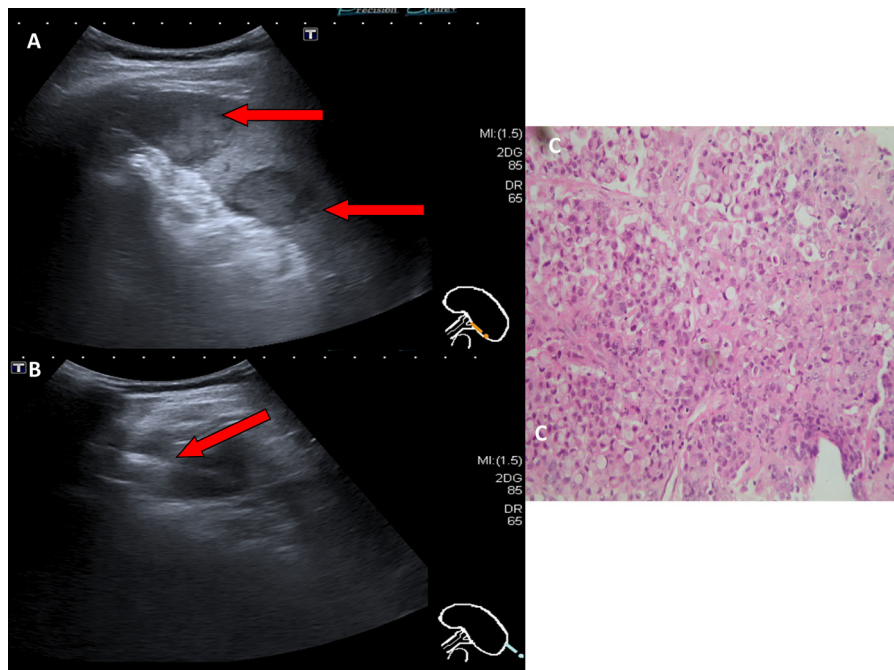


Fig. 3. US biopsy of splenic lesion demonstrating biopsy needle through the metastatic deposit and the histology slide displaying histological confirmation of metastatic disease.

dissemination through the inferior mesenteric vein.⁷ To the best of our knowledge, there have been only two previous cases of caecal adenocarcinoma metastasising to the spleen recorded in the literature without infiltration of other solid organs.^{2,3} Furthermore, there have only been 4 additional cases of right sided colonic cancer (all ascending colon) with metastases to the spleen recorded.⁶ Given the additional presence of left sided para aortic lymphadenopathy in our patient, this could possibly indicate tumour spread via the lymphatic system.

Carcinoembryonic antigen (CEA) is an oncofetal protein used as a tumour marker. It is not routinely used as a screening tool as it lacks sensitivity and specificity. However it is widely used as part of surveillance programmes to monitor for disease recurrence in conjunction with colonoscopy, imaging and follow up clinic appointments. It has been shown that in 30–40% of cases of disease recurrence there is no corresponding rise in CEA levels.⁸ Furthermore in cases where CEA levels were recorded as normal at initial presentation, it was reported that in cases of recurrence, a corresponding elevation in CEA is only observed in 27% of cases.⁹ In one large study, it was noted that CEA monitoring did not result in improved survival.¹⁰ This brings into question the value of interval CEA monitoring as part of surveillance programmes post resection for colorectal cancers.

Historically the technique of percutaneous splenic biopsy was not widely performed due to the perceived high complication rates mostly involving haemorrhage. With the advent of improved imaging modalities, splenic biopsies can now be performed relatively safely using either ultrasound or CT guided techniques. Ultrasound is currently favoured over CT due to the real time images projected. The differential of a solid splenic lesion includes metastases, an infarct or a splenic abscess. Adequate collection of targeted tissue suitable for histological analysis has been recorded at 88% in one series. Complication rates were found to be directly proportional to the gauge of needle used in the procedure.¹¹

Given the limited number of cases recorded in the literature, the optimal treatment for splenic metastases from a colorectal primary is not known. In cases of isolated splenic metastases from a

colonic source, splenectomy is preferred to chemo/radio therapy. In the literature, this has been performed by both the traditional open technique and more recently laparoscopically.¹² To date disease free intervals and survival are reported to be similar for both techniques. Chemotherapy is currently favoured in circumstances where disease is recorded in other sites including the spleen. The current data available is too small to draw any definitive conclusions regarding the optimal treatment for splenic metastases in the context of low disease burden.

4. Conclusion

This case illustrates a number of important features regarding splenic metastases from caecal carcinoma. Firstly, multimodal imaging is important in the context of asymptomatic patients and especially given the limited sensitivity of CEA measurements. Second, modern image guided biopsy techniques facilitate accurate and safe percutaneous biopsy of suspicious splenic lesions. Third, further research is necessary to determine the optimal treatment of splenic metastases from a colonic source with a low disease burden.

Conflict of interest statement

None declared.

Funding

None.

Ethical approval

Written informed consent was obtained from the patient for publication of this case report and accompanying images. A copy of the written consent is available for review by the Editor-in-Chief of this journal on request.

Author contributions

Thomas Patrick Burke is the Primary author of the Paper. Peadar Waters helped in the review of article and compiling of images. John Hanaghan helped in the review of Radiology of the case. Fadel Benani helped in the review of pathology. Waqar Khan helped in the review of case and literature. Kevin Barry helped in the final review of article prior to submission including editing and layout.

Acknowledgments

None.

References

1. Berge T. Splenic metastases. Frequencies and patterns. *Acta Pathol Microbiol Scand A* 1974;**82**:499–506.
2. Tamesa T, Watanabe Y, Yoshimura K, Mori N, Yamamoto S, Hazama S, Tangoku A, Oka M. *Gan To Kagaku Ryoho* 2004;**31**(11):1864–6.
3. Slavin JD, Mathews J, Spencer RP. Splenectomy for splenic metastasis from carcinoma of colon. *Clin Nucl Med* 1986;**11**:491–2.
4. Skandalakis LJ, Gray SW, Skandalakis JE. Splenic realities and curiosities. *Prob Gen Surg* 1990;**7**:28–32.
5. Kim JC, Roh SA, Park KC. Adhesive function of carcinoembryonic antigen in the liver metastasis of KM-12c colon carcinoma cell line. *Dis Colon Rectum* 1997;**40**:946–53.
6. Abi Saad George S, Maher Hussein, El-Saghir Nagi S, Salah Termos, Sharara Ala I, Ali Shamseddine. Isolated splenic metastasis from colorectal cancer. *Int J Clin Oncol* 2011;**16**:306–13.
7. Induhara R, Vogt D, Levin HS, Church J. Isolated splenic metastases from colon cancer. *South Med J* 1997;**90**:633–6.
8. Benson III AB, Desch CE, Flynn PJ, Krause C, Loprinzi CL, Minsky BD, et al. *J Clin Oncol* 2000;**18**:3586.
9. Park IJ, Choi GS, Lim KH, Kang BM, Jun SH. Serum carcinoembryonic antigen monitoring after curative resection for colorectal cancer: clinical significance of the preoperative level. *Ann Surg Oncol* 2009;**16**:3087.
10. Jeffery M, Hickey BE, Hider PN. Follow-up strategies for patients treated for non-metastatic colorectal cancer. *Cochrane Database Syst Rev* 2007 [CD 002200].
11. Singh Ajay K, Sridhar Shankar, Gervais Debra A, Hahn Peter F, Mueller Peter R. Image guided percutaneous splenic interventions. *Radiographics* 2012;**32**:523–34.
12. Lopez Monclova J, Targarona Soler E, Peraza Solis Y, Vidal Gonzalez P, Balague Ponz C, Rodriguez Luppi C, Trias Folch M. *Surg Laparosc Endosc Percutan* 2013;**1**:21–4.

Open Access

This article is published Open Access at sciedirect.com. It is distributed under the [IJSCR Supplemental terms and conditions](#), which permits unrestricted non commercial use, distribution, and reproduction in any medium, provided the original authors and source are credited.