

Endometrial carcinoma in asymptomatic post-menopausal women with a thickened endometrium and its influencing factors - A cross-sectional study

Bhabani Pegu¹, Sri Saranya T¹, Rajeswari Murugesan²

Departments of ¹Obstetrics and Gynecology and ²Biostatistics, JIPMER, Puducherry, India

ABSTRACT

Background: A thickened endometrium upon trans-vaginal ultrasound in asymptomatic post-menopausal women always poses a clinical dilemma. **Objectives:** To investigate the frequency of endometrial malignancies by histopathological examination and identify the associated factors influencing the thickened endometrium in asymptomatic post-menopausal women. **Methods:** In trans-vaginal ultrasonography, we enrolled 72 asymptomatic post-menopausal women with a thickened endometrium (>5 mm). Dilatation and curettage were performed for all cases, and the specimen was sent for histopathological examination. According to the data distribution, all the continuous variables were stated as mean \pm standard deviation/median (inter-quartile range), categorical variables were expressed in frequency, and percentage will be compared using the Chi-square test/Fisher exact test. **Results:** In our study, most of the women were multipara. The age of post-menopausal women ranged from 46 to 68 years, and the mean duration of menopause was 8.10. The most common histological findings were benign in 72.22% of the cases. We identified pre-malignant and malignant lesions of the endometrium in 18.05% and 9.72% of the cases, respectively. To predict the condition of the lesion, we noticed no definite cut-off value of endometrial thickness to indicate the state of the lesion. We observed that none of the patient's characteristics showed a significant difference with a thickened endometrium. **Conclusion:** We observed an increased frequency of endometrial pathology irrespective of the presence or absence of risk factors. The result of this study is justified enough for the need of further evaluation of a thickened endometrium in asymptomatic post-menopausal women.

Keywords: Asymptomatic endometrial thickening, dilatation and curettage, endometrial carcinoma, post-menopausal women, trans-vaginal ultrasonography

Introduction

Endometrial carcinoma is one of the common malignancies contributing about 1.9% of the total cancer burden in women.^[1] Endometrial malignancy is usually suspected when a post-menopausal woman presents with bleeding per vagina or is found to have an asymptomatic thickened endometrium (>4 mm)

upon trans-vaginal ultrasonography (TVS).^[2] Other concerned ultrasound findings are excessive vascularity and asymmetrical endometrial lining with the fluid collection.^[3] The incidence of endometrial thickening in post-menopausal women ranges from 3% to 17%.^[4,5] A few studies stated a malignancy rate of 0% to 3% among asymptomatic post-menopausal women with a thickened endometrium.^[6,7]

Address for correspondence: Dr. Bhabani Pegu,

Department of Obstetrics and Gynecology, JIPMER, Puducherry, India.

E-mail: bpeguamc@gmail.com

Received: 02-12-2021

Revised: 05-02-2022

Accepted: 07-02-2022

Published: 30-06-2022

Access this article online

Quick Response Code:



Website:
www.jfmpc.com

DOI:
10.4103/jfmpc.jfmpc_2347_21

British Gynaecological Cancer Society (BGCS) Uterine Cancer Guidelines suggested screening asymptomatic women with trans-vaginal ultrasound scanning (Trans-Vaginal Sonography (TVS)), or endometrial sampling does not improve outcomes

This is an open access journal, and articles are distributed under the terms of the Creative Commons Attribution-NonCommercial-ShareAlike 4.0 License, which allows others to remix, tweak, and build upon the work non-commercially, as long as appropriate credit is given and the new creations are licensed under the identical terms.

For reprints contact: WKHLRPMedknow_reprints@wolterskluwer.com

How to cite this article: Pegu B, Saranya TS, Murugesan R. Endometrial carcinoma in asymptomatic postmenopausal women with a thickened endometrium and its influencing factors - A cross-sectional study. J Family Med Prim Care 2022;11:2956-60.

from endometrial cancer.^[8] Although routine evaluations are not recommended, it is a matter of concern for clinicians.^[6,9] Various risk factors for endometrial cancer are obesity, diabetes mellitus, hypertension, women with a history of polycystic ovarian syndrome, late menopause, etc., In 2010, Goldstein suggested individualizing the cases for evaluation depending upon the clinical profile.^[10] This statement is challenging for the population living in low- and middle-income countries such as India, where poor access to health care and the lack of knowledge and awareness of patients lead to late presentation. Hence, this study was undertaken to investigate the frequency of endometrial malignancies and identify the associated factors influencing the thickened endometrium in asymptomatic post-menopausal women. Such information would be helpful to guide the physician to take the decision regarding the further management of the thickened endometrium in asymptomatic post-menopausal women.

Methods

The study was carried out in the Obstetrics and Gynaecology Department in a tertiary center. The institutional ethical committee approved the study. If women experience amenorrhea naturally for 12 consecutive months, it is called menopause. After counseling, informed consent was taken from all the participants before enrollment. We conducted a cross-sectional study among asymptomatic post-menopausal women incidentally diagnosed with a thickened endometrium (ET >5 mm) by trans-vaginal ultrasound from February 2016 to January 2018. We excluded all symptomatic post-menopausal women with vaginal bleeding, patients with an unknown status of menopause, women on hormone replacement therapy, patients with a history of endometrial hyperplasia or endometrial cancer, and tamoxifen users. The purpose of performing ultrasound in post-menopausal women with no bleeding per vagina might be to investigate abdominal pain or masses or to delineate the adnexa when the pelvic examination is inadequate.

Those who fulfilled the inclusion criteria were included in this study. Thorough history on age of the women, age at menopause, duration of menopause, body mass index (BMI), the presence of co-morbidities such as hypertension and diabetes, and drug intake was obtained. Where endometrial polyp is clearly made out on ultrasonography, those cases were excluded from the study. In addition to history, each patient's endometrial thickness (ET) and any pathological findings in ultrasound were documented. On the out-patient department (OPD) visit, all patients underwent routine gynecological examination.

According to a hypothetical cohort decision analysis study in asymptomatic post-menopausal women, it is observed that an ET of 11 mm poses similar separations as <4 mm.^[11] They reported 6.7% risk of endometrial cancer for endometrium >11 mm and 0.002% risk for endometrium <11 mm. Depending upon this finding, participants were divided into two groups: group A with ET <11 mm and group B with ET >11 mm.

It is well known that dilatation and curettage is a blind procedure that limits the power of outlining intra-uterine pathologies. Because of logistics and technical issues, endometrial sampling was performed by dilatation and curettage (D&C) under local anesthesia and sedation as a day-care procedure. The samples were sent to the pathology department for histopathological examination. All the patients were asked to review after 2 weeks with Histo-Pathological Examination (HPE) reports. We collected necessary data in a pre-designed proforma. Women with endometrial hyperplasia were sub-categorized according to the revised 2014 World Health Organization (WHO) classification.^[12]

Statistics

Data were entered in Microsoft Excel version 13 periodically. Categorical variables were expressed as frequencies and percentages. Mean and standard deviation (SD) or median and inter-quartile range (IQR) were used for continuous variables. The Chi-square test was applied as a test of significance for comparison between the groups, and a *P* value of < 0.05 was considered for a statistically significant difference.

Results

The thickened endometrium (>5 mm) was observed in 93 asymptomatic post-menopausal women during the study period. Nine patients were not keen on endometrial sampling but assured for regular follow-up, and in a few, the sample was tried but inaccessible. After curettage, two of them did not review with histopathology reports, four patients declined to participate in the study, and a few histopathology reports came as inadequate tissues for examination. Therefore, a total of 21 eligible women were excluded from the study. [Figure 1].

A total of 72 asymptomatic post-menopausal women were included for analysis. Table 1 shows the essential characteristics of post-menopausal women. The total number of multiparous women was 58, that of primiparous women was 11, and that of nulliparous women was 7. It was observed that the age of post-menopausal women ranged from 46 to 68 years, and

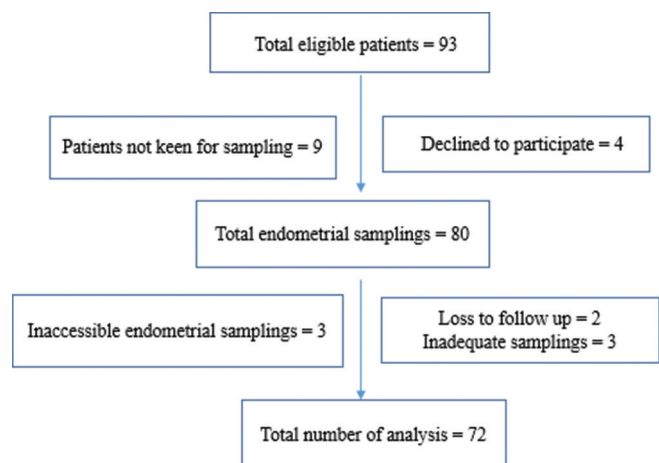


Figure 1: Flow chart of participants in the study

the range of ET was 5 mm to 21 mm. On histopathological examination, 72.22% of the cases were found to have benign lesions, followed by endometrial hyperplasia in 18.05% and endometrial carcinoma in 9.72% of cases. Details on histopathological findings of the endometrial biopsy are listed in Table 2. In this study, most of the endometrial lesions were benign, irrespective of endometrial thickness. Pre-malignant and malignant lesions were noted in both groups of asymptomatic post-menopausal women. There was no statistically significant difference between the two groups with endometrium thickness and malignant lesions. Table 3 shows various histological findings according to endometrial thickness.

Tables 4 and 5 show the association of histopathological reports of the endometrium with the patient characteristics and clinical profile. None of the patient's characteristics and clinical profile showed a statistically significant difference. Although diabetes,

hypertension, and obesity are the three component risks for endometrial cancer, these risk factors were not statistically significant in our study.

Discussion

We observed most of the histopathology reports of endometrial biopsy in asymptomatic post-menopausal women with a thickened endometrium were benign. Pre-malignant and malignant pathology had been identified in 18.05% and 9.72% of the cases, respectively. A systematic review and meta-analysis on asymptomatic post-menopausal women reported that the frequency of endometrial malignancy and atypical hyperplasia was 0.62 and 0.59%, respectively, with the mean endometrial thickness of 2.9 mm. The author also observed that the positive and negative predictive values of TVS varied between 0 and 0.2 and between 0.98 and 1.0, respectively, for the outcomes (endometrial carcinoma, atypical endometrial hyperplasia, and both combined) for all reported endometrial thickness cut-offs. As the reported prevalence was low, the effectiveness of TVS in the evaluation of the asymptomatic population is limited compared to the symptomatic patient, where the risk of the endometrial pre-malignant or malignant lesion was between 5 and 20%.^[13]

A previous study detected endometrial cancer only in 0.7% (one) case when hysteroscopy-guided endometrial biopsies were performed in 148 asymptomatic post-menopausal women having a thickened endometrium.^[2] A study from Egypt on a similar population found endometrial hyperplasia with atypia in 6.8% and endometrial carcinoma in 4.1%.^[14] The prevalence of endometrial pathology is lower than our findings. The findings may be because of different ethnicity with different patient profiles.

In the present study, the relationship between abnormal endometrial lesions and the level of the thickened endometrium was analyzed. In group A (ET <11 mm), pre-malignant and malignant lesions were found in 6.94% and 4.16% of the cases, and in group B (ET >11 mm), they were found in 11.11% and 5.55% of the patients, respectively. In the histopathological report, a retrospective study analyzed 123 asymptomatic post-menopausal women with an endometrial thickness of ≥10 mm, 17% of the women had hyperplasia, and 13% had endometrial cancer.^[15] A previous study was conducted in 792 cases and found that 98.2% of the lesions were benign in those with ET <11 mm and 87.5% were with ET ≥11 mm. The malignancy rates in these two groups were 1.2% and 7.8%, respectively.^[16]

A comparison study was conducted between hypertensive women with or without medication to determine the effect of anti-hypertensive drugs on endometrial thickness. The author noticed an increase in the endometrium in women on anti-hypertensive medications compared to those with no medicines.^[17] This occurrence was primarily recognized in beta-blocker groups of anti-hypertensive drugs because of its

Table 1: Demographics and patient characteristics

Characteristics	Range	Mean (SD)
Age (years)	46-68	55.67 (5.71)
Parity	0-5	2.58 (1.22)
Age at menopause (years)	42-53	46.74 (2.88)
Duration of menopause	1-23	8.10 (4.88)
BMI (kg/m ²)	22-38	26.79 (3.45)
Endometrial thickness (mm)	5-21	10.49 (4.22)

Table 2: Histopathological findings of the thickened endometrium in post-menopausal women

Histopathology of the endometrium	n (%)
Benign lesions	52 (72.22)
Normal endometrium	19 (26.4)
Polyp	15 (20.8)
Disordered proliferative	11 (15.3)
Proliferative endometrium	7 (9.7)
Endometrial hyperplasia	13 (18.05)
Non-atypical or benign hyperplasia	10 (13.88)
Atypical hyperplasia or EIN*/well differentiated carcinoma	3 (4.2)
Endometrial carcinoma	7 (9.72)
Squamous cell carcinoma	5 (7.02)
Adenocarcinoma	2 (2.70)

*Endometrial intra-epithelial neoplasia

Table 3: Histopathological findings in relation to endometrial thickness

Histopathological report	ET <11 mm n=52 (%)	ET >11 mm n=20 (%)	Total (%)
Normal endometrium	15 (20.83)	4 (5.55)	19 (26.38)
Polyp	13 (18.05)	2 (2.77)	15 (20.83)
Disordered proliferative	10 (13.88)	1 (1.38)	11 (15.27)
Proliferative endometrium	6 (8.33)	1 (1.38)	7 (9.7)
Simple hyperplasia	3 (4.16)	4 (5.55)	7 (9.7)
Complex hyperplasia	1 (1.38)	2 (2.77)	3 (4.16)
Atypical hyperplasia	1 (1.38)	2 (2.77)	3 (4.16)
Endometrial carcinoma	3 (4.16)	4 (5.55)	7 (7.6)

trophic effect on the uterine endometrium.^[18] A few other studies reported no association between hypertension and endometrial thickness.^[19,20] In our study, too, no correlation was found between hypertension and the thickened endometrium.

High BMI and diabetes mellitus can affect endometrial thickness through several mechanisms. Increased peripheral conversion of androstenedione by aromatization is the cause for the thickened endometrium in obese post-menopausal women. The insulin-like growth factor (IGF-1) and its binding protein (IGF binding protein-1) are the two factors that are responsible for stimulating endometrial cell growth.^[21] Endometrial hyperplasia is seen in obese women because of elevated levels of IGF found in their bodies. Another author also observed that an increase in BMI was associated with an increase in endometrial thickness.^[18]

Lynch syndrome is one of the reasons for a carcinoma endometrium. Therefore, evaluating the asymptomatic thickened endometrium in post-menopausal women can give an opportunity to identify Lynch syndrome.^[22,23] It is suitable to both patients and clinicians if gynecologists can start Lynch syndrome testing.^[24] The universal testing of endometrial cancer is cost-effective and is also recommended by the National Institute of Health and Care Excellence.^[25,26]

Persistent exposure to unopposed estrogen is one of the reasons to have a thickened endometrium.^[4] In this study, we observed that 29.31% of multiparous women had endometrial pathology compared to nulliparous women, which was observed in 14.28% of the cases. The result mentioned above may be because of a small number of study participants. A previous study observed that more pregnancies have an inverse association with endometrial pathology and protect against endometrial disease.^[22] Mechanical shedding of malignant potential precursor cells after every delivery prevents the endometrium from being thickened, and the effect of progesterone has the property of limiting the proliferation of the endometrium.^[27,28]

There are several limitations observed in our study. First, the small number of participants limited our ability to analyze the various risk factors and their effects on endometrial pathologies. The findings necessitate further prospective research with a larger population to determine a new cut-off value for further evaluation. Second, hysteroscopy is considered a gold standard procedure for identifying endometrial disorders. It benefits from gaining a panoramic vision of the endometrial cavity, and a biopsy can be done from the suspicious-looking area. Still, dilatation and curettage were performed for endometrial sampling because of logistic issues, a blind procedure.

Conclusions

In our analysis, no specific factors can influence the thickened endometrium in asymptomatic post-menopausal women, and pre-malignant and malignant lesions can often be identified in them. These lesions were noted irrespective of the extent of endometrial thickness, so no exact cut-off value was established to predict endometrial pathology. Pre-malignant and malignant lesions can often be identified in the thickened endometrium in asymptomatic post-menopausal women. We emphasize

Table 4: Histopathological reports in relation to patient characteristics

Variables	Benign		EIN		Carcinoma		P
	Mean	SD	Mean	SD	Mean	SD	
Age (years)	56.06	5.75	53.85	5.96	56.14	4.98	0.453
Age at menopause	46.83	2.82	46.23	3.06	47.00	3.32	0.779
Duration of menopause	8.46	5.18	6.69	3.88	8.00	4.28	0.510
BMI	26.96	3.62	26.23	3.27	26.57	2.57	0.784
Endometrial thickness*	9.5	6	9.23	4	10	8	0.667

Table 5: Histopathological reports in relation to the patient clinical profile

Variables	Benign n=52 (%)	EIN n=13 (%)	Carcinoma n=7 (%)	P
Past menstrual cycle				
Regular	38 (73.1)	10 (76.9)	4 (57.1)	0.690
Irregular	14 (26.9)	3 (23.1)	3 (42.9)	
Diabetic				
Yes	19 (36.5)	4 (30.8)	3 (42.9)	0.856
No	33 (63.5)	9 (69.2)	4 (57.1)	
Hypertension				
Yes	23 (44.2)	6 (46.2)	2 (28.6)	0.856
No	29 (55.8)	7 (53.8)	5 (71.4)	
History of Poly Cystic Ovarian Disease (PCOD)				
Yes	10 (19.2)	2 (15.4)	1 (14.3)	1.000
No	42 (80.8)	11 (84.6)	6 (85.7)	
History of oral contraceptive pill intake				
Yes	19 (36.5)	5 (38.5)	3 (42.9)	1.000
No	33 (63.5)	8 (61.5)	4 (57.1)	
History of early menarche				
Yes	10 (19.2)	2 (15.4)	1 (14.3)	1.000
No	42 (80.8)	11 (84.6)	6 (85.7)	

*Median, IQR

the importance of pathological evaluation of the thickened endometrium, irrespective of the presence or absence of symptoms in post-menopausal women.

Financial support and sponsorship

Nil.

Conflicts of interest

There are no conflicts of interest.

References

- Kong TW, Lee KM, Cheong JY, Kim WY, Chang SJ, Yoo SC, *et al.* Comparison of laparoscopic versus conventional open surgical staging procedure for endometrial cancer. *J Gynecol Oncol* 2010;21:106-11.
- Ozelci R, Dilbaz B, Akpınar F, Kınay T, Baser E, Aldemir O, *et al.* The significance of sonographically thickened endometrium in asymptomatic postmenopausal women. *Obstet Gynecol Sci* 2019;62:273-9.
- Lev-Sagie A, Hamani Y, Imbar T, Hurwitz A, Lavy Y. The significance of intrauterine lesions detected by ultrasound in asymptomatic postmenopausal patients. *BJOG* 2005;112:379-81.
- Koss LG, Schreiber K, Oberlander SG, Moukhtar M, Levine HS, Moussouris HF. Screening of asymptomatic women for endometrial cancer. *CA Cancer J Clin* 1981;31:300-17.
- Vuento MH, Pirhonen JP, Mäkinen JJ, Tyrkkö JE, Laippala PJ, Grönroos M, *et al.* Screening for endometrial cancer in asymptomatic postmenopausal women with conventional and colour Doppler sonography. *Br J Obstet Gynaecol* 1999;106:14-20.
- Opolskiene G, Sladkevicius P, Valentin L. Ultrasound assessment of endometrial morphology and vascularity to predict endometrial malignancy in women with postmenopausal bleeding and sonographic endometrial thickness ≥ 4.5 mm. *Ultrasound Obstet Gynecol* 2007;30:332-40.
- Newton C, Nordin A, Rolland P, Ind T, Larsen-Disney P, Martin-Hirsch P, *et al.* British gynaecological cancer society recommendations and guidance on Patient-initiated follow-up (PIFU). *Int J Gynecol Cancer* 2020;30:695-700.
- Worley MJ Jr, Dean KL, Lin SN, Caputo TA, Post RC. The significance of a thickened endometrial echo in asymptomatic postmenopausal patients. *Maturitas* 2011;68:179-81.
- ACOG committee opinion no. 734: The role of transvaginal ultrasonography in evaluating the endometrium of women with postmenopausal bleeding. *Obstet Gynecol* 2018;131:e124-9.
- Goldstein SR. Modern evaluation of the endometrium. *Obstet Gynecol* 2010;116:168-76.
- Smith-Bindman R, Weiss E, Feldstein V. How thick is too thick? When endometrial thickness should prompt biopsy in postmenopausal women without vaginal bleeding. *Ultrasound Obstet Gynecol* 2004;24:558-65.
- Sobczuk K, Sobczuk A. New classification system of endometrial hyperplasia WHO 2014 and its clinical implications. *Prz Menopauzalny* 2017;16:107-11.
- Breijer MC, Peeters JA, Opmeer BC, Clark TJ, Verheijen RH, Mol BW, *et al.* Capacity of endometrial thickness measurement to diagnose endometrial carcinoma in asymptomatic postmenopausal women: A systematic review and meta-analysis. *Ultrasound Obstet Gynecol* 2012;40:621-9.
- Allam NE, Mohamed TM. Postmenopausal asymptomatic endometrial thickening: Patient characteristics and pathology. *J Women's Health Reprod Med* 2018;2:5.
- Gerber B, Krause A, Müller H, Reimer T, Külz T, Kundt G, *et al.* Ultrasonographic detection of asymptomatic endometrial cancer in postmenopausal patients offers no prognostic advantage over symptomatic disease discovered by uterine bleeding. *Eur J Cancer* 2001;37:64-71.
- Jiang T, Yuan Q, Zhou Q, Zhu Y, Lv S, Cao Y, *et al.* Do endometrial lesions require removal? A retrospective study. *BMC Womens Health* 2019;19:61.
- Bornstein J, Auslender R, Goldstein S, Kohan R, Stolar Z, Abramovici H. Increased endometrial thickness in women with hypertension. *Am J Obstet Gynecol* 2000;183:583-7.
- Okman-Kilic T, Kucuk M. The effects of antihypertensive agents on endometrial thickness in asymptomatic, hypertensive, postmenopausal women. *Menopause* 2003;10:362-5.
- Hebbar S, Chaya V, Rai L, Ramachandran A. Factors influencing endometrial thickness in postmenopausal women. *Ann Med Health Sci Res* 2014;4:608-14.
- Serin IS, Özçelik B, Basbug M, Ozsahin O, Yilmazsoy A, Erez R. Effects of hypertension and obesity on endometrial thickness. *Eur J Obstet Gynecol Reprod Biol* 2003;109:72-5.
- Gürbüz B, Yalti S, Yildirim G. Endometrial thickness and uterine size in postmenopausal women. *Int J Gynaecol Obstet* 2004;84:268-70.
- Ryan NAJ, McMahon R, Tobi S, Snowsill T, Esquibel S, Wallace AJ, *et al.* The Proportion of endometrial tumours associated with lynch syndrome (PETALS): A prospective cross-sectional study. *PLoS Med* 2020;17:e1003263.
- Ryan NA, Donnelly L, Stocking K, Evans DG, Crosbie EJ. Feasibility of gynaecologist led lynch syndrome testing in women with endometrial cancer. *J Clin Med* 2020;9:1842.
- Snowsill TM, Ryan NAJ, Crosbie EJ. Cost-effectiveness of the manchester approach to identifying lynch syndrome in women with endometrial cancer. *J Clin Med* 2020;9:1664.
- Stinton C, Jordan M, Fraser H, Auguste P, Court R, Al-Khudairy L, *et al.* Testing strategies for Lynch syndrome in people with endometrial cancer: systematic reviews and economic evaluation. *Health Technol Assess.* 2021;25:1-216.
- Gull B, Karlsson B, Milsom I, Granberg S. Factors associated with endometrial thickness and uterine size in a random sample of postmenopausal women. *Am J Obstet Gynecol* 2001;185:386-91.
- Albrektsen G, Heuch I, Tretli S, Kvåle G. Is the risk of cancer of the corpus uteri reduced by a recent pregnancy? A prospective study of 765,756 Norwegian women. *Int J Cancer* 1995;61:485-90.
- Lambe M, Wu J, Weiderpass E, Hsieh CC. Childbearing at older age and endometrial cancer risk (Sweden). *Cancer Causes Control* 1999;10:43-9.