



## Unusual complications caused by lipoma of the tongue

Serena Cocca<sup>1</sup>, Massimo Viviano<sup>2</sup>, Stefano Parrini<sup>2</sup>

<sup>1</sup>Department of Medicine, Surgery and Neurosciences, ENT Clinic, <sup>2</sup>Department of Dentistry, University of Siena, Siena, Italy

**Abstract** (J Korean Assoc Oral Maxillofac Surg 2017;43 Suppl 1:S6-8)

Lipoma is the most common, benign, soft tissue, mesenchymal tumour and is composed of mature adipose tissue. It is infrequent in the oral cavity (approximately 0.3% of all tongue neoplasias). We describe the case of a 68-year-old man with a swelling at the tongue edge and tongue dysesthesia. Medical history, clinical assessment, radiographic images, and cytological analysis enabled specialists to classify this neoplasia as a lipoma. The patient recovered fully after surgical excision of the affected area, and the neuralgic symptoms regressed. Surgical excision is an elective treatment; however, accurate differential diagnosis, histological examination, and follow-up are required.

**Key words:** Tongue, Lipoma, Oral cavity, Macroglossia, Hypoesthesia

[paper submitted 2017. 3. 15 / revised 2017. 4. 30 / accepted 2017. 5. 26]

### I. Introduction

Lipoma, a soft tissue lesion, is a benign tumour composed of mature adipose tissue. It is a common mesenchymal neoplasm that usually develops on the torso or proximal segments of the limbs<sup>1</sup>. Oral lipoma is rare, having an incidence of 1% to 5% among benign oral tumours<sup>2</sup> and 0.3% among tongue neoplasias<sup>3</sup>. The most common sites are the buccal mucosa, lips, tongue, palate, vestibule, floor of the mouth, and retromolar area<sup>4</sup>. In 2004, Furlong et al.<sup>5</sup> classified oral peripheral mesenchymal tumours as:

- Lipomas
- Myomas (rhabdomyomas and leiomyoma)
- Peripheral nerve tumours (neurofibroma, plexiform type of neurofibroma, schwannoma, traumatic neuroma)

Clinically, they are all well-circumscribed, painless, slow-growing tumours. Their aetiology and pathogenesis are unclear, although factors such as mechanical, endocrine, or

inflammatory issues<sup>2,6-8</sup>; hypercholesterolemia; obesity<sup>9,10</sup>; radiation<sup>9</sup>; and chromosomal abnormalities<sup>11,12</sup> have been considered. Contributing risk factors include trauma, mucosal infections, and chronic or hormonal irritation. Lipoma usually affects male and female adults equally, and the most frequent age group is 40 to 50 years<sup>13</sup>. The lesions are slow-growing and often without symptoms; they are typically yellow in colour with a soft doughy consistency. A continuous increase in volume can interfere with phonation and mastication<sup>14</sup>. Lipomas usually occur as solitary lesions; multiple lesions can be associated with Gardner or Bourneville syndromes<sup>13</sup>.

### II. Case Report

A 68-year-old Caucasian male presented with macroglossia that had developed from a slight swelling on the right lingual border, noted 3 years earlier. The neoplasm, involving the lateral edge of the ventral surface of the tongue, had a maximum diameter of 20 mm, a sinuous shape, and soft consistency. It was movable on the superficial and deep planes and covered by normal mucosa (Fig. 1) It caused difficulty in swallowing and changes in sensitivity associated with occasional numbness on the tip of the tongue. His medical history did not reveal any systemic diseases. Palpation of the cervical lymph nodes and neck did not reveal any abnormality. To determine the places in which the patient experienced changes in sensitivity, the tongue was explored with a sharp pointed instrument. The patient reported hypesthesia and dysesthesia

#### Serena Cocca

Department of ENT, General Hospital of Siena, University of Siena, Viale Bracci, 14, Siena 53100, Italy

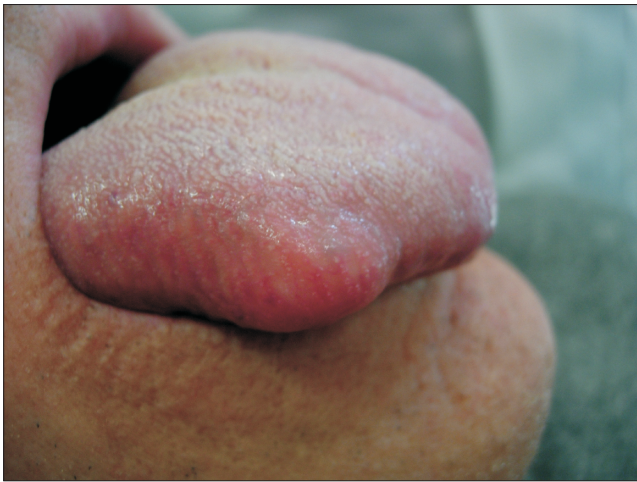TEL: +39-3201525334 FAX: +39-0577585470

E-mail: mailarticoli@libero.it

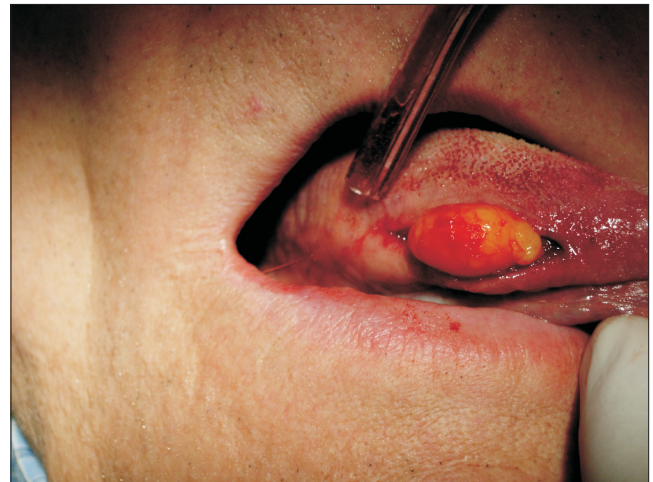ORCID: <http://orcid.org/0000-0003-3485-9967>

© This is an open-access article distributed under the terms of the Creative Commons Attribution Non-Commercial License (<http://creativecommons.org/licenses/by-nc/4.0/>), which permits unrestricted non-commercial use, distribution, and reproduction in any medium, provided the original work is properly cited.

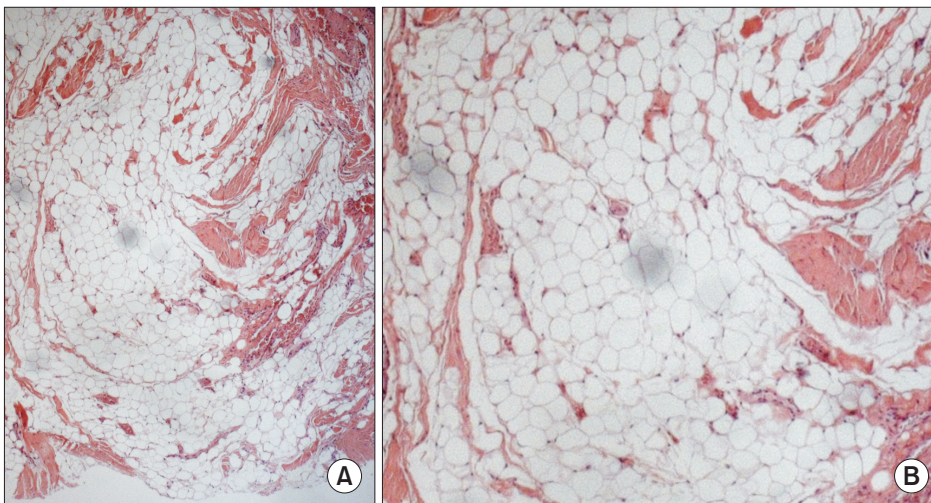
Copyright © 2017 The Korean Association of Oral and Maxillofacial Surgeons. All rights reserved.



**Fig. 1.** Nodular lesion on the right ventral surface of the tongue. The lesion was asymptomatic, well defined, smooth with soft consistency and with normal lingual mucosal surface.  
*Serena Cocca et al: Unusual complications caused by lipoma of the tongue. J Korean Assoc Oral Maxillofac Surg 2017*



**Fig. 2.** Exposing the mass. An excisional biopsy and enucleation of the lesion was performed.  
*Serena Cocca et al: Unusual complications caused by lipoma of the tongue. J Korean Assoc Oral Maxillofac Surg 2017*



**Fig. 3.** Histological features. Microscopic examination revealed mature adipocytes septimented by thin fibrous connective tissue, clusters of unvacuolated fat cells forming lace-like sheets and bland peripheral nuclei (H&E staining, A:  $\times 50$ , B:  $\times 100$ ).  
*Serena Cocca et al: Unusual complications caused by lipoma of the tongue. J Korean Assoc Oral Maxillofac Surg 2017*

in the anterior third of the tongue. Oral magnetic resonance imaging with contrast medium confirmed the suspicion of lipoma. Fine-needle aspiration biopsy was performed, and the histopathology report indicated a predominance of mature adipose tissue with associated spindle cells embedded in myxoid stroma. No pleomorphic lipoblasts or areas of mitosis were observed.

The neoplasm was removed by transoral surgery.(Fig. 2) Local anaesthesia with articaine 1:100,000 (3.8 mL) was administered, a strip on the lingual border was marked, and the neoplasm was enucleated following the cleavage plane. The edge of the tongue was then sutured with silk size 3-0.

Macroscopic examination of the surgical material showed a capsulated mass, soft and yellowish in colour. It was placed

in 10% buffered formalin and sent to the pathologist. Histological examination showed a well-circumscribed mass composed of lobules of mature adipose tissue and nodules of entrapped, non-neoplastic acini and ducts separated by thin, fibrous septa, compatible with lipoma.(Fig. 3)

The patient was given instructions for post-surgical care and pharmacological treatment. Antibiotics (amoxicillin and clavulanic acid twice daily for 5 consecutive days) and a corticosteroid (16 mg methylprednisolone for 3 days, then 8 mg for 3 days) were prescribed as well as chlorhexidine 0.2% anti-discoloration system mouthwash (three times a day after regular oral hygiene). Seven days after enucleation of the lesion, the sutures were removed. The surgical wound healed well, but dysesthesia on the top surface of the tongue persist-

ed. The patient returned for weekly follow-ups and showed full neurological recovery 3 months after the operation.

### III. Discussion

In 1848, Roux described lipoma for the first time as “yellow epulis”<sup>1</sup>. Lipoma is a common tumour of soft tissues and consists of mature fat cells arranged in lobules separated by layers of fibrous connective tissue. Although morphologically indistinguishable from normal fat, lipomas differ because their lipid is not available for metabolism, and they are usually surrounded by a thin fibrous capsule<sup>3</sup>. Lipoma is rare in the oral mucosa; 50% of oral lipomas occur in the buccal mucosa or on the tongue; less common areas are the floor of the mouth and lips<sup>2</sup>.

Lipomas in the oral mucosa might not be true tumours, but rather herniations of the buccal fat pad through the buccinator muscle. Such cases could occur as a result of local trauma in young children or surgical removal of third molars in older patients<sup>1</sup>. They manifest as soft and compressible masses of doughy consistency that are well defined clinically, radiologically (computed tomography), ultrasonographically, and by magnetic resonance imaging<sup>15</sup>. Other lesions that should be considered in differential diagnosis include oral lymphoepithelial, epidermoid and oral dermoid cysts, and connective tissue lesions such as granular cell tumours, neurofibromas, traumatic fibromas, and salivary gland lesions<sup>2</sup>. In the present case, a diagnosis of lipoma was confirmed by fine-needle aspiration biopsy. With regard to changes in sensitivity, the patient’s medical history was negative for other surgery. The discomfort suffered was related to nerve damage caused by compression. Compression of the nerve trunk was found without damage to the axon, and this led to compression anaesthesia. Compression of the nerve axon led to dysesthesia that resolved after removal of the neoplasm. The slow growth of the lipoma probably initially deviated the lingual nerve from its regular path, and the subsequent compression caused dysesthesia. Lack of sensitivity in the tongue impedes phonation, mastication, and swallowing. It is worth remembering that biting the tongue can cause severe laceration and mutilation. Damage to the lingual nerve, as documented in the international literature, can occur during wisdom tooth extraction or other oral surgery. In the present case, the lesion was attributed to neuropraxia with no damage to the nerve trunk, as described by Seddon<sup>16</sup>. Complete surgical excision of the tumour can maintain adjacent structures but must include a rim of healthy tissue to prevent local recurrence<sup>17</sup>.

### Conflict of Interest

No potential conflict of interest relevant to this article was reported.

### ORCID

Serena Cocca, <http://orcid.org/0000-0003-3485-9967>

Massimo Viviano, <http://orcid.org/0000-0002-9405-731X>

Stefano Parrini, <http://orcid.org/0000-0003-3062-2401>

### References

1. Venkateswarlu M, Geetha P, Srikanth M. A rare case of intraoral lipoma in a six year-old child: a case report. *Int J Oral Sci* 2011;3:43-6.
2. Hoseini AT, Razavi SM, Khabazian A. Lipoma in oral mucosa: two case reports. *Dent Res J (Isfahan)* 2010;7:41-3.
3. Iaconetta G, Friscia M, Cecere A, Romano A, Orabona GD, Califano L. Rare fibrolipoma of the tongue: a case report. *J Med Case Rep* 2015;9:177.
4. Studart-Soares EC, Costa FW, Sousa FB, Alves AP, Osterne RL. Oral lipomas in a Brazilian population: a 10-year study and analysis of 450 cases reported in the literature. *Med Oral Patol Oral Cir Bucal* 2010;15:e691-6.
5. Furlong MA, Fanburg-Smith JC, Childers EL. Lipoma of the oral and maxillofacial region: Site and subclassification of 125 cases. *Oral Surg Oral Med Oral Pathol Oral Radiol Endod* 2004;98:441-50.
6. Egido-Moreno S, Lozano-Porras AB, Mishra S, Allegue-Allegue M, Mari-Roig A, López-López J. Intraoral lipomas: review of literature and report of two clinical cases. *J Clin Exp Dent* 2016;8:e597-603.
7. de Moraes M, de Matos FR, de Carvalho CP, de Medeiros AM, de Souza LB. Sialolipoma in minor salivary gland: case report and review of the literature. *Head Neck Pathol* 2010;4:249-52.
8. Santos LC, Wanderley Rocha SM, Carvalho CN, Oliveira EP, Neves DF. Intraoral lipoma: an atypical case. *Braz J Otorhinolaryngol* 2011;77:676.
9. Brkić A, Ozçamur C, Gürkan-Köseoğlu B, Olgac V. Angiofibrolipoma of the buccal mucosa: a case report. *J Oral Sci* 2010;52:173-6.
10. Motagi A, Aminzadeh A, Razavi SM. Large oral lipoma: case report and literature review in Iran. *Dent Res J (Isfahan)* 2012;9:350-2.
11. Kumaraswamy S, Madan N, Keerthi R, Shakti S. Lipomas of oral cavity: case reports with review of literature. *J Maxillofac Oral Surg* 2009;8:394-7.
12. Srinivasan K, Hariharan N, Parthiban P, Shyamala R. Lipoma of tongue: a rare site for a rare site for a common tumour. *Indian J Otolaryngol Head Neck Surg* 2007;59:83-4.
13. Del Castillo Pardo de Vera JL, Cebrián Carretero JL, Gómez García E. Chronic lingual ulceration caused by lipoma of the oral cavity. Case report. *Med Oral* 2004;9:166-7, 163-6.
14. Barker GR, Sloan P. Intraosseous lipomas: clinical features of a mandibular case with possible aetiology. *Br J Oral Maxillofac Surg* 1986;24:459-63.
15. Ahuja AT, King AD, Kew J, King W, Metreweli C. Head and neck lipomas: sonographic appearance. *AJNR Am J Neuroradiol* 1998;19:505-8.
16. Seddon HJ. Three types of nerve injury. *Brain* 1943;66:237-88.
17. Moore PL, Goede A, Phillips DE, Carr R. Atypical lipoma of the tongue. *J Laryngol Otol* 2001;115:859-61.