

Trajectory of Lumbar Translaminar Facet Screw Under Navigation: A Cadaveric Study

Weerasak Singhatanadgige, MD¹, Kittisak Songthong, MD¹, Phattareeya Pholprajug, MD¹, Wicharn Yingsakmongkol, MD¹, Vit Kotheeranurak, MD², and Worawat Limthongkul, MD¹ 

Global Spine Journal
2022, Vol. 12(5) 765–771
© The Author(s) 2020
Article reuse guidelines:
sagepub.com/journals-permissions
DOI: 10.1177/2192568220962444
journals.sagepub.com/home/gsj



Abstract

Study Design: Anatomic cadaver study.

Objective: Translaminar facet screw fixation supplements unilateral pedicle screw-rod fixation in minimally invasive transforaminal lumbar interbody fusion (TLIF). Various screw diameters, lengths, trajectories, and insertion points are used; however, they do not represent true screw trajectory. We aimed to evaluate lumbar laminar anatomy and suggest a safe and effective insertion point and trajectory during lumbar-translaminar facet screw fixation in an anatomic cadaver study.

Methods: O-arm navigation simulating the true translaminar facet screw trajectory was used to evaluate L1-S1 in cadaveric spines. The inner and outer diameters, length, and trajectory of the screw pathway were measured along the trajectory from the spinous process base through the contralateral lamina, crossing the facet joint to the transverse process base using 2 starting points: cephalad one-third (1/3SL) and one-half (1/2SL) of the spinolaminar junction.

Results: Using the 1/2SL starting point, the outer and inner lamina diameters did not differ significantly from L1-L5 (7.47 ± 1.38 to 6.7 ± 1.84 mm and 4.73 ± 1.04 to 3.86 ± 1.46 mm, respectively). Screw length (36.16 ± 4.02 to 49.29 ± 10.07 mm) and lateral angle increased ($50.28^\circ \pm 8.78^\circ$ to $60.77^\circ \pm 8.88^\circ$), but caudal angle decreased ($16.19^\circ \pm 9.01^\circ$ to $1.13^\circ \pm 11.31^\circ$). Lamina diameter and screw length did not differ with different starting points. L2-L3 caudal angles were lower in the 1/2SL starting point.

Conclusion: A 36- to 50-mm translaminar facet screw—with 5.0-mm diameter for L1-L2 and 4.5-mm diameter for L3-L5—can be inserted at the middle of the spinolamina, especially during minimally invasive TLIF, with a 50° to 60° lateral angle relative to the spinous process, and a caudal angle of 16° to 1° relative to the spinolamina from L1-L5.

Keywords

translaminar facet screw, O-arm navigation, trajectory, insertion point, screw length, screw diameter, pedicle screws, zygapophyseal joint, lumbosacral region

Introduction

Facet screw fixation was first described by King in 1948 as the placement of a short screw directly across the facet joint.¹ In 1959, Boucher² used a modified method called “transfacetopedicular screw fixation,” which used a longer screw directed toward the pedicle. Benini and Magerl³ proposed a method called “translaminar facet screw fixation” (TLFS), which used a much longer screw that started from the base of the spinous process, threaded through the entire lamina, across the facet

¹ Department of Orthopaedics, Faculty of Medicine, Chulalongkorn University and King Chulalongkorn Memorial Hospital, Bangkok, Thailand

² Queen Savang Vadhana Memorial Hospital, Chonburi, Thailand

Corresponding Author:

Worawat Limthongkul, Department of Orthopaedics, Faculty of Medicine, Chulalongkorn University and King Chulalongkorn Memorial Hospital, Bangkok, Thailand.

Email: dr.worawat@gmail.com



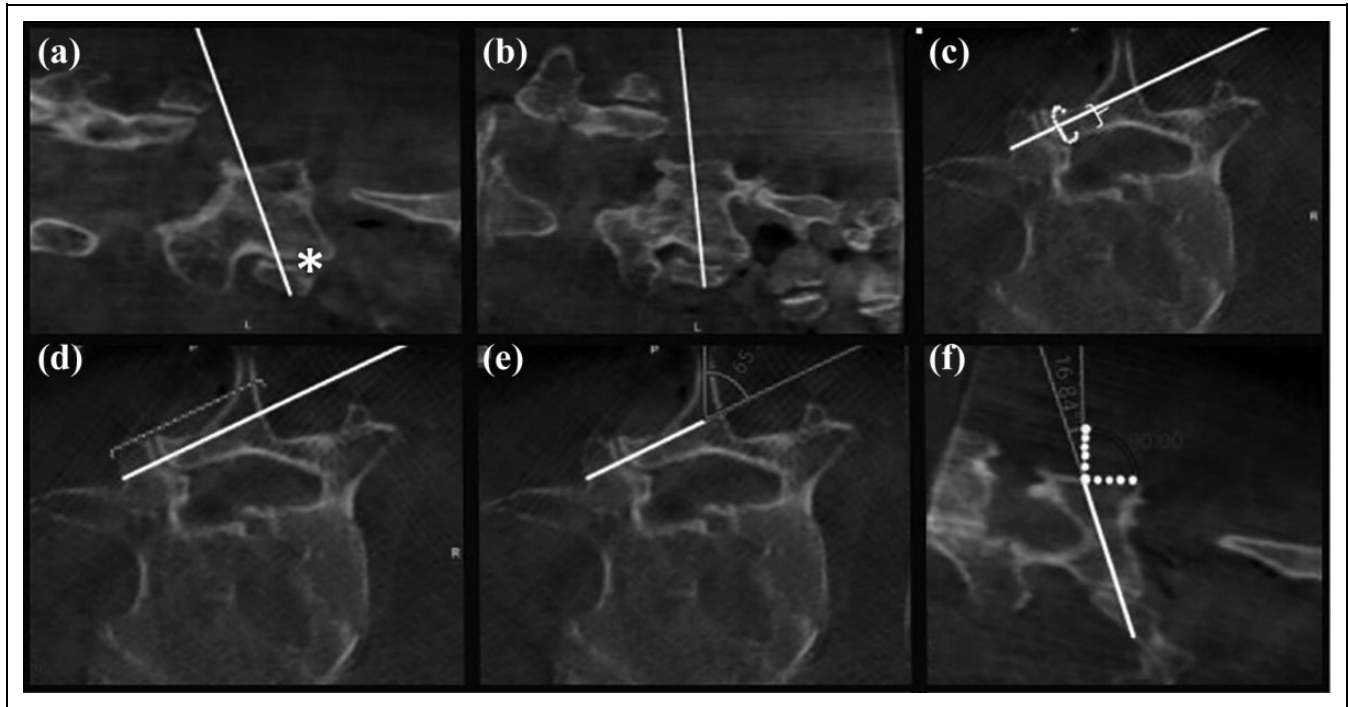


Figure 1. Images along the screw trajectory plane are shown. The starting point trajectory at the cephalad one-third of the spinolamina (white line) crossing the lamina through the contralateral facet joint (asterisk) (a); the starting point at the middle of the spinolamina (white line) (b); inner (white brace) and outer diameter (white dot) of the lamina along the screw trajectory (c); length of the translaminar screw along the trajectory (d); lateral angle of the trajectory relative to the spinous process (e); caudal angle of the trajectory relative to the perpendicular line of the spinolamina (white dot) (f). The solid white line represents the screw trajectory.

joint, and ended at the attachment of the transverse process and the pedicle.

In biomechanical studies involving single and 2-level fusion, TLFS was equivalent in stability to traditional pedicle screw fixation.⁴⁻⁶ Therefore, TLFS could be used to supplement anterior lumbar interbody fusions.⁷ The clinical use of TLFS with a unilateral pedicle screw to supplement lumbar interbody fixation has shown promise—especially using the open and minimally invasive surgery (MIS) technique—with excellent fusion rates of 87.9% to 100%, lower complications, and 35% lower implant costs.⁷⁻¹⁰ Moreover, TLFS can be used bilaterally in degenerative lumbar fusions, resulting in clinical outcomes and complication rates that were comparable to bilateral pedicle screw supplement to TLIF.¹¹

Various screw diameters ranging from 4.0 to 4.5 mm and various insertion points have been reported.¹⁻⁴ Sasso et al¹² used 4.0 mm screws for the placement of TLFS, resulting in a dorsal laminar breach in 50% of cases and a terminal point of screw breakout in 50% of cases. Further investigation of proper screw diameter and correct trajectory is required.¹² Previous studies aimed to evaluate the lamina and facet anatomy for TLFS placement using cadavers or computed tomography (CT) imaging^{13,14}; however, this did not reflect the ideal trajectory of the screw. We performed this study using 3-dimensional (3D) CT-based navigation to evaluate the lamina and facet anatomy of L1-S1 according to the true screw trajectory pathway. This study aimed to evaluate the insertion

point, laminar diameter, screw length, and screw trajectory in TLFS of the lumbar spine.

Methods

This study was approved by the institutional review board of our institution. Eleven fresh frozen human cadavers (7 males, 4 females; mean age 72.7 years [range: 57-94 years]) with intact lumbar spines from L1-S1 were used. Sixty-six vertebral bodies were included. Before measurement, cadavers were first thawed to room temperature (25 °C) and then posterior midline dissection of the lamina of L1-S1 was performed. The O-arm Imaging System, Synergy Spine Software, and StealthStation system (Medtronic Navigation) were used to assess the laminae of the lumbar spines. The navigation probe was placed at the starting point for TLFS placement of each lamina at the base of the spinous process at the spinolaminar junction. Two starting points were evaluated: the cephalad one-third of the spinolamina (1/3SL) (Figure 1a) and the middle of the spinolamina (1/2SL) of each vertebra (Figure 1b). The navigation probe was inserted at the starting point, projecting through the contralateral lamina, crossing the mid-portion of the contralateral facet joint to the base of the contralateral transverse process (Figure 1c and d). The narrowest inner and outer diameters of the lamina along the trajectory of the navigation probe were measured, representing the space for screw diameter placement (Figure 1c). The trajectory length was measured from the

Table 1. The Outer Diameter of the Lamina According to the Cephalad One-Third and One-Half of the Spinolamina in Fresh Cadaveric Vertebrae.

Level	The outer diameter of the lamina (mm), mean \pm SD			P^a
	The cephalad one-third of the spinolamina	The cephalad one-half of the spinolamina	Mean difference	
L1	7.18 \pm 1.37	7.47 \pm 1.38	0.29 \pm 0.66	.081
L2	7.22 \pm 1.33	7.09 \pm 1.06	-0.14 \pm 1.25	.635
L3	6.89 \pm 1.25	6.79 \pm 1.07	-0.11 \pm 0.81	.570
L4	6.5 \pm 1.21	6.65 \pm 1.23	0.15 \pm 0.98	.571
L5	6.59 \pm 1.68	6.7 \pm 1.84	0.11 \pm 1.07	.715
P^b	.564	.362		

^a Comparison between the 2 starting points.

^b Comparison between each spinal level.

starting point at the base of the spinous process to the outermost cortex at the base of the transverse process, representing the screw length (Figure 1d). The trajectory of the probe representing the trajectory of the screw placement was measured as the lateral angle and the caudal angle. The lateral angle was the angle of the navigation probe relative to the spinous process (Figure 1e). The caudal angle was the angle of the navigation probe relative to the perpendicular line of the spinolamina (Figure 1f). All parameters were measured using the O-arm Imaging System, and Synergy Spine Software under the StealthStation system (Medtronic Navigation). All parameters were measured thrice on both sides of the lamina of each vertebra and averages were used for analysis. Statistical analyses were performed using SPSS version 22.0 (IBM Corp, Chicago, IL). The difference in parameters at different vertebral levels was analyzed with a single-factor analysis of variance (ANOVA). The differences between the 2 starting points and the sides were analyzed with a paired *t* test. The difference between sexes was analyzed with an independent *t* test. Intraobserver reliability was evaluated using Cronbach's alpha. A *P* value less than .05 was considered statistically significant.

Results

The 3 observations for each parameter showed good reliability (intraclass correlation coefficient [ICC] >0.75). There was no statistical difference observed between sides and between sexes ($P > .05$). The outer diameters of the lamina were not statistically different from L1-L5 with starting points at 1/3SL and 1/2SL (7.18 \pm 1.37 to 6.59 \pm 1.68 mm and 7.47 \pm 1.38 to 6.7 \pm 1.84 mm, respectively, $P > .05$). No statistical difference ($P > .05$) in the outer diameter was detected between the 2 starting points (Table 1). Similarly, the inner diameters of the lamina were not statistically significant according to either level or starting point (4.58 \pm 1.14 to 3.78 \pm 1.57 mm for 1/3SL and 4.73 \pm 1.04 to 3.86 \pm 1.46 for 1/2SL, $P > .05$) (Table 2). The mean screw lengths gradually increased from L1-L5, ranging from 37.18 \pm 3.58 to 45.67 \pm 7.16 mm for the

Table 2. The Inner Diameter of the Lamina According to the Cephalad One-Third and One-Half of the Spinolamina in Fresh Cadaveric Vertebrae.

Level	The inner diameter of the lamina (mm), mean \pm SD			P^a
	The cephalad one-third of the spinolamina	The cephalad one-half of the spinolamina	Mean difference	
L1	4.58 \pm 1.14	4.73 \pm 1.04	-0.15 \pm 0.81	.443
L2	4.45 \pm 0.96	4.16 \pm 0.59	0.29 \pm 0.69	.077
L3	4.24 \pm 0.97	3.93 \pm 0.67	0.31 \pm 0.77	.089
L4	3.83 \pm 1.07	3.89 \pm 0.87	-0.05 \pm 0.94	.830
L5	3.78 \pm 1.57	3.86 \pm 1.46	-0.09 \pm 0.88	.722
P^b	.377	.112		

^a Comparison between the 2 starting points.

^b Comparison between each spinal level.

SD, standard deviation.

Table 3. Screw Length According to the Cephalad One-Third and One-Half of the Spinolamina in Fresh Cadaveric Vertebrae.^a

Level	Screw length (mm), mean \pm SD			P^b
	The cephalad one-third of the spinolamina	The cephalad one-half of the spinolamina	Mean difference	
L1	37.18 \pm 3.58	36.16 \pm 4.02	1.03 \pm 2.00	.044
L2	39.01 \pm 4.57	38.71 \pm 4.69	0.30 \pm 2.02	.514
L3	41.81 \pm 4.85	40.3 \pm 4.68	1.52 \pm 3.23	.050
L4	44.03 \pm 6.98	44.54 \pm 7.26	-0.51 \pm 2.97	.519
L5	45.67 \pm 7.16	49.29 \pm 10.07	-3.61 \pm 7.52	.096
P^c	.009	<.001		

^a Boldfaced entries indicate statistical significance ($P < .05$).

^b Comparison between the 2 starting points.

^c Comparison between each spinal level.

1/3SL starting point ($P = .009$) and from 36.16 \pm 4.02 to 49.29 \pm 10.07 mm for the 1/2SL starting point ($P < .001$). For the TLFS of L1-2, the screw length with a 1/3SL starting point was significantly longer than that of the 1/2SL starting point ($P = .044$) (Table 3). Regarding the screw path trajectory, the lateral angles gradually increased from L1-L5, ranging from 49.53° \pm 7.98° to 60.1° \pm 9.66° for the 1/3SL starting point ($P = .005$) and from 50.28° \pm 8.78° to 60.77° \pm 8.88° for the 1/2SL starting point ($P = .020$). Conversely, the caudal angles gradually decreased from L1-L5, ranging from 18.53° \pm 7.89° to 4.32° \pm 11.63° for the 1/3SL starting point ($P = .001$) and from 16.19° \pm 9.01° to 1.13° \pm 11.31° for the 1/2SL starting point ($P = .001$). At the L2 and L3 vertebra, the caudal angles of the 1/3SL starting point were significantly greater than those at 1/2SL ($P = .009$ and .011, respectively) (Table 4).

Discussion

Lumbar arthrodesis is a treatment for various degenerative lumbar spinal diseases. Instrumentation of lumbar arthrodesis

Table 4. Screw Trajectory According to the Cephalad One-Third and One-Half of the Spinolamina in Fresh Cadaveric Vertebrae.^a

Level	The cephalad one-third of the spinolamina	The cephalad one-half of the spinolamina	Mean difference	<i>P</i> ^b
Lateral angle				
L1	49.53 ± 7.98	50.28 ± 8.78	-0.75 ± 4.36	.475
L2	48.12 ± 8.31	50.46 ± 8.93	-2.35 ± 3.71	.011
L3	51.02 ± 9.91	51.72 ± 9.47	-0.70 ± 3.26	.349
L4	56 ± 7.39	53.97 ± 7.79	2.04 ± 7.29	.297
L5	60.1 ± 9.66	60.77 ± 8.88	-0.68 ± 5.05	.624
<i>P</i> ^c	.005	.020		
Caudal angle				
L1	18.53 ± 7.89	16.19 ± 9.01	2.34 ± 5.33	.081
L2	18.45 ± 9.87	15.86 ± 9.21	2.59 ± 3.96	.009
L3	16.95 ± 6.63	13.89 ± 7.45	3.06 ± 4.82	.011
L4	8.48 ± 5.98	7.39 ± 5.51	1.10 ± 3.86	.290
L5	4.32 ± 11.63	1.13 ± 11.31	3.20 ± 7.66	.143
<i>P</i> ^c	.001	.001		

^a Boldfaced entries indicate statistical significance ($P < .05$).

^b Comparison between the 2 starting points.

^c Comparison between each spinal level.

is augmented to intensify solid fusion and improve clinical outcomes.^{15,16} The facet screw fixation method can be useful as adjunct instrumentation of lumbar arthrodesis, including interbody and intertransverse process fusion.⁴⁻¹¹

TLFS provides comparable stability to traditional pedicle screw fixation in 1- to 2-level fusion, even stand-alone bilateral facet screw fixation.⁴⁻⁶ It adequately provides stability in the augmentation of anterior lumbar interbody fusion.¹⁷ It can be used to supplement unilateral pedicle screw rod fixation in MIS TLIF with comparable stability to bilateral pedicle screw rod fixation.¹⁸ Because it is less invasive, TLFS is widely used as a supplement to unilateral pedicle screw fixation in MIS TLIF with favorable clinical outcomes, fewer complications, and lower costs.^{7,9,10,19}

To our knowledge, this is the first study to describe the true laminar diameter along with the screw trajectory using real-time 3D CT-based navigation. The narrowest part of the outer diameters of the lamina along the TLFS trajectory represented the maximum diameter of the TLFS. This study showed that the outer diameters of the lamina gradually decreased from 7.18 to 6.59 mm from L1-L5. This result supports the prior empirical use of screw diameter.^{3,8,9,12,17} Kömürçü et al¹⁴ reported mean transverse diameters of L1-L5 as 7.2, 7.6, 7.8, 7.4, and 7.4 mm, respectively. The differences in the outer diameters of the lamina were due to the measurement used in this study, which was the transverse axis of the screw trajectory; however, it is important to note that prior studies used the transverse axis of the vertebral body. Nevertheless, the transverse axis of the screw trajectory accurately represents the true screw diameter.¹⁴ Menga et al²⁰ reported outer lamina diameters at the isthmus in the sagittal plane of L3-L5 as 5.6,

6.8, and 5.8 mm, respectively. Similarly, this does not represent the true diameter of TLFS. The narrowest part of the inner diameters of the lamina, along which the TLFS trajectory is placed, represents the minimum diameter of TLFS to engage the inner cortex. We found that the inner diameters of the lamina also decreased from L1-L5, ranging from 4.73 to 3.86 mm. Meanwhile, Kömürçü et al¹⁴ reported transverse inner diameters from L1-L5 in the transverse vertebral plane of 3.0, 2.8, 3.0, 2.7, and 2.5 mm, respectively. Menga et al²⁰ reported inner laminar diameters in the sagittal plane from L3-L5 of 0.8, 1.9, and 1.7 mm, respectively. Both these studies did not represent the true inner diameter along the translaminar screw trajectory as in this study. Furthermore, we showed that both starting points—the cephalad one-third and one-half of the spinolamina—were not significantly related to outer and inner laminar diameters. Both landmarks can be used as starting points in terms of screw diameter.

The length of the translaminar screw increased from L1-L5, ranging from 37.2 to 45.7 mm. Lu et al¹³ also reported translaminar screw paths, which are measured externally from the base of the spinous process to the base of the transverse process, gradually increasing from L1-L5 of 41.0, 45.3, 47.2, 50.6, and 54.3, respectively. This may cause overestimation of the length due to breaches outside the cortex as well as raise questions regarding the screw location inside the cortical table across all trajectories to catch the contralateral superior facet. A screw that is too long can cause anterior cortex penetration of the transverse process, resulting in nerve root injury.¹³ At the L1 lamina, the 1/3SL starting point required significantly longer screws than that of 1/2SL ($P = .044$), while other levels were not significantly different.

The screw trajectory consists of the lateral angle and the caudal angle. In this study, we measured the lateral angle from the angle between the screw trajectory and the spinous process of each vertebra as the reference, which was also used by Kömürçü et al.¹⁴ It was used as the reference given its consistent anatomy and accessibility, especially with MIS TLIF. Furthermore, this reference did not change with spine rotation due to the deformity or the operation setting. The caudal angle used in this study was measured as the angle between the screw trajectory and the perpendicular line of the spinolamina. The advantages of this reference are its consistent anatomy, accessibility, especially during MIS TLIF, and no change during surgery due to increased or decreased lordosis on the transverse plane of the vertebra, as reported by Lu et al.¹³ The lateral angles increased from L1-L5, ranging from 50.28° to 60.77° for the 1/2SL starting point. The caudal angles decreased from L1-L5, ranging from 16.2° to 1.1° for the 1/2SL starting point. Their characteristics were consistent with that described by Lu et al¹³ in which the L1-L5 lateral angles were 39.0° to 59.5° and the L1-L5 caudal angles were 60.5° to 38.5°. The differences between these values were due to the different references; however, the spinous process and the spinolamina were more consistent and practical intraoperatively. In the L2 lamina, the lateral angle of the 1/3SL starting point was significantly lower than that at 1/2SL ($P = .011$). In the L2 and L3 lamina, the

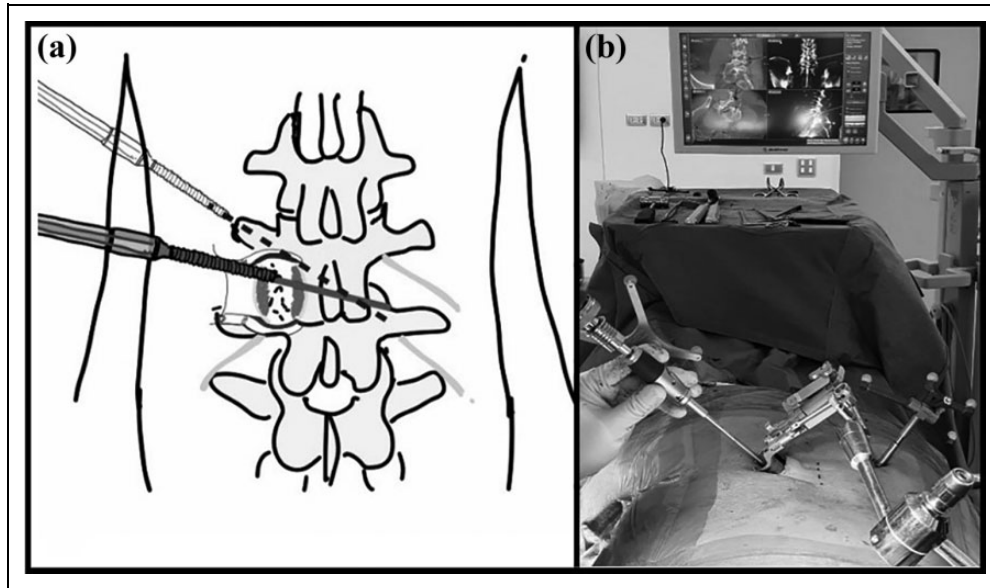


Figure 2. The insertion point of the translaminal facet screw at the cephalad one-half of the spinolamina (dark screw) through the same mini-incision to the contralateral facet in MIS-TLIF of L3-4 (a). The MIS TLIF of L3-4 with the unilateral pedicle screw rod fixation and contralateral translaminal screw fixation via the same mini-incision using navigation (b).

caudal angle of the 1/3SL starting point was significantly larger than that of 1/2SL ($P = .009$ and $.011$, respectively). The caudal angle affected the trajectory of TLFS insertion by which the screw with less caudal angle could be easily inserted through the mini-open incision of MIS TLIF.

MIS TLIF can be performed using the unilateral mini-open paramedian approach in the intermuscular plane of the longissimus and multifidus muscles with a tubular retractor.^{21,22} Bilateral percutaneous pedicle screws are preferred to augment this construct, causing another unnecessary incision and violating the back muscles with the contralateral percutaneous pedicle screw. TLFS is a minimally invasive technique, which can supplement the contralateral fixation of the unilateral pedicle screw, especially in MIS TLIF. Given that the stability of the screws depends on the fourth power of the screw radius, larger diameter screws can be used to enhance the stability of constructs.²³

For TLFS, 5.0- to 6.0-mm diameter screws are recommended for L1-L2, depending on bone quality, and 4.5- to 5.5-mm diameter screws are recommended for L3-L5, which are larger than previous empirical uses, with a 36- to 50-mm long screw inserted through the lamina in the middle of the spinolamina, directed at a 50° to 60° lateral angle from L1-L5 relative to the spinous process, and 16° to 1° caudal angle from L1-L5 relative to the spinolamina. In osteoporotic patients, larger diameter screws should be selected for greater stability. The facet joints of the lower lumbar spine are oriented toward the coronal plane.²⁴ A lateral 40° to 60° angle can orient the screw penetration into the facet joint perpendicularly. The space between the inner cortex of the lamina and the dura ranges from 1.8 to 2.6 mm in the lumbar spine.¹⁴ A small Penfield was used

while drilling the lamina to detect and protect against anterior laminar penetration and palpate the contralateral facet joint that directed the screw trajectory.¹³ Moreover, in cases where bilateral TLFS is used, one screw was inserted at 1/3SL while another contralateral screw was inserted at 1/2SL to prevent screw shaft contact. Therefore, we recommend an insertion point at the cephalad half with TLFS to supplement unilateral pedicle screw fixation in MIS TLIF, given the smaller caudal angle. The screw insertion can be smoother through the same mini-incision used for the Peek cage placement (Figure 2).

One limitation to this study is that measurement errors are possible in an O-arm navigated base morphometric study. However, all measurements were performed thrice by the same spine specialist in the same manner on a 0.830-mm axial slice and 0.415 mm on the coronal and sagittal slice.²⁵ Furthermore, the ICC showed high reliability. Any errors were minimized and negligible. All measurements were performed with O-arm navigation of cadaveric spines that had not been diagnosed definitively with degenerative spinal disease. However, all studied cadavers had aging spines (mean age: 72.7 years), which were degenerated, deformed, and rotated by the aging process. Consequently, the results of this study can be applied to degenerative spinal disease. Further prospective clinical studies on patients may be necessary in order to compare the clinical outcomes between MIS TLIF using a larger TLFS (4.5 mm TLFS for L3-L5 and 5.0 mm TLFS for L1-2) supplemented with unilateral pedicle screw fixation and conventional bilateral pedicle screw fixation. Additionally, biomechanical studies should be conducted to compare the stability of a larger TLFS, in contrast to traditional unilateral/bilateral pedicle screws.

Conclusion

We recommend performing TLFS in MIS TLIF with a diameter of 5.0 mm for L1-L2 and a 4.5-mm diameter for L3-L5, which was larger than previous empirical uses resulting in greater stability, with a 36- to 50-mm screw inserted through the lamina at the middle of the spinolamina, directed with a lateral angle of 50° to 60° from L1-L5 relative to the spinous process with a caudal angle of 16° to 1° from L1-L5 relative to the spinolamina line. The advantages of these references are its consistent anatomy and accessibility. In osteoporotic patients, a 1-mm larger screw (5.5-6.0 mm in diameter) should be selected.

Author Contributions

All authors contributed to the study conception and design. Material preparation, data collection and analysis were performed by Kittisak Songthong, Phattareeya Pholprajug, Wicharn Yingsakmongkol, Vit Kotheeranurak, Worawat Limthongkul. The first draft of the manuscript was written by Weerasak Singhatanadgige and all authors commented on previous versions of the manuscript. All authors read and approved the final manuscript.

Declaration of Conflicting Interests

The author(s) declared no potential conflicts of interest with respect to the research, authorship, and/or publication of this article.

Funding

The author(s) received no financial support for the research, authorship, and/or publication of this article.

ORCID iD

Worawat Limthongkul, MD  <https://orcid.org/0000-0002-0116-8791>

Ethical Approval

This study was approved by the Faculty of Medicine, Chulalongkorn University Institutional Review Board: IRB ID #598/62.

Informed Consent

Informed consent was obtained from legal guardians. The authors affirm that human research participants provided informed consent for publication of the images in Figure 1 and 2b.

References

- King D. Internal fixation for lumbosacral fusion. *J Bone Joint Surg Am.* 1948;30:560-565. doi:10.2106/00004623-194830030-00003
- Boucher HH. A method of spinal fusion. *J Bone Joint Surg Br.* 1959;41-B:248-259. doi:10.1302/0301-620X.41B2.248
- Benini A, Magerl F. Selective decompression and translaminar articular facet screw fixation for lumbar canal stenosis and disc protrusion. *Br J Neurosurg.* 2009;7:413-418. doi:10.3109/02688699309103497
- Ferrara LA, Secor JL, Jin BH, Wakefield A, Inceoglu S, Benzel EC. A biomechanical comparison of facet screw fixation and pedicle screw fixation: effects of short-term and long-term repetitive cycling. *Spine (Phila Pa 1976).* 2003;28:1226-1234. doi:10.1097/01.BRS.0000065485.46539.17
- Mahar A, Kim C, Oka R, et al. Biomechanical comparison of a novel percutaneous transfacet device and a traditional posterior system for single level fusion. *J Spinal Disord Tech.* 2006;19:591-594. doi:10.1097/01.bsd.0000211238.21835.e4
- Eskander M, Brooks D, Ordway N, Dale E, Connolly P. Analysis of pedicle and translaminar facet fixation in a multisegment interbody fusion model. *Spine (Phila Pa 1976).* 2007;32:E230-E235. doi:10.1097/01.brs.0000259232.30302.bf
- Best NM, Sasso RC. Efficacy of translaminar facet screw fixation in circumferential interbody fusions as compared to pedicle screw fixation. *J Spinal Disord Tech.* 2006;19:98-103. doi:10.1097/01.bsd.0000179244.76244.5e
- Sethi A, Lee S, Vaidya R. Transforaminal lumbar interbody fusion using unilateral pedicle screws and a translaminar screw. *Eur Spine J.* 2008;18:430-434. doi:10.1007/s00586-008-0825-4
- Huang P, Wang Y, Xu J, et al. Minimally invasive unilateral pedicle screws and a translaminar facet screw fixation and interbody fusion for treatment of single-segment lower lumbar vertebral disease: surgical technique and preliminary clinical results. *J Orthop Surg Res.* 2017;12:117. doi:10.1186/s13018-017-0606-z
- Awad BI, Lubelski D, Shin JH, et al. Bilateral pedicle screw fixation versus unilateral pedicle and contralateral facet screws for minimally invasive transforaminal lumbar interbody fusion: clinical outcomes and cost analysis. *Global Spine J.* 2013;3:225-230. doi:10.1055/s-0033-1349399
- Grob D, Bartanusz V, Jeszenszky D, et al. A prospective, cohort study comparing translaminar screw fixation with transforaminal lumbar interbody fusion and pedicle screw fixation for fusion of the degenerative lumbar spine. *J Bone Joint Surg Br.* 2009;91-B:1347-1353. doi:10.1302/0301-620X.91B10.22195
- Sasso RC, Best NM, Potts EA. Percutaneous computer-assisted translaminar facet screw: an initial human cadaveric study. *Spine J.* 2005;5:515-519. doi:10.1016/j.spinee.2005.03.016
- Lu J, Ebraheim NA, Yeasting RA. Translaminar facet screw placement: an anatomic study. *Am J Orthop (Belle Mead NJ).* 1998;27:550-555.
- Kömürcü E, Kaymaz B, Adam G, Gölge UH, Göksel F, Özden R. Safety and feasibility of lumbar spine for intralaminar screw fixation: a computed tomography-based morphometric study. *Acta Orthop Traumatol Turc.* 2015;49:522-529. doi:10.3944/AOTT.2015.14.0201
- Endler P, Ekman P, Moller H, Gerdhem P. Outcomes of posterolateral fusion with and without instrumentation and of interbody fusion for isthmic spondylolisthesis: a prospective study. *J Bone Joint Surg Am.* 2017;99:743-752. doi:10.2106/JBJS.16.00679
- Alvi MA, Alkhataybeh R, Wahood W, et al. The impact of adding posterior instrumentation to transpoas lateral fusion: a systematic review and meta-analysis. *J Neurosurg Spine.* 2018;30:211-221. doi:10.3171/2018.7.SPINE18385
- Kim SM, Lim TJ, Paterno J, Kim DH. A biomechanical comparison of supplementary posterior translaminar facet and transfacetopedicular screw fixation after anterior lumbar interbody fusion. *J Neurosurg Spine.* 2004;1:101-107. doi:10.3171/spi.2004.1.1.0101

18. Slucky AV, Brodke DS, Bachus KN, Droge JA, Braun JT. Less invasive posterior fixation method following transforaminal lumbar interbody fusion: a biomechanical analysis. *Spine J*. 2006;6:78-85. doi:10.1016/j.spinee.2005.08.003
19. Tuli J, Tuli S, Eichler ME, Woodard EJ. A comparison of long-term outcomes of translaminar facet screw fixation and pedicle screw fixation: a prospective study. *J Neurosurg Spine*. 2007;7:287-292. doi:10.3171/SPI-07/09/287
20. Menga EN, Jain A, Kebaish KM, Zimmerman SL, Sponseller PD. Anatomic parameters: direct intralaminar screw repair of spondylolysis. *Spine (Phila Pa 1976)*. 2004;39:E153-E158. doi:10.1097/BRS.0000000000000118
21. Mobbs RJ, Phan K, Malham G, Seex K, Rao PJ. Lumbar interbody fusion: techniques, indications and comparison of interbody fusion options including PLIF, TLIF, MI-TLIF, OLIF/ATP, LLIF and ALIF. *J Spine Surg*. 2015;1:2-18. doi:10.3978/j.issn.2414-469X.2015.10.05
22. Hansen-Algenstaedt N, Liem M, Khalifah SO, Ilg A, Giese A. Minimal-invasive TLIF. *Eur Spine J*. 2016;25(suppl 4):473-475. doi:10.1007/s00586-016-4759-y
23. Truumees E. Thoracic and lumbar instrumentation: anterior and posterior. In: Garfin SR, Eismont FJ, Bell G, Bono C, eds. *Rothman-Simeone and Herkowitz's the Spine*. 7th ed. Elsevier; 2018:1187-1217.
24. Panjabi MM, Oxland T, Takata K, Goel V, Duranceau J, Krag M. Articular facets of the human spine. Quantitative three-dimensional anatomy. *Spine (Phila Pa 1976)*. 1993;18:1298-1310. doi:10.1097/00007632-199308000-00009
25. Medtronic. O-ARM[®] complete multidimensional surgical imaging. Accessed September 17, 2020. https://www.bnasurg.com/wp-content/uploads/2016/09/O-arm_brochure.pdf