



Prenatal diagnosis of fetal midgut volvulus: a case description

Junjun Chen, Daozhu Wu

Department of Ultrasound Diagnosis, The Second Affiliated Hospital and Yuying Hospital of Wenzhou Medical University, Wenzhou, China

Correspondence to: Daozhu Wu. Department of Ultrasound Diagnosis, The Second Affiliated Hospital and Yuying Hospital of Wenzhou Medical University, 109 Xueyuan Western Road, Wenzhou, China. Email: wdz6276@163.com.

Submitted Jan 13, 2022. Accepted for publication May 20, 2022.

doi: 10.21037/qims-22-37

View this article at: <https://dx.doi.org/10.21037/qims-22-37>

Introduction

Congenital midgut volvulus is a rare condition in which the small bowel is looped or the proximal colon twisted around the superior mesenteric artery (1,2). In severe cases, the condition can lead to intestinal necrosis, threatening perinatal and neonatal life. In the absence of specific signs on ultrasound (US), the prenatal diagnosis of this type of midgut volvulus can prove difficult. While there are numerous reports of neonatal cases of volvulus in the literature, antenatal occurrences have been reported less frequently. Here, we report and analyze the case of a fetus found with an abdominal mass that was ultimately diagnosed as fetal midgut volvulus.

Case presentation

The patient was a 31-year-old female, for whom no fetal abnormalities had been noted during the prenatal checkup. At 30 weeks of gestation, fetal US examination detected a mixed echogenic mass measuring 73 mm × 52 mm in the fetal abdominal cavity (*Figure 1*), accompanied by polyhydramnios. A subsequent US at 31 weeks of gestation detected a size increase in the intra-abdominal mass to 82 mm × 53 mm and showed an amniotic fluid index of 260 mm. Excessive torsion of the umbilical cord was also observed (*Figure 2*). Scans performed later showed a progressive stabilization of the mass. At the same time, a magnetic resonance imaging (MRI) examination revealed a fetal intra-abdominal mass with a line-like separation and abnormal nodular signals. An MRI diagnosis of cystadenoma was considered (*Figure 3*). At 32 weeks of gestation, US scan findings revealed that the fetal abdominal mass was in

fact a significantly expanded, fluid-filled loop of bowel, and the adjacent bowel loops were also expanded with excessive torsion of the cord still at a visible height (*Figure 4*). Given the US findings, fetal midgut volvulus was suspected. Based on scans performed later, the team decided on observational management.

The female patient experienced premature rupture of membranes at 32 weeks of gestation, at which point cardiotocography showed loss of variability but no acceleration of the fetal heart rate. Subsequently, the obstetrician performed an emergency cesarean section, and a boy weighing 1.94 kg was delivered. The infant had an Apgar score of 9 and 10 at 1 and 5 minutes, respectively, and his pulse, blood pressure, and temperature were within the normal ranges. After birth, the neonatal abdominal X-ray showed evidence of small bowel dilation with multiple air-fluid levels (*Figure 5*), which prompted emergency surgery. Intraoperatively, part of the small intestine was found to be turned 540° counterclockwise. The extreme dilation of the ischemic small intestine was reversed, and the necrotic small intestine was resected. The operative findings were consistent with midgut volvulus. After appropriate surgical intervention, the infant survived and continued to show normal growth and development in subsequent follow-up.

All procedures described in this study were performed in accordance with the ethical standards of the institutional and/or national research committee(s) and with the Helsinki Declaration (as revised in 2013). Written informed consent was obtained from the patient for the publication of this case report and the accompanying images. A copy of the written consent form is available for review by the editorial office of this journal.

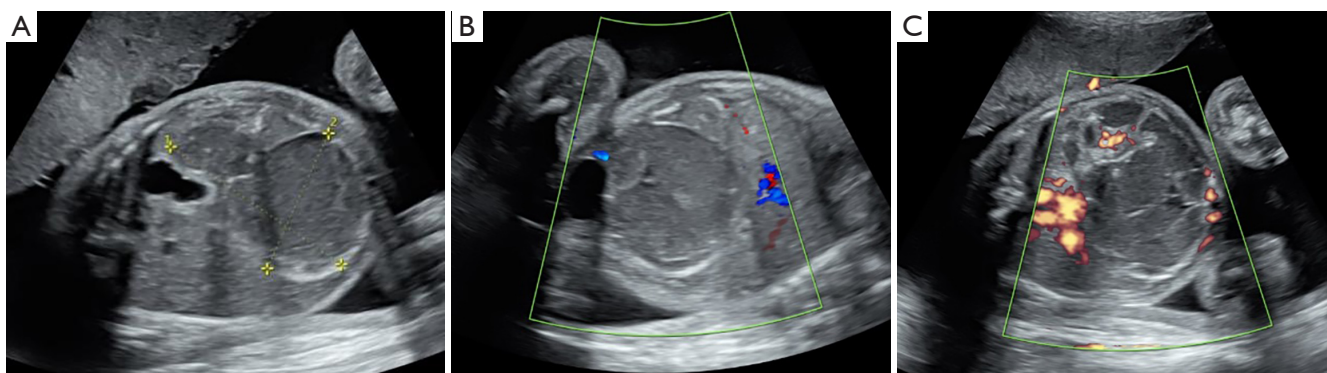


Figure 1 Ultrasound features at 30 weeks of gestation. (A) shows a mass in the abdominal cavity of the fetus. (B) (color Doppler) and (C) (energy Doppler) show the detection of blood flow signals around the abdominal wall (the mass was determined to be a midgut volvulus on follow-up).

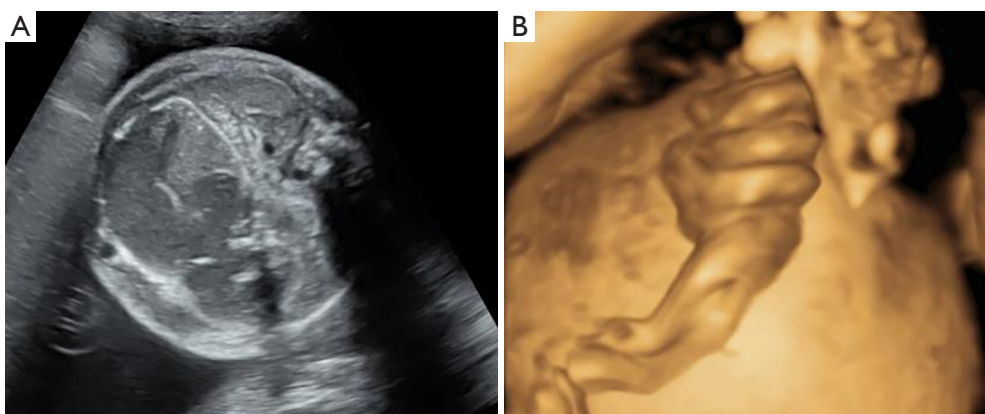


Figure 2 The fetal intraperitoneal mass gradually increased and three-dimensional ultrasound revealed a high torsion of the fetal cord.

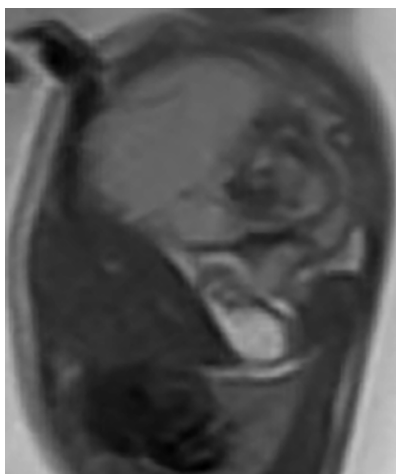


Figure 3 Ultrasound image at 31 weeks of pregnancy. In this image, the dilated intestine surrounding the superior mesenteric artery presents as a “whirlpool” sign.

Discussion

During normal embryonic development, the midgut rotates 270° counterclockwise around the axis of the superior mesenteric artery to complete normal intestinal rotation and internal fixation through mesenteric attachment. Abnormal rotation of the bowel within the peritoneal cavity during embryogenesis provides the pathological basis of ultrasonic manifestations (3). Fetal midgut volvulus was first reported by Crisera *et al.* (4) in 1999. The incidence of midgut volvulus has been estimated to be 1 in every 6,000 live births (5). In most cases, midgut volvulus is secondary, with the most common cause being intestinal malrotation, which can lead to necrotic intestinal perforation and in severe cases, hemorrhagic ascites, anemia, and fetal death. Maternal and fetal outcomes following midgut volvulus can be disastrous, especially if the diagnosis is delayed.

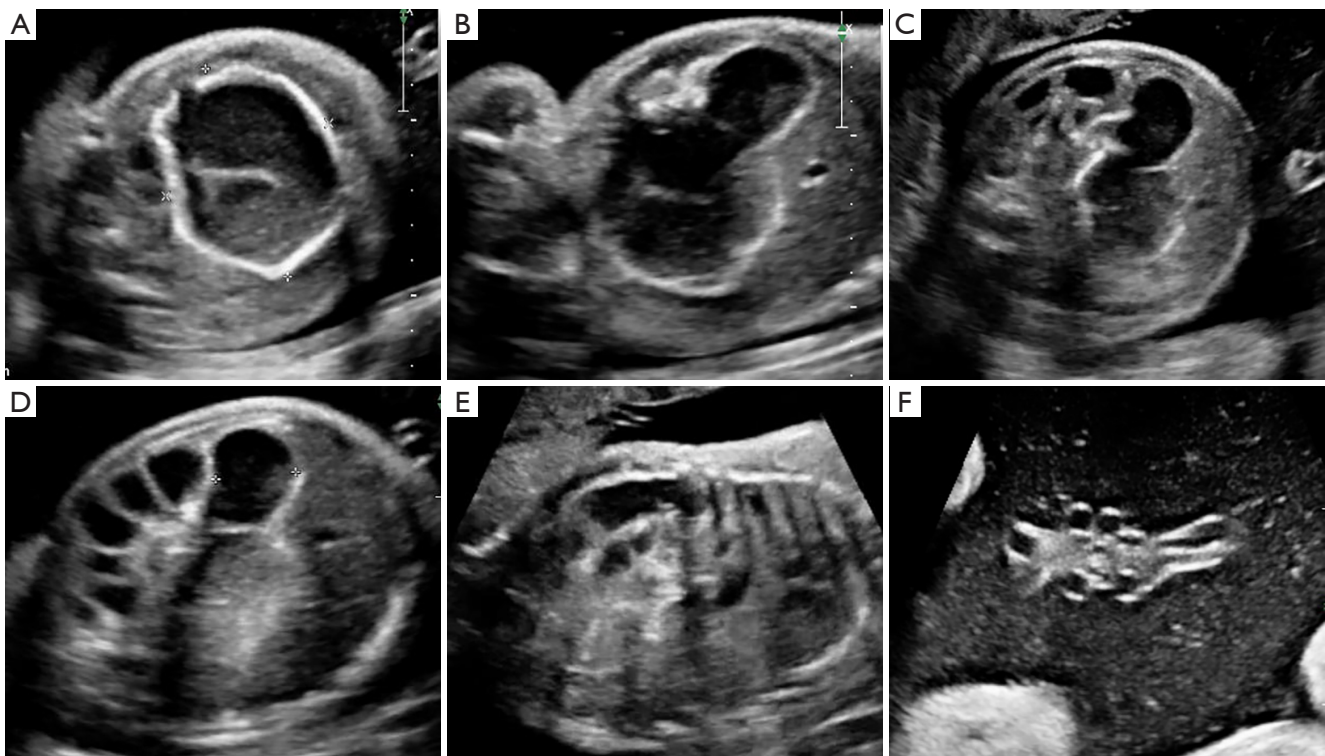


Figure 4 Ultrasound features at 32 weeks of gestation. Ultrasound features at 32 weeks of gestation. (A,B) show the significantly enlarged intestine and the thickened intestinal wall. (C,D) show this segment of intestine communicating with the surrounding intestine. (E) shows the appearance of the “coffee bean” sign. (F) shows the middle of the umbilical cord rotated twice.

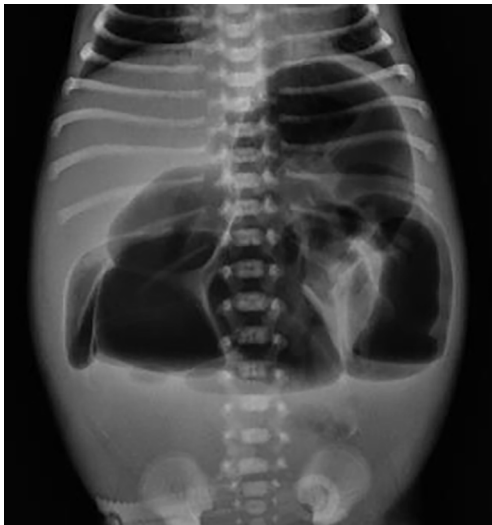

Figure 5 The dilatation of the intestine.

Although recent studies have shown that US examination can show gastrointestinal organs such as the sigmoid colon during early pregnancy, this is often difficult to achieve and requires an experienced physician (6). Before 20 weeks of gestation, due to the lack of contents in the fetal intestine, the intestinal loop is in a collapsed shape and the structure of the loop wall is not clear. At around 24 weeks of pregnancy, distinguishing the fetal small intestine and colon echo on US is easy; therefore, some congenital digestive system deformities can be detected in mid to late pregnancy. However, prenatal diagnosis of this type of malformation fetal midgut volvulus can prove difficult in the absence of specific signs. Some scholars maintain that the sonographic findings of a typical “whirlpool” can be used as the specific sign of a volvulus in intestinal malrotation. This “whirlpool” sign depicts loops of the small intestine more or less dilated and winding in a spiral form in two-

dimensional (2D) mode; in color Doppler, it corresponds to a particular coiled configuration of the superior mesenteric vessels, with the vein winding around an axis centered on the artery (7,8). The “coffee bean” sign—a dilatation of a very short bowel segment that resembles a coffee bean—is another characteristic sign of volvulus (9). Specifically, the closed loop of the volvulus results in incomplete intestinal obstruction, and fetal amniotic fluid cannot pass through from the proximal to the distal loops and reciprocate intestinal motion. Consequently, there is a significant increase in the closed bowel loop due to edema thickening, which is shaped like a coffee bean (10). This sign, however, is not necessarily caused by intestinal malrotation: severe meconium obstruction caused by intestinal torsion can also appear as a “coffee bean” sign. Also, prenatal US signs of midgut volvulus include intestinal dilatation, polyhydramnios, meconium peritonitis, ascites, and fetal edema (11,12). In the above-described case, the fetal US was initially characterized by an abdominal mass which was subsequently revised at follow-up by US. Clockwise rotation of the small bowel around the axis of the superior mesentery artery and vein was confirmed by MRI. Although the “whirlpool” signs on MRI were initially ignored, the MRI signs were consistent with the surgical diagnosis of volvulus. The identification of volvulus allowed for close prenatal monitoring and referral to postnatal management in a specialized pediatric center. As this case demonstrates, the survival rate of fetal midgut volvulus can be significantly improved by timely surgical intervention (13,14).

Fetal intestinal volvulus has characteristic ultrasonic signs that can support a diagnosis; however, US findings tend to be non-specific and understanding of the signs of this condition is currently limited. The presence of indirect signs also helps to improve the accuracy of US-based diagnosis. These indirect signs include the presence of a differential, fluid-filled level in a dilated intestinal loop, polyhydramnios, a meconium pseudocyst or ascites, and signs of meconium peritonitis. The US diagnosis of fetal volvulus plays an important role in the management of obstetrics and the formulation of early treatment plans for newborns.

Acknowledgments

Funding: None.

Footnote

Conflicts of Interest: Both authors have completed the

ICMJE uniform disclosure form (available at <https://qims.amegroups.com/article/view/10.21037/qims-22-37/coif>). The authors have no conflicts of interest to declare.

Ethical Statement: The authors are accountable for all aspects of the work in ensuring that questions related to the accuracy or integrity of any part of the work are appropriately investigated and resolved. All procedures performed in this study were in accordance with the ethical standards of the institutional and/or national research committee (s) and with the Helsinki Declaration (as revised in 2013). Written informed consent was obtained from the patient for publication of this case report and accompanying images. A copy of the written consent is available for review by the editorial office of this journal.

Open Access Statement: This is an Open Access article distributed in accordance with the Creative Commons Attribution-NonCommercial-NoDerivs 4.0 International License (CC BY-NC-ND 4.0), which permits the non-commercial replication and distribution of the article with the strict proviso that no changes or edits are made and the original work is properly cited (including links to both the formal publication through the relevant DOI and the license). See: <https://creativecommons.org/licenses/by-nc-nd/4.0/>.

References

1. Neville JJ, Sharma E, Al-Muzrakchi A, Sheth H. Congenital intestinal malrotation presenting in octogenarians: a report of two cases. *Ann R Coll Surg Engl* 2020;102:e12-4.
2. Chong E, Liu DS, Rajagopal V, Strugnell N. Midgut volvulus secondary to congenital malrotation in pregnancy. *BMJ Case Rep* 2020;13:234664.
3. Chouikh T, Mottet N, Cabrol C, Chaussy Y. Prenatal intestinal volvulus: look for cystic fibrosis. *BMJ Case Rep* 2016;2016:bcr2016217003.
4. Crisera CA, Ginsburg HB, Gittes GK. Fetal midgut volvulus presenting at term. *J Pediatr Surg* 1999;34:1280-1.
5. Steffensen TS, Gilbert-Barness E, DeStefano KA, Kontopoulos EV. Midgut volvulus causing fetal demise in utero. *Fetal Pediatr Pathol* 2008;27:223-31.
6. Wozniak S, Florjanski J, Kordecki H, Podhorska-Okolow M, Domagala Z. Fetal sigmoid colon mesentery - In relevance in fetal ultrasound application. A pilot study. *Ann Anat* 2018;216:152-8.

7. Chakraborty A, Ayoob A, DiSantis D. Coffee bean sign. *Abdom Imaging* 2015;40:2904-5.
8. Tang X, Tao R, Zhang X, Jin Q, He W. Assessment of fetal superior mesenteric artery and vein by three-dimensional power Doppler sonography. *Zhejiang Da Xue Xue Bao Yi Xue Ban* 2019;48:453-8.
9. Park JS, Cha SJ, Kim BG, Kim YS, Choi YS, Chang IT, Kim GJ, Lee WS, Kim GH. Intrauterine midgut volvulus without malrotation: diagnosis from the 'coffee bean sign'. *World J Gastroenterol* 2008;14:1456-8.
10. Rousslang ND, Hansen JR, Lum E, Tamamoto KA, McGrain AH, Rooks VJ. Target sign of intussusception versus whirlpool sign of midgut volvulus. *Radiol Case Rep* 2021;17:670-5.
11. Jéquier S, Hanquinet S, Bugmann P, Pfizenmaier M. Antenatal small-bowel volvulus without malrotation: ultrasound demonstration and discussion of pathogenesis. *Pediatr Radiol* 2003;33:263-5.
12. Miyakoshi K, Tanaka M, Miyazaki T, Yoshimura Y. Prenatal ultrasound diagnosis of small-bowel torsion. *Obstet Gynecol* 1998;91:802-3.
13. Ezer SS, Oguzkurt P, Temiz A, Ince E, Gezer HO, Demir S, Hicsonmez A. Intestinal malrotation needs immediate consideration and investigation. *Pediatr Int* 2016;58:1200-4.
14. Shen AW, Kothari A, Flint A, Kumar S. Prenatal imaging features and perinatal outcomes of foetal volvulus-A literature review. *Prenat Diagn* 2022;42:192-200.

Cite this article as: Chen J, Wu D. Prenatal diagnosis of fetal midgut volvulus: a case description. *Quant Imaging Med Surg* 2022;12(8):4326-4330. doi: 10.21037/qims-22-37