

# Condylar Disarticulation; Analysis of 20 Cases from a Nigerian Tertiary Centre

Victor I Akinmoladun, Adeola A Olusanya, Wasiu O Olawole

Department of Oral and Maxillofacial Surgery, University College Hospital, Ibadan, Nigeria

## ABSTRACT

**Background:** A disarticulation resection is a variant of mandibular segmental resection in which the condylar articulation is sacrificed. Indication varies from primary condylar lesions to jaw conditions involving the condyle. **Aim:** This retrospective analysis was carried out to highlight the pattern of disarticulation resections carried out in our centre over a five-year period. **Materials and Methods:** Cases of mandibular resection were identified from the operation book. The medical records of patients who had disarticulation resection were then retrieved and analyzed for demography, indications for disarticulations, methods of reconstruction and complications. **Results:** A total of 20 cases of disarticulation with complete records were obtained, this constituted 24.7% of total mandibular resections in the department. There were 9 males and 11 females with a male: female ratio of 1:1.2. The age ranged between 13 and 59 years with a mean of 30.4 years (std. 12.0). Sixteen patients received autogenous bone graft; two were stabilized using Steinman's pins and two with reconstruction plates. One bone graft and one reconstruction plate were removed because of infection and exteriorization respectively. Condyle was not replaced in any case. Outcomes were satisfactory but jaw deviation on opening was a common complaint in all cases. **Conclusion:** Condylar disarticulation accounts for a considerably high percentage of mandibular resection in our centre. Non vascularized immediate bone grafting without actual joint reconstruction was common. No disarticulation was carried out for traumatic reasons.

**KEYWORDS:** Condylar, disarticulation, pattern

## INTRODUCTION

A wide variety of benign and malignant neoplastic conditions, as well as nonneoplastic diseases necessitate partial resection of the mandible, depending on the magnitude of the pathologic entity and the required bony margin dictated by the specific pathologic entity. A disarticulation resection is a variety of segmental resection in which the condylar articulation is sacrificed. Due to the paramount importance of the condyle in mandibular function, the surgeon must exercise judgment when contemplating the sacrifice of this structure. An overly aggressive approach to mandibular tumor surgery might adversely affect mandibular function postoperatively if the condyle was unnecessarily resected, whereas a rather conservative resection

### Address for correspondence:

Dr. Victor I Akinmoladun,  
Department of Oral and Maxillofacial Surgery,  
University College Hospital, Ibadan, Nigeria.  
E-mail: viakinmoladun@yahoo.com

### Access this article online

#### Quick Response Code:



Website: [www.nigerianjsurg.com](http://www.nigerianjsurg.com)

DOI:  
10.4103/1117-6806.103105

that preserves the condyle will predispose the patient to persistent disease if the condyle should have been sacrificed.<sup>[1]</sup>

Disarticulation resection of the mandible results in a complex deformity that has significant potential to affect facial appearance and oral function. A successful reconstruction of such a deformity could restore the facial form, maintain the premorbid dental relationship, and preserve mouth opening and function. The purpose of this study was to review the cases of mandibular condyle disarticulation carried out in our centre over a five year period.

## MATERIALS AND METHODS

This study retrospectively examined the medical records of cases of mandibular resections carried out in the department of oral and maxillofacial surgery of the hospital from 2005 to 2010. Cases of disarticulation with complete medical records were further examined for demographics, indications for disarticulation reconstruction and complications recorded.

## RESULTS

Eighty-one mandibular resections were carried out within the study period, out of which twenty six were disarticulations, however twenty had complete records and were used for this exercise. The age ranged between 13 and 59 years. The mean age being 30.4 years (12.0 std). There were 9 males and 11 females with a male: female ratio of 1:1.2. Ameloblastoma was the indication for 70.0% of disarticulation [Figure 1]. Sixteen cases

had primary reconstruction with autogenous non vascularized iliac crest graft, two had Steinman's pin with acrylic condylar head for stabilization and two were reconstructed with bone plate alone. All patients were placed in maxillomandibular fixation for periods ranging from one week (for those with pins and plates) and six weeks for others. Though acceptable facial profile was achieved in all cases, all patients complained about less than optimal function and mandibular deviation on opening. The

frequency of the complications recorded is as shown in Figure 2.

## DISCUSSION

Disarticulation resection of the mandible is a specific variant of segmental resection that is indicated in a variety of pathologic and traumatic conditions that affect the mandible and contiguous structures.<sup>[2-6]</sup> Three patterns of extension of pathology into the condylar region necessitates disarticulation; the pathologic process involves the condylar head proper, involvement of the subcondylar region such that inclusion of the appropriate bony linear margin results in complete disarticulation and involvement of the inferior subcondylar region such that addition of the required linear bony margin would otherwise result in the preservation of only an impractical volume of condylar head that would not assist bony reconstruction of the mandible, nor would this small volume of bone favorably affect mandibular function.<sup>[1]</sup>

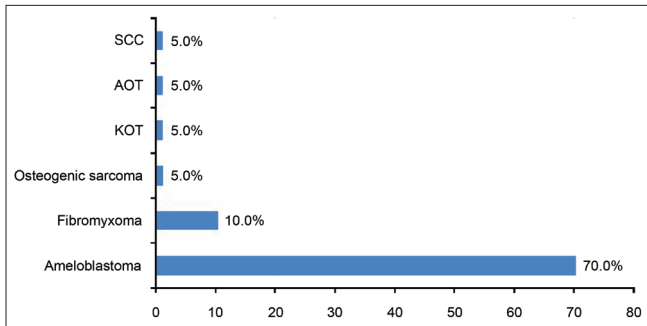


Figure 1: Frequency of diagnosis of the mandibular tumor

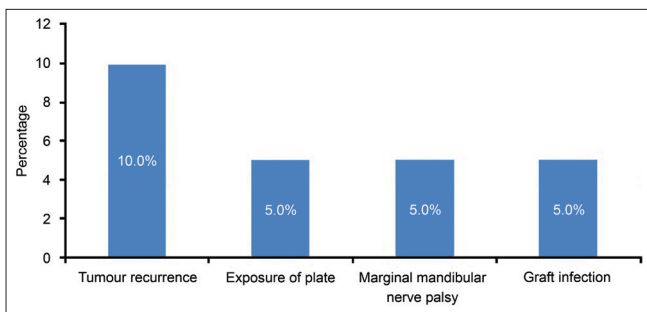


Figure 2: Types of complications recorded

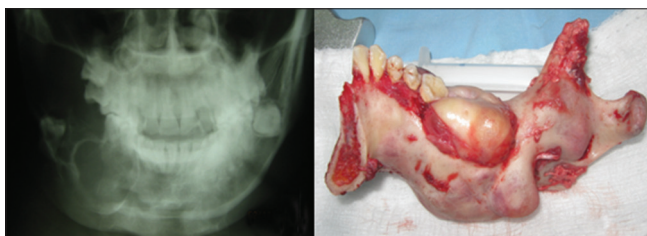

Figure 3: Radiograph and specimen of a large ameloblastoma requiring disarticulation resection

Although this procedure has been described as a relatively rare procedure accounting for 5% of mandibular procedure carried out by Carlson<sup>[1]</sup> in an 8-year period, it accounted for 24.7% of mandibular resections in our centre in a five-year period. This difference can be explained by the delayed presentation typical of patients in this environment, the fact that study centre is a referral centre for a large population could be another [Figure 3]. Also, routine jaw radiograph used for dental assessment, which often draws attention to the presence of a tumor before facial swelling becomes obvious is not practiced in our environment because of poor level of oral health awareness and poverty. More typically posteriorly located tumors with medullary growth were seen more often in this series.

The goals of reconstruction include not only the rehabilitation of the complex mechanism of the normal joint, but also the restoration of facial symmetry, occlusion, and mastication. Four methods have been described for immediate reconstruction: condylar prostheses;<sup>[7-9]</sup> native condyle;<sup>[10-12]</sup> costochondral grafts;<sup>[13]</sup> vascular free flaps (fibula and second metatarsal);<sup>[14-16]</sup> and fibular free flap with long term follow up of radiological findings.<sup>[17]</sup> Although titanium prostheses have their advocates, the fibula flap has been widely popularized.<sup>[18]</sup>

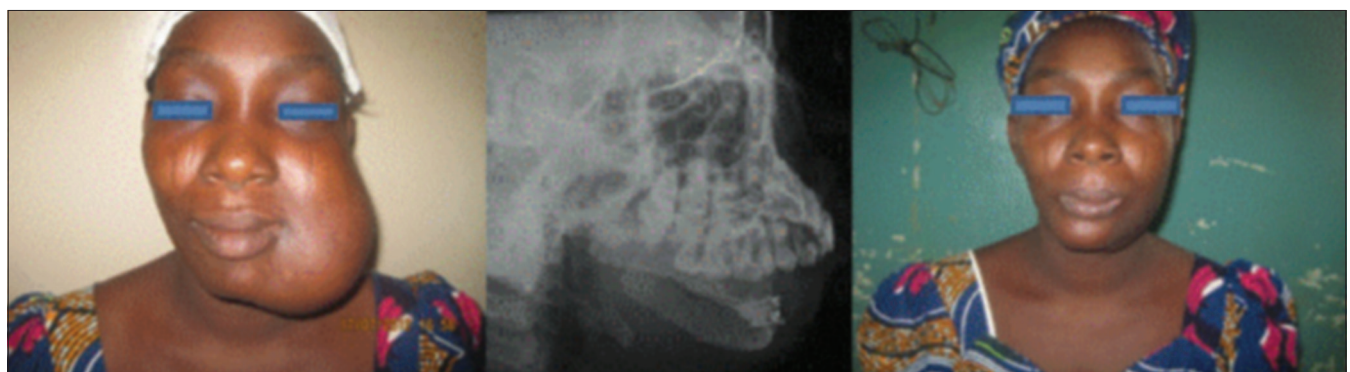


Figure 4: Preoperative appearance, graft *in-situ* and postoperative photograph

The poor resource practice and cost continue to constitute barriers against optimum reconstruction of patients who undergo major ablative surgery involving the joint. No actual condylar replacement was carried out in any patient in this series. Steinman's pins are usually inserted in malignant conditions and extensive tumors where soft tissue cover for grafts was inadequate. The pin is usually removed and replaced with autogenous non vascularized iliac crest bone graft [Figure 4].

Though most patients in this series were apparently satisfied with post-operative facial appearance, they tended to complain of function as less than optimal. The failure to mention the meniscus in the operation note could mean it was not usually considered a major factor in treatment; this may be a contributing factor in tumor recurrence.<sup>[1]</sup>

## CONCLUSION

Condylar disarticulation accounts for a considerably high percentage of mandibular resection in our centre than generally reported due largely to late presentation. No actual joint reconstruction was carried out in any patient during the study period due largely to the poor resource nature of environment of study. Though appearance was reported satisfactory by patients, function was less than optimum hence efforts should be made to provide reconstructed joints.

## REFERENCES

- Carlson ER. Disarticulation resections of the mandible: A prospective review of 16 cases. *J Oral Maxillofac Surg* 2002;60:176-81.
- MacIntosh RB. The case for autogenous reconstruction of the adult temporomandibular joint. In: Worthington P, Evans JR, editors. *Controversies in Oral and Maxillofacial Surgery*. Philadelphia, PA: Saunders; 1994. p. 356-80.
- MacIntosh RB. Juvenile ossifying fibroma. *Oral Maxillofac Surg Clin North Am* 1997;9:713-20
- Marx RE, Cillo JE Jr, Broumand V, Ulloa JJ. Outcome analysis of mandibular condylar replacements in tumor and trauma reconstruction: A prospective analysis of 131 cases with long-term follow-up. *J Oral Maxillofac Surg* 2008;66:2515-23.
- MacIntosh RB. Current spectrum of costochondral and dermal grafting. In: Bell WH, editor. *Modern Practice in Orthognathic and Reconstructive Surgery*. Philadelphia, PA: Saunders; 1992. p. 872-949.
- Catone GA, Carlson ER. Squamous cell carcinoma of the temporomandibular joint: Report of a case with long-term follow up. *J Oral Maxillofac Surg* 1990;48:515.
- van Loon JP, de Bont GM, Boering G. Evaluation of temporomandibular joint prostheses: Review of the literature from 1946 to 1994 and implications for future prosthesis designs. *J Oral Maxillofac Surg* 1995;53:984-97.
- Collins CP, Wilson KJ, Collins PC. Lateral pterygoid myotomy with reattachment to the condylar neck: An adjunct to restore function after total joint reconstruction. *Oral Surg Oral Med Oral Pathol Oral Radiol Endod* 2003;95:672-3.
- Wolford LM, Pitta MC, Reiche-Fischel O, Franco PF. TMJ Concepts/Techmedica custom-made TMJ total joint prosthesis: 5-year follow-up study. *Int J Oral Maxillofac Surg* 2003;32:268-74.
- Boyne PJ. Free grafting of traumatically displaced or resected mandibular condyles. *J Oral Maxillofac Surg* 1989;47:228-32.
- Hidalgo DA. Condyle transplantation in free flap mandible reconstruction. *Plast Reconstr Surg* 1994;93:770-83.
- Nahabedian MY, Tufaro A, Manson PN. Improved mandible function after hemimandibulectomy, condylar head preservation, and vascularised fibular reconstruction. *Ann Plast Surg* 2001;46:506-10.
- Saeed NR, Kent JN. A retrospective study of the costochondral graft in TMJ reconstruction. *Int J Oral Maxillofac Surg* 2003;32:606-9.
- Wax MK, Winslow CP, Hansen J. A retrospective analysis of temporomandibular joint reconstruction with free fibula microvascular flap. *Laryngoscope* 2000;110:977-81.
- Landa LE, Gordon C, Dahar N, Sotereanos GC. Evaluation of long-term stability in second metatarsal reconstruction of the temporomandibular joint. *J Oral Maxillofac Surg* 2003;61:65-71.
- Bond SE, Saeed NR, Cussons PD, Watt-Smith SR. Reconstruction of the temporomandibular joint by the transfer of the free vascularised second metatarsal. *Br J Oral Maxillofac Surg* 2004;42:241-5.
- Guyot L, Richard O, Layoun W. Long-term radiological findings following reconstruction of the condyle with fibular free flaps. *J Craniomaxillofac Surg* 2004;32:98-102.
- González-García R, Naval-Gías L, Rodríguez-Campo FJ, Martínez-Chacón JL, Gil-Díez JL. Vascularized fibular flap for reconstruction of the condyle after mandibular ablation. *J Oral Maxillofac Surg* 2008;66:1133-7.

**How to cite this article:** Akinmoladun VI, Olusanya AA, Olawole WO. Condylar disarticulation; Analysis of 20 cases from a Nigerian Tertiary Centre. *Niger J Surg* 2012;18:68-70.

**Source of Support:** Nil. **Conflict of Interest:** None declared.