

Effectiveness of More than 2-Year Treatment with Miniscleral Contact Lens in Ocular Surface Diseases: Four Case Reports

Dear Editor,

Visual acuity mostly depends on the smooth surface of the cornea, and pathologies such as irregular astigmatism, increased higher-order aberration, and corneal scars are known to decrease visual acuity. Scleral contact lenses (SCLs) can correct such abnormalities and therefore be used as a treatment option by not only optimizing optical correction in ectatic corneal disorders, but also hydrating cornea and neutralizing ocular surface in ocular surface diseases (OSDs) [1-3].

Unlike spectacles and conventional corneal rigid gas permeable (RGP) lenses, SCLs rest on the less sensitive sclera instead of the cornea, making suitable for the patient with various corneal deformities and showing successful clinical results. SCLs were manufactured using Boston XO, and the oxygen permeability was 100×10^{-11} (cm/sec) (mL O₂/mL × mmHg). Flat keratometry was used for prescription, and the one with apical clearance of 250 to 300 μm and sufficient limbal clearance measured by DRI-OCT (Topcon Corp., Tokyo, Japan) was chosen 4 hours after lens insertion. Therefore, we report four cases where it was possible to confirm therapeutic effects in various corneal abnormalities using mini-SCL, with diameters of 14.7 mm (Onefit A; Biumentec, Seoul, Korea) for a long time. Written informed consents for publication of the research details and clinical images were obtained from the patients.

A 37-year-old female patient with keratoconus presented with decreased visual acuity and discomfort despite using corneal RGP lens. On the first visit, the best-corrected visual acuity was 20 / 40 in the right eye and 20 / 32 in the

left eye. Mini-SCL with base curve radius of 7.0 mm was prescribed and standard haptic design was chosen (Fig. 1A-1F). Visual acuity was measured to be 20 / 20 in both eyes after wearing the lenses for a median of 8 hours per day. Neither were any significant adverse events of the cornea manifested during more than 2 years of follow-up period.

A 47-year-old female patient who had been diagnosed with Sjögren's syndrome and treated with therapeutic contact lenses was referred for corneal ulcer with pain in her left eye starting 3 days ago. Even after 6 months of resolution of corneal ulcer, no visual improvement was made due to corneal opacity. Mini-SCL was prescribed, using the same method from case 1 (Fig. 1G-1L). Pain was significantly relieved and visual acuity improved from hand motion to 20 / 32, wearing the lens for a median of 6 hours a day for 3 years.

A 35-year-old male patient with Stevens-Johnson syndrome presented with keratitis, despite wearing therapeutic contact lenses. His right and left visual acuity was 20 / 25 and 20 / 125, respectively. Mini-SCL was prescribed for his left eye, using the same method from case 1 (Fig. 1M-1R). Ocular pain was noticeably relieved, visual acuity improved to 20 / 25, and punctate and filamentary keratitis decreased remarkably, maintaining lens wearing time averaging to 9 hours a day for 3 years.

A 26-year-old female patient who underwent laser assisted *in situ* keratomileusis in both eyes referred for corneal ectasia in her left eye. On the first visit, her left best-corrected visual acuity was 20 / 50, and topography showed irregular corneal surface. Mini-SCL was prescribed using the same method from case 1 (Fig. 1S-1X). Left visual acuity was measured to be 20 / 20 after wearing the lens for 10 hours per day on average for 2 years with no other complications.

Recent rapid development in the manufacturing process of RGP lens has brought attention to research on contact lenses with larger diameter. Usages have been expanded for patients with various types of ocular disease. Especially, SCLs have an arch structure to minimize contact with cornea; as a result, tear reservoir is maintained, masking corneal surface irregularities, thereby improving symptoms and demonstrating therapeutic benefits in OSDs. Furthermore, SCLs provide easier centration compared to cor-

Received: March 17, 2022 Final revision: July 12, 2022
Accepted: July 18, 2022

© 2022 The Korean Ophthalmological Society

This is an Open Access journal distributed under the terms of the Creative Commons Attribution Non-Commercial License (<http://creativecommons.org/licenses/by-nc/4.0/>) which permits unrestricted non-commercial use, distribution, and reproduction in any medium, provided the original work is properly cited.

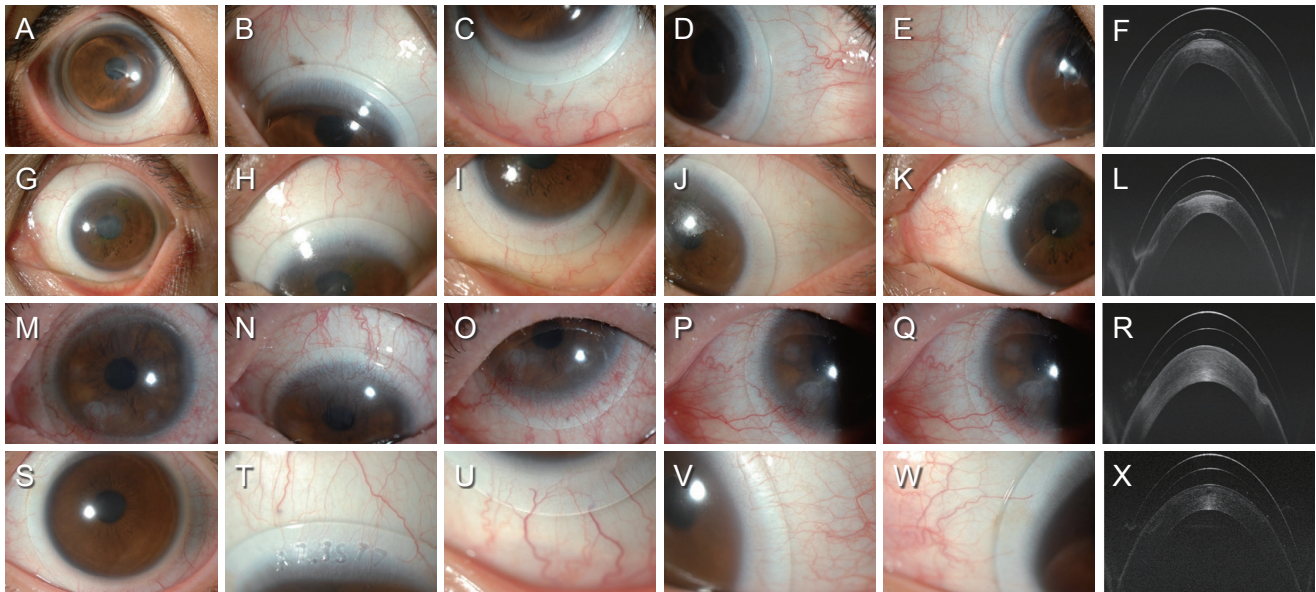


Fig. 1. Anterior segment photographs after wearing mini-scleral contact lenses (mini-SCLs). After wearing mini-SCLs, tear film between the cornea and the lens was well positioned. Limbal area was clear, and no evidence of conjunctival compression was found. The patient was told to wear the lenses for at least 4 hours before coming to the next outpatient visit, during which the photograph was taken. There were no serious adverse effects with using the contact lens. Mild injection was the problem after taking off the contact lens in most cases. However, as time went on, injection disappeared eventually and gradually. (A-E) Right eye of case 1 with keratoconus, presented with poor vision despite using corneal rigid gas permeable contact lens. Visual acuity improved to 20 / 20 after applying mini-SCL with a base curve radius of 7.0 mm and standard haptic design. (F) Anterior segment optical coherence tomography for case 1. (G-K) Left eye of case 2 with corneal opacity after corneal ulcer and Sjögren's syndrome, manifesting symptoms of ocular pain and decreased vision acuity to hand motion despite wearing conventional contact lens. Ocular pain was significantly reduced, and vision was improved to 20 / 32 after fitting mini-SCL with a base curve radius of 7.6 mm and standard haptic design. (L) Anterior segment optical coherence tomography for case 2. (M-Q) Left eye of case 3 with Stevens-Johnson syndrome, showing signs of keratitis. Mini-SCL was applied with a base curve radius of 7.30 mm and one flat haptic design. Signs of keratitis diminished remarkably, and visual acuity improvement was made as well. (R) Anterior segment optical coherence tomography for case 3. (S-W) Left eye of case 4 with corneal ectasia after laser assisted *in situ* keratomileusis referred for decreased visual acuity. Left vision improved after wearing mini-SCL with a base curve radius of 7.3 mm and one flat haptic design. (X) Anterior segment optical coherence tomography for case 4. Written informed consents for publication of the clinical images were obtained from the patients.

neal RGP lens that greatly depends on stability of the cornea [4,5]. In particular, mini-SCL is easier to prescribe due to its small diameter. While there have been several reports on the usefulness of mini-SCLs on OSD, few have dealt with a long follow-up period. In our presented four cases, patients with corneal disease that were intractable with conventional lens improved with no complications for more than 2 years. The cases presented in this study only show the results of few patients; therefore, further retrospective and prospective research on the effectiveness of SCLs on various diseases will be needed. Although indications of mini-SCLs are not established well, this study shows that mini-SCLs could be extensively used for various corneal abnormalities.

Conflicts of Interest: None.

Acknowledgements: None.

Funding: This work was supported by the National Research Foundation (NRF) grant funded by the Korean government (the Ministry of Science and ICT) (No. NRF-2020R1A2C1009975).

Min Sung Oh, Min Seung Kang, Su Hwan Park,
Ji Eun Lee

*Department of Ophthalmology, Research Institute for
Convergence of Biomedical Science and Technology, Pusan
National University Yangsan Hospital, Pusan National
University School of Medicine, Yangsan, Korea
E-mail (Ji Eun Lee): jiel75@pusan.ac.kr*

References

1. Yan P, Kapasi M, Conlon R, et al. Patient comfort and visual outcomes of mini-scleral contact lenses. *Can J Ophthalmol* 2017;52:69-73.
2. Visser ES, Visser R, van Lier HJ, Otten HM. Modern scleral lenses part I: clinical features. *Eye Contact Lens* 2007;33:13-20.
3. Visser ES, Visser R, van Lier HJJV, Otten HM. Modern scleral lenses part II: patient satisfaction. *Eye Contact Lens* 2007;33:21-5.
4. Montalt JC, Porcar E, Espana-Gregori E, Peris-Martínez C. Visual quality with corneo-scleral contact lenses for keratoconus management. *Cont Lens Anterior Eye* 2018;41:351-6.
5. Lee SM, Kim YJ, Choi SH, et al. Long-term effect of corneoscleral contact lenses on refractory ocular surface diseases. *Cont Lens Anterior Eye* 2019;42:399-405.