

Transrectal drainage of pelvic collections: Experience of a single center

Jean-Philippe Ratone, Julie Bertrand, Sébastien Godat¹, Jean-Paul Bernard, Laurent Heyries

Hôpital de la Conception, Gastroenterology Unit, Marseille, France, ¹Centre Hospitalo-Universitaire Du Vaudois, Endoscopic Unit, Lausanne, Switzerland

ABSTRACT

Background and Objective: Pelvic abscesses are a well-known complication of intestinal diseases or abdominal surgery. We report our case series concerning transrectal drainage by endoscopic ultrasound (EUS). **Methods:** Between January 2010 and august 2014, seven patients received transrectal drainage by endoscopic ultrasound (EUS) were selected and analyzed. **Results:** Two pigtailed catheters were positioned under fluoroscopic and EUS control. The success rate was 100% and complication rate was 0%. The median time of hospitalization was 10 days [range 4-25]. **Conclusions:** The technique appears to be safe and feasible in all etiologies. In our experience, we can considerate transrectal drainage by EUS like a first-line technique in experienced hands.

Key words: Pelvic abscesses, transrectal drainage, therapeutic EUS

INTRODUCTION

Pelvic abscess is a well-known complication of intestinal diseases or abdominal surgery. Radiological drainage and surgery are usual treatments for these complications.^[1-3] Therapeutic transrectal or transcolonic drainages with endosonography ((endoscopic ultrasound) EUS) are now considered as a mini-invasive option for the treatment of pelvic abscesses.^[4] The aim of our case series is to confirm that EUS transrectal drainage is effective, safe, and induces a short duration of hospitalization.

MATERIALS AND METHODS

We did a single-center retrospective analysis of seven patients with pelvic abscess treated by EUS transrectal

drainage between January 2010 and August 2014. There were four men and three women, with a median age of 50 years (range 22-68). All patients underwent abdominopelvic computed tomography (CT) before drainage. Colon preparation was achieved by administration of polyethyleneglycol or rectal enemas. A concomitant intravenous antibiotic treatment was always administered before EUS and for a minimum of 7 days after drainage. A new evaluation by CT was performed between 1 and 2 months after drainage. Pigtailed catheters were removed only if CT evaluation showed flattening of the abscess. The method of drainage was done with a linear interventional echoendoscope (PENTAX®) (EG 3870UTK PENTAX-HITACHI™, Hamburg, Germany). EUS-Doppler evaluation was first performed to exclude the presence of intercalated blood vessels before puncture with a 19-Gauge access needle (Cook) (19 G, EchoTip Access Needle, Cook™ Ireland Ltd., Limerick, Ireland). The puncture tract was then enlarged with a 10 French diathermic cystostomy over a tetrafluoroethylene (TFE)-coated 0.035-inch guidewire (Cook Endoscopy®, Winston-Salem, NC, USA). A second guidewire was then put into the cavity,

Access this article online	
Quick Response Code: 	Website: www.eusjournal.com
	DOI: 10.4103/2303-9027.180474

Address for correspondence

Dr. Jean-Philippe Ratone, Hôpital de la Conception Gastroenterology Unit, 147 Bd Baille, 13005, Marseille, France.

E-mail: jpratone@gmail.com

Received: 2015-01-19; Accepted: 2015-02-26

and two 7 French double pigtail plastic stents were positioned (4 or 7 cm length).

RESULTS

EUS drainages were done for a majority of abscesses post surgery ($n = 5/7$). The treatment was feasible and effective in 100% of cases [Figures 1-7], without supplementary radiological or surgical intervention [Table 1]. The median time of hospitalization was 10 days (range 4-25 days). The main difficulty related to this technique is the positioning of the double pigtail plastic stents, induced by pus outflow that can reduce the endoscopic visibility. Spontaneous migration of one stent happened postoperatory for some patients. However, the drainage still efficient in these cases without any adverse events. Two of our patients were embarrassed by the length of the double pigtail plastic stents which protruded in the anal canal.

DISCUSSION

Since 2003, EUS pelvic abscesses drainage is performed; given the proximity between the rectal lumen and the abscess,^[4-8] with a mini-invasive technique compare to radiological or surgical drainage. Moreover, percutaneous drainage may be difficult to realize and uncomfortable, especially if the collection is in deep location which needs a posterior drainage.^[2,3,8] Our case series show identical results compared to the current literature. Our technique is safe, without adverse events observed; and is actually well standardized, in analogy with 10 years of practice for EUS drainage of pancreatic pseudocysts. The use of the fluoroscopy and cystostomy facilitates the procedure and can be easily used by experienced operators. The length of double pigtail plastic stents should be as short as possible, especially if drainage is done in the lower rectum, because it may cause discomfort if it touches the anal canal. We can also conceive that the length of hospital stay could be

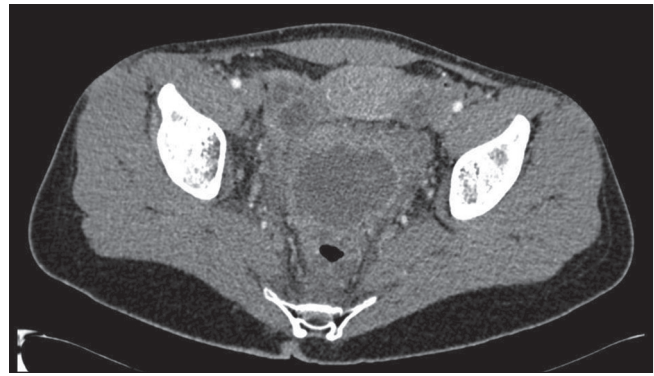


Figure 1. Pelvic abscess before drainages

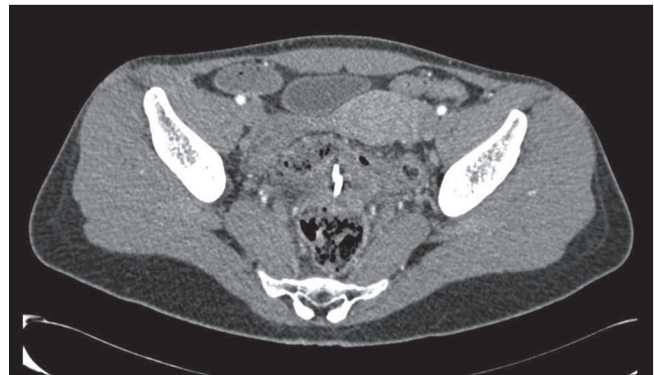

Figure 2. Pelvic abscess after drainage

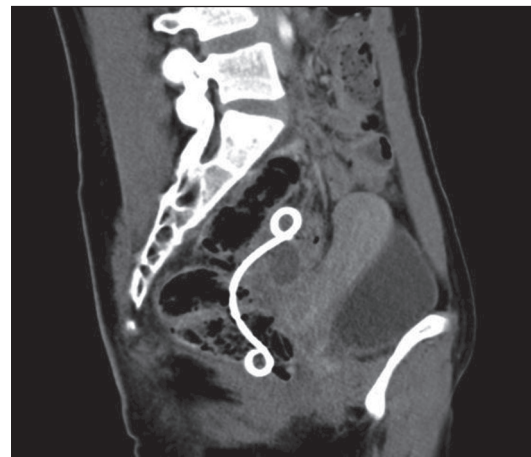

Figure 3. Sagittal view of pigtail stent in pelvic abscess

Table 1. Etiology and outcomes

No patient	Etiology	Abscess location	Abscess size (cm)	Duration hospitalization (days)	Outcome	Median follow-up (month)
1	Post Crohn surgery	Douglas	9×5	10	Success	42
2	Post appendectomy	Douglas	6×4	4	Success	3
3	Infected hematoma	Retrorectal	5×4	20	Success	8
4	Post colectomy	Douglas	10×7	10	Success	4
5	Spontaneous	Douglas	6×5	10	Success	1
6	Post biliary surgery	Douglas	6×4	25	Success	3
7	Post appendectomy	Douglas	8×5	4	Success	3

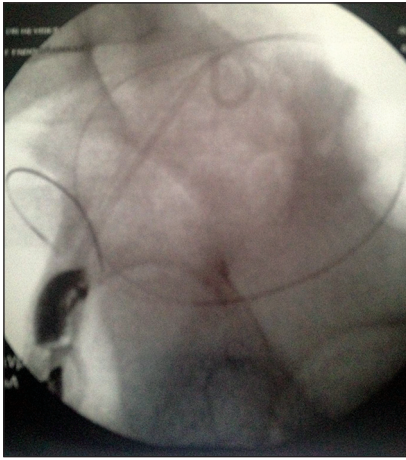


Figure 4. Fluoroscopic view of first pigtail insertion

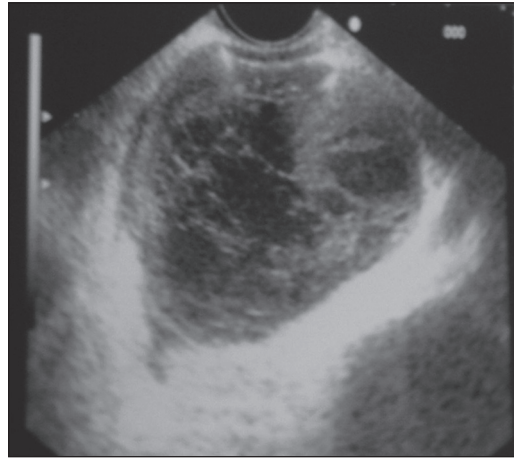


Figure 5. Endoscopic ultrasound (EUS) view of Douglas abscess

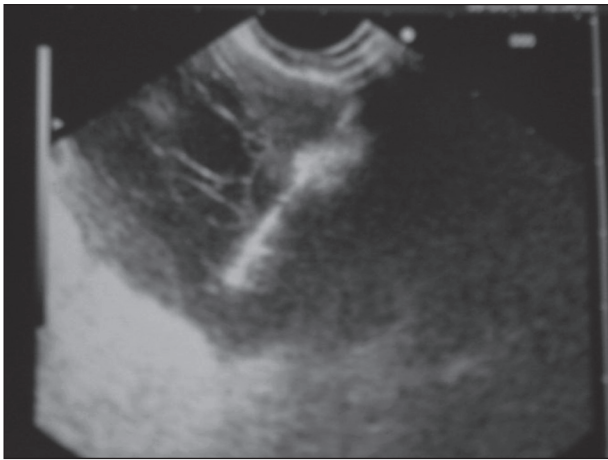


Figure 6. EUS view of abscess puncture

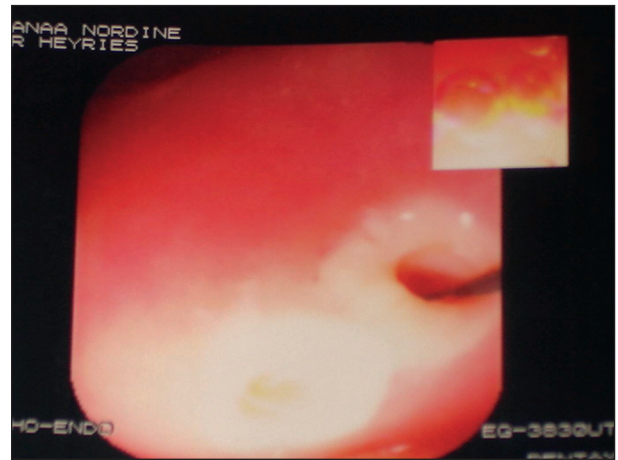


Figure 7. Endoscopic view with first guidewire insertion

further reduced if the antibiotic treatment is continued orally in selected patients.

CONCLUSION

EUS transrectal drainage is a safe and an efficient method for therapeutical treatment of pelvic abscess. In our experience, we recommend EUS transrectal drainage for pelvic abscess as the first-line technique for experienced hands.

REFERENCES

1. Sudakoff GS, Lundeen SJ, Otterson MF. Transrectal and transvaginal sonographic intervention of infected pelvic fluid collections: A complete approach. *Ultrasound Q* 2005;21:175-85.
2. Jaffe TA, Nelson RC, DeLong DM, et al. Practice patterns in percutaneous image-guided intraabdominal abscess drainage: Survey of academic and private practice centers. *Radiology* 2004;233:750-6.

3. Harisinghani MG, Gervais DA, Maher MM, et al. Transgluteal approach for percutaneous drainage of deep pelvic abscesses: 154 cases. *Radiology* 2003;228:701-5.
4. Giovannini M, Moutardier V, Pesenti C, et al. Endoscopic ultrasound-guided bilioduodenal anastomosis: A new technique for biliary drainage. *Endoscopy* 2001;33:898-900.
5. Varadarajulu S, Drelichman ER. Effectiveness of EUS in drainage of pelvic abscesses in 25 consecutive patients (with video). *Gastrointest Endosc* 2009;70:1121-7.
6. Giovannini M, Bories E, Moutardier V, et al. Drainage of deep pelvic abscesses using therapeutic echo endoscopy. *Endoscopy* 2003;35:511-4.
7. Piraka C, Shah RJ, Fukami N, et al. EUS-guided transesophageal, transgastric, and transcolonic drainage of intra-abdominal fluid collections and abscesses. *Gastrointest Endosc* 2009;70:786-92.
8. Puri R, Eloubeidi MA, Sud R, et al. Endoscopic ultrasound-guided drainage of pelvic abscess without fluoroscopy guidance. *J Gastroenterol Hepatol* 2010;25:1416-9.

How to cite this article: Ratone JP, Bertrand J, Godat S, Bernard JP, Heyries L. Transrectal drainage of pelvic collections: Experience of a single center. *Endosc Ultrasound* 2016;5:108-10.

Source of Support: Nil. **Conflicts of Interest:** None declared.