

Received: 2021.09.27

Accepted: 2021.11.09

Available online: 2021.11.22

Published: 2022.01.03

Psychosis-Induced Exertional Rhabdomyolysis without Acute Kidney Injury or Myoglobinuria

Authors' Contribution:

Study Design A
Data Collection B
Statistical Analysis C
Data Interpretation D
Manuscript Preparation E
Literature Search F
Funds Collection G

ABCDEF 1 **Joann M. Butkus**
ABE 2 **Mackenzie Kramer**
AE 3 **Vincent Chan**
DE 4 **Eunha Kim**

1 Sidney Kimmel Medical College, Thomas Jefferson University Hospital, Philadelphia, PA, USA
2 Department of Internal Medicine, Jefferson Abington Hospital, Abington, PA, USA
3 Department of Pulmonary, Allergy, & Critical Care Medicine, Thomas Jefferson University Hospital, Philadelphia, PA, USA
4 Department of Psychiatry, Jefferson Abington Hospital, Abington, PA, USA

Corresponding Author: Joann M. Butkus, e-mail: joann.butkus@students.jefferson.edu

Financial support: This manuscript received funding from the Thomas Jefferson University Open Access Fund for article processing fees

Conflict of interest: None declared

Patient: Male, 21-year-old
Final Diagnosis: Rhabdomyolysis
Symptoms: Myalgia • psychosis
Medication: —
Clinical Procedure: Intravenous hydration
Specialty: General and Internal Medicine

Objective: Unusual clinical course

Background: Rhabdomyolysis is a clinical syndrome that results from skeletal muscle breakdown and the release of intracellular enzymes into systemic circulation [1,2]. We present a case of non-traumatic rhabdomyolysis with transaminitis, without myoglobinuria or acute kidney injury. Cases reports of rhabdomyolysis with elevation of serum creatine kinase (hyperCKemia) in the absence of myoglobinuria or renal failure are limited in the literature.

Case Report: A 21-year-old man presented to the Emergency Department following an acute psychotic episode. One week earlier, his bloodwork had been within normal limits. Biochemical investigations on admission revealed hyperCKemia (590 000 U/L), transaminitis (AST, 628; ALT, 160), and normal creatinine (0.83), without myoglobinuria. Non-traumatic rhabdomyolysis was suspected, and the patient was treated with aggressive intravenous fluid resuscitation and transferred to Inpatient Psychiatry on day 10 of hospitalization. The complete metabolic panel was trended daily, without indication of kidney injury. The creatine kinase (CK) and liver function tests trended downward.

Conclusions: This report presents a rare case of exertional rhabdomyolysis with CK levels nearly 3000 times the upper limit of normal, without myoglobinuria or acute kidney injury. Acute kidney injury is a dangerous complication of rhabdomyolysis. Traditionally, clinicians use serum CK levels to predict the likelihood of acute kidney injury and/or renal failure in rhabdomyolysis. Ultimately, this patient was diagnosed with exertional rhabdomyolysis with hyperCKemia and transaminitis without myoglobinuria or acute kidney injury. More research is needed to elucidate the protective patient characteristics against rhabdomyolysis-associated acute kidney injury, associations between CK and myoglobinuria, and diagnostic criteria for psychosis-associated hyperCKemia.

Keywords: Acute Kidney Injury • Creatine Kinase • Myoglobinuria • Psychotic Disorders • Rhabdomyolysis

Full-text PDF: <https://www.amjcaserep.com/abstract/index/idArt/934943>



2284



4



1



20



Background

Rhabdomyolysis is a clinical syndrome that results from skeletal muscle breakdown and the release of intracellular enzymes into systemic circulation [1,2]. Causes of rhabdomyolysis include trauma, extreme exertion, ischemia, adverse effects of medication, intoxication with illicit drugs or alcohol, infections, and inherited structural or metabolic myopathies [1-3].

Rhabdomyolysis can also be multifactorial. Psychiatric patients are often considered at higher risk for rhabdomyolysis owing to the adverse effects of antipsychotic or antidepressant medications [4]. Episodes of agitation or intoxication could also contribute to the multifactorial etiology of rhabdomyolysis frequently seen in patients with psychiatric conditions. Clinically, rhabdomyolysis presents with characteristic symptoms of severe muscle pain, weakness, and dark, tea-colored urine, while consequential electrolyte imbalances can precipitate cardiac arrhythmias or arrest [1]. A serum creatinine kinase (CK) level greater than 5 times the upper limit of normal and the presence of myoglobinuria can further support the diagnosis [1,2]. However, this diagnostic CK threshold is sensitive but not specific, especially in diagnosing exertional rhabdomyolysis in athletes or military personnel owing to the significant variability in baseline CK levels in these populations [5]. Acute kidney injury is the most serious complication of rhabdomyolysis and represents 7% to 10% of all cases of acute kidney injury in the United States, whereas incidence reports of acute kidney injury in rhabdomyolysis range from 13% to 50% [2]. The mortality rate of rhabdomyolysis-associated acute kidney injury varies greatly with comorbidities, but most patients diagnosed with rhabdomyolysis-associated acute kidney injury recover renal function [2].

In this report, we present a case in which a young man presented with extremely elevated serum CK and transaminitis after an acute psychotic episode. The patient was diagnosed with exertional rhabdomyolysis. CK levels reached 590 000 U/L, without myoglobinuria or subsequent acute kidney injury. Case reports regarding such extreme CK elevations without myoglobinuria or ensuing renal failure in rhabdomyolysis are rare.

Case Report

A 21-year-old man with a past medical history of depression, post-traumatic stress disorder, and auditory hallucinations presented to the Emergency Department following an acute psychotic episode with suicidal and homicidal ideation. The patient also reported myalgias, which he attributed to extensive daily exercise and gym workouts. Biochemical investigations on admission revealed extremely elevated CK levels (590 000 U/L), transaminitis (AST=628 U/L; ALT=160 U/L), normal

Table 1. Normal complete metabolic panel 1 week prior to admission.

Na	141
K	4.0
Cl	104
CO ₂	27
Protein	7.1
Albumin	4.8
Ca	9.5
BUN	15
Cr	1.04
Total bilirubin	0.5
ALP	33
AST	22
ALT	16
eGFR	>60

Table 2. Urinalysis on admission day 0.

Color	Yellow
Appearance	Clear
Glucose	1+
Bilirubin	Negative
Ketones	Negative
Specific Gravity	1.005
Blood	Negative
pH	8.0
Urobilinogen	Normal
Protein	Negative
Nitrite	Negative
Leukocyte	Negative
Myoglobin	Negative

creatinine (0.83 mg/dL), and normal urinalysis. One week prior, the patient had normal laboratory values on discharge from Inpatient Psychiatry, as shown in **Table 1**. The urinalysis results from admission are shown in **Table 2**. Notably, there was no evidence of myoglobinuria, and subsequent urine myoglobin analyses were negative. The patient's home medications included citalopram, clonazepam, and 5000 mg daily of a glutathione supplement, which he purchased online. Citalopram and clonazepam were discontinued on admission out of concern for hepatotoxicity, and the initial CK level was confirmed by laboratory dilution studies. Fluid resuscitation with a 1-L lactated ringer bolus followed by continuous infusion was started immediately, and repeat CK samples were drawn. Repeat CK

Table 3. Additional laboratory workup for transaminitis and non-traumatic rhabdomyolysis.

High sensitivity troponin	Negative
EBV	Negative
CMV IgM Antibody	Negative
CMV IgG Antibody	Positive
Cystatin C	Negative
Influenza A/B, Covid-19	Negative
ANA	Negative
Blood cultures	Negative
Urine drug screen	Negative
Serum drug screen	Negative
Hepatitis panel	Negative
TSH	1.55

levels remained extremely elevated (>42 670 U/L), so another 1-L bolus followed by continuous infusion of lactated ringler solution was administered. Lactated ringler solution was administered continuously at 250 cc/h for the first 4 days of hospitalization before being slowed to a rate of 125 cc/h until CK levels normalized. The patient remained stable, and urine output and the complete metabolic panel were monitored.

There was concern for neuroleptic malignant syndrome given the patient's home medications, myalgias, and mental status change. However, he remained afebrile, lacked rigidity, and had no evidence of acute kidney injury, which effectively ruled out the diagnosis. Therefore, alternative diagnoses for the patient's transaminitis were investigated throughout admission. Ultrasound of the right upper quadrant showed no liver disease, and urine and serum drug screening were negative. A hepatitis panel was non-reactive. A decreased serum ceruloplasmin (15 mg/dL) in the setting of mental status change prompted an additional workup for Wilson's disease.

Table 4. Daily laboratory investigation.

Admission day	Serum CK (U/L)	AST (U/L) normal: 5-40	ALT (U/L) normal: 7-56	Serum Cr (mg/dL)
0	590,000*	628	160	0.83
1	>42,670	660	188	0.72
2	>42,670	642	210	0.71
3	>42,670	582	246	0.71
4	33,626	409	262	0.78
5	17,494	314	330	0.74
6	6,959	471	706	0.71
7	2,899	469	953	0.72
8	1,487	420	936	0.75
9	799	517	1112	0.74
10	339	446	1111	0.83
11	–	259	855	0.79
12	–	247	847	0.78
13	–	191	675	0.84
14	–	101	492	0.85
15	–	66	375	0.77
16	–	60	326	–
17	–	41	252	–
18	–	46	230	–
19	–	52	182	–
20	–	57	176	–
21	–	38	125	–
22	–	42	126	–

* Confirmed by laboratory dilution studies.

However, a 24-h urine collection revealed low copper excretion, and Keyser-Flescher rings were absent on slit-lamp exam, which did not support the diagnosis. An additional laboratory workup for possible etiologies is displayed in **Table 3**. The patient's transaminitis trended downward with fluid resuscitation and was attributed to effects from his rhabdomyolysis. The patient remained afebrile throughout the admission and did not require any medications for pain.

However, the patient's CK remained >42 670 U/L for 4 days despite aggressive fluid resuscitation. Urine output was monitored, and the complete metabolic panel was trended daily with no evidence of acute kidney injury, defined as an increase in serum creatinine by ≥ 0.3 mg/dL within 48 h, an increase in serum creatinine ≥ 1.5 times baseline, or urine output <0.5 mL/kg/h for 6 h [6]. Daily laboratory values are shown in **Table 4**. Notably, serum creatinine remained near the patient's baseline and serum electrolytes remained within normal limits. Additionally, no myoglobinuria was observed throughout the admission. On day 10 of hospitalization, the patient was transferred to Inpatient Psychiatry due to auditory hallucinations, which began after a personal assault 6 years prior. He was advised to follow-up with gastroenterology for monitoring of transaminitis and further workup for Wilson's disease. Close follow-up with the Psychiatry Department was also recommended.

Discussion

This report presents a rare case of exertional rhabdomyolysis with CK levels exceeding 2950 times the upper limit of normal, without myoglobinuria or acute kidney injury. Despite the lack of myoglobinuria, the diagnosis was made based on the patient's history, myalgias, and laboratory results.

Although the initial cause of muscle damage in rhabdomyolysis can vary, the pathophysiology that results in rhabdomyolysis is consistent, regardless of etiology. Skeletal muscle damage can occur primarily from direct injury or secondarily from metabolic derangement, adverse effects of medication, and intoxication. Cell damage allows ionized calcium to enter muscle cells, which activates proteases and apoptosis pathways that ultimately produce reactive oxygen species that cause cell lysis [1-3]. Massive release of intracellular electrolytes and enzymes into systemic circulation perpetuates this cycle of cell damage and death and can cause systemic complications [1-3]. Acute kidney injury is a common and dangerous complication of rhabdomyolysis, and the incidence of acute kidney injury in rhabdomyolysis ranges from 13% to 50% [2]. Rhabdomyolysis-associated acute kidney injury is the culmination of different mechanisms, such as hypovolemia, myoglobinuria, and metabolic acidosis [1,3]. Muscle damage can cause inflammation and subsequent extravasation of intravascular fluid, resulting

in functional hypovolemia and decreased renal blood flow [1,3]. Additionally, the release of myoglobin from damaged skeletal muscle is directly nephrotoxic, and the iron released from myoglobin catabolism can undergo the Fenton reaction within the kidney to produce reactive oxygen species that further damage nephrons [1]. Finally, the release of uric acid from lysed skeletal muscle contributes to metabolic acidosis and the deposition of urate crystals within the kidney, causing renal tubular obstruction and metabolic derangement [1].

Traditionally, serum CK levels have been used to predict the likelihood of acute kidney injury, renal failure, and/or the need for hemodialysis in patients presenting with rhabdomyolysis, and there are many reports that endorse a correlation between serum CK levels and kidney injury in rhabdomyolysis [1,3,7-13]. Notably, El-Abdellati et al, conducted a retrospective review of 1769 intensive care unit (ICU) patients to investigate CK, serum myoglobin, and urinary myoglobin as markers for acute kidney injury and found that the best cutoff value for acute kidney injury prediction was CK >773 U/L [13]. Meijer et al conducted an observational cohort study of ICU patients and reported that 65% (n=17) of patients developed renal failure in a cohort of patients with severe rhabdomyolysis and CK levels >10 000 U/L, with a mean serum CK of approximately 40 000 U/L on admission [12]. Finally, Luckoor et al presented a case report in which a 36-year-old man was diagnosed with massive rhabdomyolysis and CK levels comparable to those reported in our case (>700 000 U/L), which resulted in acute renal failure, severe electrolyte abnormalities, acid-base disturbances, and a prolonged hospital stay [14]. The results of additional studies have suggested that extremely elevated CK levels are not limited to ICU patients. For instance, Desayes et al described the case of a 25-year-old man treated with atypical antipsychotics who developed rhabdomyolysis with serum CK of 43 950 U/L and creatinine of 392 μ mol/L on admission, with ensuing acute renal failure requiring dialysis. The patient also developed deep-vein thrombosis that was attributed to the antipsychotic treatment [15]. Moreover, Runnstrom et al reported a case of acute influenza infection causing severe rhabdomyolysis with acute renal failure in a 29-year-old man. The CK level on admission was 3043 U/L and continued to increase to 34 176 U/L, despite aggressive hydration, while the serum creatinine normalized from 8.48 on admission [16]. Overall, there is a significant amount of literature to suggest that extreme elevations in CK result in acute kidney injury and/or renal failure.

However, there is an isolated case report by Hansrivijit et al in which extremely elevated creatinine kinase levels were detected without ensuing acute kidney injury. In their case report, serum CK levels exceeded 150 000 U/L in a patient with rhabdomyolysis with myoglobinuria attributed to marijuana or a nonspecific viral illness. The authors reported that the

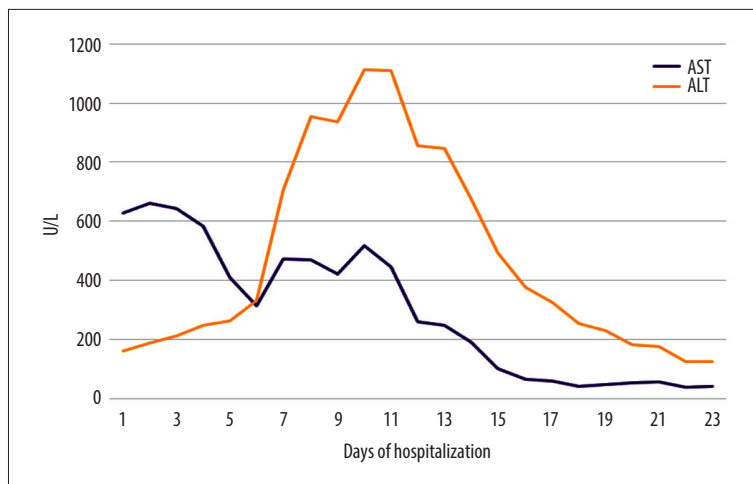


Figure 1. Trend of liver function tests.

lack of acute kidney injury in this patient suggested that preserved kidney function is possible in the setting of extreme CK elevation in patients with protective factors, such as young age and adequate oral fluid hydration [17]. This report is similar to our case in that extremely elevated CK levels did not result in acute kidney injury, but our case is unique in that myoglobinuria was absent. One prospective study conducted by Hermesh et al described the lack of myoglobinuria in patients with acute psychosis with CK levels exceeding 1000 U/L. The authors suggested a dissociation between increased serum CK and myoglobinuria and that psychosis-associated hyperCKemia may be related to an unknown, non-traumatic mechanism [18]. While the above study included the absence of myoglobinuria patients with psychiatric conditions similar to those in our patient, the maximal CK level in our report (590 000 U/L) was nearly 30 times higher than the greatest maximal CK level reported in the above study (21 000 U/L). Therefore, it is difficult to attribute our patient's presentation solely to psychosis-associated hyperCKemia without concomitant exertional rhabdomyolysis. Our patient's rhabdomyolysis was likely multifactorial, resulting from extreme exertion from exercise, the psychotic episode, and the physical contact used to contain him during the episode. Citalopram may have also increased his risk for rhabdomyolysis [4]. His home clonazepam and glutathione supplementation likely had negligible contributions, although the adverse effects of such high doses of glutathione supplementation are unclear.

Finally, our patient's transaminitis was attributed to acute skeletal muscle injury from rhabdomyolysis. The trends in the patient's liver function tests are shown in **Figure 1**. While elevations in alanine aminotransferase (ALT) and aspartate aminotransferase (AST) are usually associated with primary liver pathology, reports suggest that ALT and AST can be elevated in patients with acute skeletal muscle injury without evidence of liver disease [19]. In these cases, myoglobinuria and transaminitis occurred, and the AST/ALT ratio was greater than 3

acutely and approached 1 after several days due to the faster decline of AST [19]. In report by Nathwani et al, the laboratory values of patients who underwent extreme exercise were comparable in magnitude to those seen in our patient, with initial CPK levels ranging from 37 300 to 392 890 IU/L, AST ranging from 421 to 3967 IU/L, ALT ranging from 115 to 712 IU/L, and an AST/ALT ratio of 3.6 to 5.6 [19]. While our patient's initial CK level was 590 000 U/L, the initial AST (628 U/L), ALT (160 U/L), and AST/ALT ratio of 3.9 were within the range of reported laboratory values. This supports our diagnosis of non-traumatic rhabdomyolysis secondary to extreme muscular exertion. Moreover, we believe that the trends in AST and ALT seen in our patient were due to a robust increase in CK and AST from the initial skeletal muscle damage [20]. As CK and AST levels trended down due to faster clearance rates, ALT levels transiently rose from secondary liver injury due to the massive amounts of intracellular enzymes, electrolytes, and reactive oxygen species that were produced from the rhabdomyolysis. Lim et al reported a very similar trend in laboratory values in a 25-year-old man admitted to the hospital with exertional rhabdomyolysis that was managed with intravenous normal saline for 48 h [20].

Ultimately, our patient was diagnosed with exertional rhabdomyolysis with extreme hyperCKemia and transaminitis without myoglobinuria or acute kidney injury. More research is needed to elucidate protective patient characteristics against rhabdomyolysis-associated acute kidney injury, the association between elevated CK and myoglobinuria, and diagnostic criteria for exertional rhabdomyolysis versus psychosis-associated hyperCKemia.

Conclusions

Elevated CK levels can cause acute kidney injury in patients with rhabdomyolysis and is frequently used as a predictor of

renal injury. However, our findings suggest that preserved renal function is possible in rhabdomyolysis in young, otherwise healthy individuals despite extremely elevated CK levels. Furthermore, our findings suggest that there could be a dissociation between extreme CK levels and myoglobinuria. Ultimately, more robust diagnostic criteria for exertional rhabdomyolysis versus psychosis-associated hyperCKemia would be helpful for clinicians to better diagnose and treat patients who present with an unclear clinical picture. Additionally, more research is needed to investigate the pathophysiology of psychosis-associated hyperCKemia in the absence of myoglobinuria to better understand our findings.

References:

1. Chavez LO, Leon M, Einav S, Varon J. Beyond muscle destruction: A systematic review of rhabdomyolysis for clinical practice. *Crit Care*. 2016;20:135
2. Bosch X, Poch E, Grau JM. Rhabdomyolysis and acute kidney injury. *N Engl J Med*. 2009;361:62-72
3. Torres PA, Helmstetter JA, Kaye AM, Kaye AD. Rhabdomyolysis: Pathogenesis, diagnosis, and treatment. *Ochsner J*. 2015;15:58-69
4. Zimmerman JL, Shen MC. Rhabdomyolysis. *Chest*. 2013;144:1058-65
5. Nye NS, Kasper K, Madsen CM, et al. Clinical practice guidelines for exertional rhabdomyolysis: A military medicine perspective. *Curr Sports Med Rep*. 2021;20:169-78
6. Kellum JA. Diagnostic criteria for acute kidney injury: Present and future. *Crit Care Clin*. 2015;31:621-32
7. Baeza-Trinidad R, Brea-Hernando A, Morera-Rodriguez S, et al. Creatinine as predictor value of mortality and acute kidney injury in rhabdomyolysis. *Intern Med J*. 2015;45:1173-78
8. Fernandez WG, Hung O, Bruno GR, et al. Factors predictive of acute renal failure and need for hemodialysis among ED patients with rhabdomyolysis. *Am J Emerg Med*. 2005;23:1-7
9. Safari S, Yousefifard M, Hashemi B, et al. The value of serum creatinine kinase in predicting the risk of rhabdomyolysis-induced acute kidney injury: A systematic review and meta-analysis. *Clin Exp Nephro*. 2016;20:153-61
10. Veenstra J, Smit WM, Krediet RT, Arisz L. Relationship between elevated creatine phosphokinase and the clinical spectrum of rhabdomyolysis. *Nephrol Dialysis Transplantation* 1994;9:637-41
11. Nielsen FE, Cordtz JJ, Rasmussen TB, Christiansen CF. The association between rhabdomyolysis, kidney injury, renal replacement therapy, and mortality. *Clin Epidemiol*. 2020;12:989-95
12. de Meijer AR, Fikkers BG, de Keijzer MH, et al. Serum creatine kinase as predictor of clinical course in rhabdomyolysis: A 5-year intensive care survey. *Intens Care Med*. 2003;29:1121-25
13. El-Abdellati E, Eyselbergs M, Sirimis H, et al. An observational study on rhabdomyolysis in the intensive care unit. Exploring its risk factors and main complication: Acute kidney injury. *Ann Intensive Care*. 2013;3:8
14. Luckoor P, Salehi M, Kunadu A. Exceptionally high creatine kinase (CK) levels in multicausal and complicated rhabdomyolysis: A case report. *Am J Case Rep*. 2017;18:746-49
15. Desayes J, Roselli A, Lamy C, et al. Rhabdomyolysis with acute renal failure and deep vein thrombosis induced by antipsychotic drugs: A case report. *Pharmacopsychiatry*. 2015;48:265-67
16. Runnstrom M, Ebied AM, Khoury AP, Reddy R. Influenza-induced rhabdomyolysis. *BMJ Case Rep*. 2018;11:e226610
17. Hansrivijit P, Yarlagadda K, Puthenpura MM, Cunningham JM. Extremely high creatine kinase activity in rhabdomyolysis without acute kidney injury. *Am J Case Rep*. 2020;21:e934347
18. Hermesh H, Manor I, Shiloh R, et al. Absence of myoglobinuria in acute psychotic patients with marked elevation in serum creatine phosphokinase level. *Euro Neuropsych*. 2001;11:111-15
19. Nathwani RA, Pais S, Reynold TB, Kaplowitz N. Serum alanine aminotransferase in skeletal muscle diseases. *Hepatology*. 2005;41:380-82
20. Lim AKH. Abnormal liver function tests associated with severe rhabdomyolysis. *World J Gastroenterol*. 2020;26:1020-28

Acknowledgements

We would like to thank our patient for giving consent for the production of this case report. Publication was made possible in part by support from the Thomas Jefferson University Open Access Fund.

Declaration of Figures' Authenticity

All figures submitted have been created by the authors who confirm that the images are original with no duplication and have not been previously published in whole or in part.