



Alternating pattern of rhino-orbital–cerebral mucormycosis with COVID-19 in diabetic patients

Caglar Eker¹ · Ozgur Tarkan¹ · Ozgur Surmelioglu¹ · Muhammed Dagkiran¹ · Ilda Tanrisever¹ · Sevinc Puren Yucel Karakaya² · Burak Ulas³ · Elvan Onan¹ · Aysun Hatice Uguz⁴ · Suleyman Ozdemir¹

Received: 28 April 2022 / Accepted: 21 June 2022

© The Author(s), under exclusive licence to Springer-Verlag GmbH Germany, part of Springer Nature 2022

Abstract

Purpose Our aim was to analyze the patients with diabetic rhino-orbital–cerebral mucormycosis that we have treated in our clinic in the last 5 years, and to reveal the altering conditions with COVID-19.

Materials and methods A retrospective study was conducted on 39 rhino-orbital–cerebral mucormycosis (ROCM) patients with diabetes mellitus between 2017 and 2022. The patients were divided into two groups as those associated with and not associated with COVID-19 and compared.

Results Thirty-nine diabetic patients were included in the study, with 15 (38.5%) of them being COVID-19 associated mucormycosis (CAM) group. CAM patients showed higher orbital involvement and cavernous sinus involvement ($p=0.002$ and $p=0.013$, respectively). The mortality rate in the non-COVID-19 associated mucormycosis (non-CAM) group was statistically higher in patients with intracranial and cavernous sinus involvement ($p=0.015$ and $p=0.033$, respectively). The difference between the overall survival of the CAM patients and non-CAM patients was not statistically significant ($p=0.741$).

Conclusions With COVID-19, progressive mucormycosis accompanied by orbital and intracranial involvement is observed more frequently. However, on the contrary, the mortality rate in COVID-19-associated mucormycosis is considerably lower than expected. The fact that temporary immune suppression can be ameliorated with adequate supportive treatment and liposomal amphotericin-B which can be given to patients in high doses may explain this situation. It has been attained hints that the essential factor in the treatment of COVID-19-associated ROCM is the control of the underlying disease and to be cautious in the decision of early aggressive surgery.

Keywords Rhino-orbital–cerebral mucormycosis · Orbital exenteration · COVID-19-associated mucormycosis · COVID-19 pandemic

✉ Caglar Eker
drcaglareker@gmail.com

Ozgur Tarkan
ozgur_tarkan@yahoo.com

Ozgur Surmelioglu
surmeli2004@yahoo.com

Muhammed Dagkiran
muhammeddagkiran@gmail.com

Ilda Tanrisever
ildatanrisever@gmail.com

Sevinc Puren Yucel Karakaya
sevincpurenyucel@gmail.com

Burak Ulas
drburakulas@gmail.com

Elvan Onan
uygurelvan@hotmail.com

Aysun Hatice Uguz
aysunuz@yahoo.com

Suleyman Ozdemir
drsozdemir@gmail.com

¹ Department of Otolaryngology and Head and Neck Surgery, Faculty of Medicine, Cukurova University, Campus of Balcali, Saricam, 01330 Adana, Turkey

² Department of Biostatistics, Faculty of Medicine, Cukurova University, Adana, Turkey

³ Department of Ophthalmology, Faculty of Medicine, Cukurova University, Adana, Turkey

⁴ Department of Pathology, Faculty of Medicine, Cukurova University, Adana, Turkey

Introduction

Rhino-orbital–cerebral mucormycosis (ROCM) is the most common form of mucormycosis (%39) [1]. ROCM is a rare but challenging to management infection caused by fungi of the Mucorales group. Fungal spores taken by inhalation, which is the main route of transmission, penetrate the sinonasal epithelium and vascular invasion occurs and this process continues with the formation of infarction and necrosis in the tissue. The mortality rate of ROCM is 50–60% despite treatment [2]. Treatment consists of control of the underlying disease, surgical debridement, and systemic antifungal therapy. Early diagnosis and treatment are critical because of the high mortality and surgical morbidity [3].

Severe acute respiratory syndrome coronavirus 2 (SARS-CoV-2), also known as COVID-19, first appeared in November 2019 and spread rapidly all over the world [4]. It has been manifested in a wide range from mild rhinitis to life-threatening pneumonia. While the pathophysiology of COVID-19 is being studied in all its aspects, the clinical presentation and complications of the disease, which may occur in different forms, continue to be defined. Perhaps the most important of these are secondary infections owing to existing comorbid diseases, use of immunosuppressive therapy and immune changes related to COVID-19.

Predisposing factors for the development of ROCM include uncontrolled diabetes mellitus, hematological malignancies, immunosuppression, and long-term treatment with corticosteroids [5]. Recently, we have been increasingly detecting ROCM with typical clinical presentation which we have rarely encountered before, in cases infected with or recovering from COVID-19. Especially, in COVID-19 patients with uncontrolled diabetes and severe infection are more likely to suffer from mucormycosis [6]. The main possible reason for this is the heavy doses steroids given to these patients during the treatment process. Besides weakening the immune system, steroids also cause blood sugar to rise in patients with uncontrolled diabetes and, as a result, an acidic environment that facilitates fungal growth. Moreover, immune alterations associated with COVID-19 and contamination of medical devices with mucorales for hospitalized patients are other possible predisposing causes [7].

In the literature, since the beginning of the COVID-19 pandemic, there have been several articles published on the relationship between COVID-19 and mucormycosis. However, to our knowledge, there has not been a study comparing COVID-19-associated mucormycosis with unrelated cases. Here, we present our experience with 39 cases of rhino-orbital–cerebral mucormycosis associated

and unrelated to COVID-19 with diabetes mellitus in the past 5 years. By comparing these two groups, we aim to assist clinicians about the changing disease pattern and prognosis with COVID-19.

Materials and methods

A retrospective study was conducted on all rhino-orbital mucormycosis patients with diabetes mellitus at the XXXX University Medical Faculty, between 2017 and 2022. This hospital is the only referral center for ear, nose and throat (ENT) care in southern Turkey. Patients from different parts of the region are mostly referred to this hospital for the diagnosis and treatment of ENT diseases.

Demographic data and complaints of the patients were noted and a comprehensive clinical examination was performed. Routine blood tests and chest X-ray were performed. It was questioned whether the patients who applied after the beginning of the COVID-19 pandemic had recently had the COVID-19 infection. Real-time polymerase chain reaction (RT-PCR) test was performed with nasopharyngeal swab to detect the presence of active COVID-19 infection. A biopsy of diseased tissue was taken and sent for KOH and histopathological examination. Necessary radiological examinations (computed tomography and magnetic resonance imaging covering the face, orbit and brain) were performed to determine the extent of the disease. The diagnosis of mucormycosis was made by histopathological and/or direct microscopic examination of the biopsy material. In microscopic examination fungal hyphae of mucormycosis are detected broad, non-septate and 90 degree branching forms in haematoxylin and eosin sections. Angioinvasion and necrosis were often accompanied to the fungal infection. In some cases, histochemical special tissue stains (Pas and GMS) were required for definitive diagnosis. Liposomal amphotericin-B (L-AmB) therapy was instituted at 3–5 mg/kg as soon as the presence of mucormycosis was confirmed and surgical debridement was planned. In addition, strict blood sugar control was achieved and anticoagulant therapy was added to patients with cavernous sinus involvement. Surgical exploration and debridement were performed assisted with sinus endoscopy. Surgical intervention ranged from a simple surgical debridement to maxillectomy (partial/total), orbital exenteration, and neurosurgical interventions, depending on the extent of the disease.

We included 39 patients with diabetes mellitus who were diagnosed and treated for mucormycosis in the last 5 years. Patients with malignancy, other hematological disease, immune system disorder or using immunomodulatory drugs, history of chemotherapy and radiotherapy were excluded from the study. Then, we evaluated demographic features, COVID-19 status, clinical presentation, laboratory and

imaging findings, management, outcome and mortality. As laboratory findings, blood C-reactive protein (CRP), white blood cell counts (WBC) and Hemoglobin A1c (HbA1c) levels at the admission of the patients, and orbital, intracranial, cavernous sinus, pterygopalatine and infraorbital fossa involvement were evaluated as radiological findings. Patients with active COVID-19 infection at the time of admission and a recent history of infection were evaluated as COVID-19-associated mucormycosis (CAM). Then, the patients were divided into two groups, COVID-19 associated and non-COVID-19 associated mucormycosis (non-CAM), and these two groups were compared.

Statistical analyses

Categorical variables were expressed as numbers and percentages, whereas continuous variables were summarized as mean and standard deviation and as median and minimum–maximum where appropriate. Chi-square test was used to compare categorical variables between Non-CAM and CAM groups. The normality of distribution for continuous variables was confirmed with the Kolmogorov–Smirnov test. For comparison of continuous variables between Non-CAM and CAM groups, the Student's *t* test or Mann–Whitney U test was used depending on whether the statistical hypotheses were fulfilled or not. To evaluate the correlations between measurements, Spearman Rank Correlation

Coefficient was used. For survival analysis, overall survival was calculated using Kaplan–Meier method and log rank test was performed. All analyses were performed using IBM SPSS Statistics Version 20.0 statistical software package. The statistical level of significance for all tests was considered to be 0.05.

Results

Thirty-nine diabetic patients were included in the study, with 15 (38.5%) of them being Covid-19 associated mucormycosis group. The patients' mean age was 53.4 ± 15.8 years. Histopathology results of all patients were reported as mucormycosis. Table 1 summarizes the baseline demographic, clinical characteristics and laboratory markers of the patients according to patients with and without association Covid-19. There was no statistically difference between the groups in terms of age and gender ($p > 0.05$ for both). CAM patients showed higher orbital involvement, cavernous sinus involvement ($p = 0.002$ and $p = 0.013$, respectively). Regarding laboratory results, HbA1c and WBC were not different between the two groups, while CRP was higher in the CAM patients ($p = 0.393$, $p = 0.890$ and $p < 0.001$, respectively). In the CAM group, the mean time from Covid-19 positivity to hospital admission was 30.3 ± 26.6 (median: 23.0, min: 10, max: 100) days and from the hospital admission to the

Table 1 Comparison of demographical and clinical characteristics in COVID-19 associated and non-COVID-19 associated mucormycosis patients

	Non-CAM (<i>n</i> =24)	CAM (<i>n</i> =15)	<i>p</i>
Age(years)	49.5 (33.0–88.0)	61.0 (15.0–77.0)	0.831
Gender, <i>n</i> (%)			> 0.999
Male	12 (50.0)	8 (53.3)	
Female	12 (50.0)	7 (46.7)	
Facial/soft issue involvement, <i>n</i> (%)	13 (54.2)	9 (60.0)	0.980
Palate involvement, <i>n</i> (%)	11 (45.8)	7 (46.7)	> 0.999
Orbital involvement, <i>n</i> (%)	9 (37.5)	14 (93.3)	0.002
Intracranial involvement, <i>n</i> (%)	9 (37.5)	9 (60.0)	0.298
Cavernous sinus involvement, <i>n</i> (%)	13 (54.2)	14 (93.3)	0.013
Nasal cavity involvement, <i>n</i> (%)			0.658
Unilateral	21 (87.5)	12 (80.0)	
Bilateral	3 (12.5)	3 (20.0)	
PPF involvement, <i>n</i> (%)	10 (41.7)	15 (100.0)	0.001
ITF involvement, <i>n</i> (%)	9 (37.5)	11 (73.3)	0.064
Mortality, <i>n</i> (%)	10 (41.7)	5 (33.3)	0.855
Laboratory markers			
HbA1c%	10.3 ± 2.8	10.9 ± 1.8	0.393
WBC (cells $\times 10^9/L$)	13.8 ± 8.1	14.1 ± 5.3	0.890
CRP (mg/dL)	15.5 (0.0–199.0)	137.0 (26.9–335.0)	< 0.001

Unless otherwise specified data was expressed as mean \pm standard deviation or median(min–max)

CAM COVID-19 associated mucormycosis, non-CAM non-COVID-19 associated mucormycosis, PPF pterygopalatine fossa, ITF infratemporal fossa, WBC white blood cell count, CRP C-reactive protein

event (death) occurs was 105.3 ± 67.6 (median: 108.0, min: 11, max: 195) days. No correlation was found between these two times ($r = -0.293$, $p = 0.289$).

In the CAM group, only one of the fourteen patients with orbital involvement had partial vision loss. The remaining thirteen patients had total vision loss and ophthalmoplegia. Orbital exenteration was performed in 7 of 14 patients. Exenteration could not be performed in three patients due to poor general condition and three patients not accepting the operation. Intermittent intraorbital L-AmB injection was applied to the patient with partial vision loss. While the mortality rate was 2/7 in patients who underwent orbital exenteration, it was 3/7 in those who did not. Except for one of the surviving patients whose orbit was preserved, their vision did not improve. The vision of the patient with partial vision loss improved completely. Three patients underwent neurosurgical interventions due to intracranial involvement in line with the recommendations of the neurosurgery clinic. All three of these patients survived and also did not develop any permanent neurological deficits. In the non-CAM group, all but one of those with orbital involvement had total vision loss. While the mortality rate was 3/4 in patients who underwent orbital exenteration, it was 3/5 in those who did not.

Whereas there was no improvement in vision in two of the patients who survived, improvement was observed only in the patient who had partial vision loss at the beginning.

Mortality rates were compared according to study groups in patients with involvement (Fig. 1). Accordingly, the mortality rate in the non-CAM group was statistically higher in patients with intracranial and cavernous sinus involvement (Table 2) ($p = 0.015$ and $p = 0.033$, respectively). The difference between the overall survival of the CAM patients and non-CAM patients was not statistically significant ($p = 0.741$). Figure 2 shows the corresponding Kaplan–Meier curves.

Discussion

Mucormycosis is a rare and fatal fungal infection caused by pathogens belonging to the family Mucoraceae [8, 9]. These pathogens are ubiquitous in nature and, therefore, easily acquired. Under immunosuppression conditions, it begins to proliferate in the nasal cavity and paranasal sinuses, and can invade surrounding tissues and spread to the palate, orbit, and brain, leading to death. Despite having a low incidence

Table 2 Comparison of the mortality rates according to study groups in patients with involvement

	Non-CAM	CAM	<i>p</i>
Facial soft tissue involvement ($n = 22$)	9 (69.2)	3 (33.3)	0.192
Palate involvement ($n = 18$)	2 (18.2)	2 (28.6)	> 0.999
Orbital involvement ($n = 23$)	6 (66.7)	5 (35.7)	0.214
Intracranial involvement ($n = 18$)	8 (88.9)	2 (22.2)	0.015
Cavernous sinus involvement ($n = 27$)	10 (76.9)	4 (28.6)	0.033
Nasal cavity involvement (bilateral) ($n = 6$)	2 (66.7)	3 (100.0)	> 0.999
PPF involvement ($n = 25$)	7 (70.0)	5 (33.3)	0.111
ITF involvement ($n = 20$)	7 (77.8)	4 (36.4)	0.092

Data were expressed as n (%)

Non-CAM non-COVID-19 associated mucormycosis, *CAM* COVID-19 associated mucormycosis, *PPF* pterygopalatine fossa, *ITF* infratemporal fossa

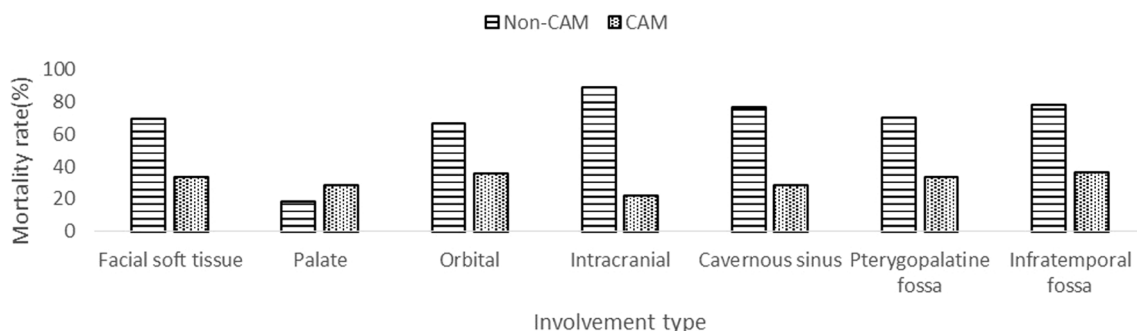


Fig. 1 Mortality rates in patients with involvement according to non-COVID-19 associated mucormycosis (Non-CAM) and COVID-19 associated mucormycosis (CAM) groups. The number of patients is

different in each involvement and the mortality rate of each involvement is given for the relevant study group

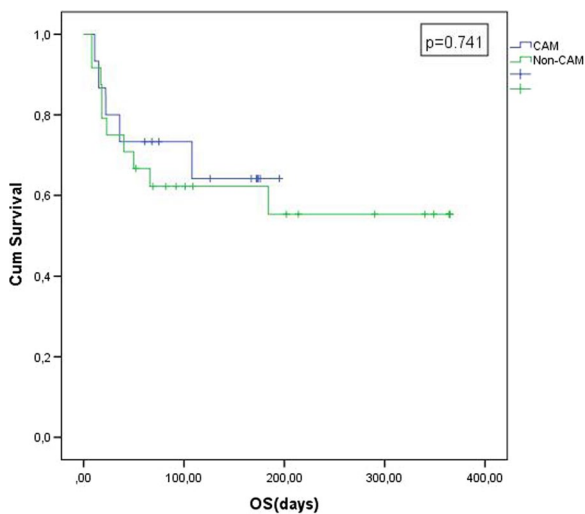


Fig. 2 Kaplan–Meier curves for the 39 patients with DM who were classified into two groups according to the post-COVID-19 status. *Cum Survival* cumulative survival, *OS* overall survival, *CAM* COVID-19 associated mucormycosis, *Non-CAM* non-COVID-19 associated mucormycosis,

rate, many cases have been seen recently, with the ongoing COVID-19 pandemic [10]. Mehta and Pandey reported a single case of rhino-orbital mucormycosis associated with COVID-19 in September 2020 [11]. Song et al. examined the relationship between COVID-19 and invasive fungal sinusitis and suggested that patients with COVID-19 were at risk for invasive fungal sinusitis [6]. Immunosuppression developed by steroid use in COVID-19 patients, immune dysregulation in the form of decreased number of T lymphocytes, decreased CD8 + T and CD4 + T cells associated with COVID-19 infection [12], emerged thrombotic microangiopathy during the COVID-19 disease process [13], impaired chemotaxis and phagocytosis of neutrophils due to persistent hyperglycemia of diabetes [14] predispose these patients to invasive fungal sinusitis.

While many case reports and articles on CAM have been published from India and east Asian countries [15–18], case reports from Europe are very limited. Anecdotal cases of CAM have been reported from France, Italy, the Netherlands and the United Kingdom [19–22]. In a multicenter study from Germany, thirteen CAM cases were reported from six tertiary care centers between March 2020 and June 2021. According to this report, pulmonary CAM was the most common clinical presentation, similar to cases reported from other European countries, in contrast to the large case series reported from India, where the vast majority of cases presented with rhino-orbital cerebral mucormycosis [23]. In the case series originating from Europe, the majority of the patients were severely critical COVID-19 patients followed in the intensive care unit, unlike the case series in India, which consisted of mild to moderate COVID-19 cases

accompanied by uncontrolled diabetes. In our clinic, we have detected a total of 86 ROCM cases in the last 5 years. While 47 of them emerged secondary to hematological and immunological diseases, chemotherapy and radiotherapy treatment, 39 patients were ROCM cases due to uncontrolled diabetes. When we review the distribution by years, the case numbers of ROCM due to diabetic and non-diabetic conditions, respectively, were 3 and 11 in 2017, 2 and 8 in 2018, 3 and 8 in 2019, 6 and 10 in 2020, 25 and 10 in 2021. Besides the fact that 22 of 25 diabetic cases in 2021 were detected in the second half of the year, 15 of these were COVID-19-associated ROCM cases. Although there was no significant change in the number of non-diabetic ROCM cases over the years, a significant increase was observed in diabetic ROCM cases with the COVID-19 pandemic in 2021. To our knowledge, CAM series from Europe demonstrate similar characteristics, and our case series is one of the limited series that differ in both quantity and case characteristics. In our study, the frequency of CAM cases was higher than Europe, and unlike Europe, it was similar to the case series in India. The cases in our series did not need intensive care unit during their COVID-19 infection. This situation can be explained by the fact that the blood sugar control of the diabetic population in Turkey is not done better than in Europe and the diagnosis of pulmonary and gastrointestinal mucormycosis is more difficult and, therefore, overlooked.

The relationship between ROCM and uncontrolled diabetes is well known [7, 24]. Moreover, COVID-19 infection and steroid therapy used in its treatment make diabetes control difficult. Accordingly, individuals with diabetes are more likely to face severe illness, complications, and opportunistic infections during their COVID-19 infection. The cumulative effect of COVID-19 infection, diabetes, and steroid use on the immune system causes immune dysregulation and creates an environment for invasive fungal infections. The fact that most of the diabetic ROCM patients who applied to our clinic recently had a history of COVID-19 infection and related steroid use supports this hypothesis. It is necessary to re-evaluate the standard steroid application in Turkey's COVID-19 infection treatment algorithm and to emphasize tight glycemic control in this patient group.

Orbital involvement generally occurs through the lamina papyracea and the roof of the maxillary sinus, while intracranial involvement is through the ethmoid, orbital veins, and optic nerve [25]. Orbital involvement incidence rates vary widely from study to study. In our study, there were differences between the two groups. Orbital involvement was present in 14 (93.3%) of 15 patients in the CAM group, and 13 of these patients had ophthalmoplegia and total vision loss. Only 9 (37.5%) of 24 patients in the non-COVID-19-related group had orbital involvement. Involvement of the orbit, cavernous sinus and pterygopalatine fossa was significantly higher in the CAM group compared to the

non-COVID-19 group. Although intracranial and infratemporal fossa involvement was higher in the CAM group, this difference was not significant. It can be considered that, in addition to diabetes, the immune dysregulation due to the COVID-19 infection itself and the effects of high-dose steroids in patients in the CAM group is deeper as a result of the cumulative effect. Fungal infection was progressing more rapidly in these patients.

It is well known that orbital and intracranial involvement are associated with higher mortality in ROCM [26]. The main principle in treatment is surgical debridement of the infected area and should be done as soon as possible after the diagnosis is confirmed. Although it is known that surgical debridement alone is not sufficient, it has been indicated to increase survival [27]. However, especially in rapidly progressing disease, even aggressive medical and surgical treatment cannot be effective and the disease may continue to progress [28]. The mortality rate in patients with intraorbital and intracranial involvement has been reported as 50–80% [29]. In our study, only 3 out of 9 patients with orbital involvement in the non-COVID-19-related group survived. The mortality rate of this group (66.7%) is in line with previous studies. On the contrary, 9 of 14 patients with orbital involvement in the CAM group survived. The mortality rate (35.7%) is below the previously reported rates. Similarly, for cavernous sinus involvement, the mortality rate was 76.9% in the non-CAM group, compared to 28.6% in the CAM group and for intracranial involvement, the mortality rate was 88.9% in the non-CAM group, compared to 22.2% in the CAM group. More frequent involvement of the orbital and intracranial regions suggests that CAM progresses more rapidly. However, considering the mortality rates, there is exactly the opposite situation. This suggests that the immune dysregulation that causes the development of CAM is a temporary disorder. Controlling dysregulation with tight blood glucose control and optimal supportive treatment may explain the better prognosis in patients with CAM. Furthermore, the fact that low-toxicity L-AmB can be given at higher doses may have contributed to this situation. According to the Global Mucormycosis Guideline published in 2019, 5–10 mg/kg L-AmB treatment per day is recommended in various organ involvements [30]. In case of intracranial involvement, the dose can be increased up to 10 mg/kg per day. Serum creatinine level increases and resistant potassium level decreases are the most important dose-limiting side effects. In our series, L-AmB treatment was administered at doses up to 10 mg/kg per day in cases with intracranial involvement. The dose was reduced in patients who developed renal toxicity. In general, the CAM group, whose general medical condition improved more rapidly through supportive care and blood glucose control, also had better medicine tolerance. Moreover, the most of the non-CAM group had long-term diabetes as well

as concomitant renal problems, and therefore, high-dose L-AmB treatment could not be possible for many patients. Hence, it has not been able to possible to clarify the role of high-dose L-AmB therapy in the observed low mortality in the CAM group. However, although we cannot explain the role of these factors in low mortality alone, there have been signs and clues that their cumulative effect is associated with low mortality rates.

Orbital exenteration is a radical and disfiguring surgery. Perhaps the most critical decision in the treatment of rhino-orbital mucormycosis is whether or not to exenter the orbit. Orbital mucormycosis corresponds not only to advanced disease, but also to a high risk for disease progress to intracranial region due to the anatomical connections directly related to this region. Therefore, in the case of rapidly progressive disease with orbital invasion, emergency exenteration may be necessary to keep the patient alive. However, recent advances in medical therapy such as low-toxicity L-AmB may allow orbital preservation in the case of slowly progressive disease [26]. Munir et al. reported that the mortality rate in patients with orbital involvement and orbital preservation was not significantly different from patients who underwent orbital exenteration [31]. In our study, we performed orbital exenteration to 7 of 14 patients with orbital involvement, because the disease progressed rapidly in patients with CAM. It could not be performed in the remaining patients because of partial vision loss in one, poor general condition in three, and refusal to accept orbital exenteration in three of them. Of these, those with poor general condition died, while the remaining four patients survived. Whereas the mortality rate of the patients we did exenteration was 2/7, it was 3/7 of those we did not. The fact that L-AmB with reduced toxicity can be given at higher doses, and the recovery of immune dysregulation due to COVID-19 and steroid use with supportive treatment may explain the lack of significant difference in mortality rates. Even with our small sample size, this result made us consider the value of prompt medical treatment with L-AmB, supportive care for the underlying disease, and a conservative approach to orbital exenteration.

The limitations of our study were that its retrospective nature, relatively small sample size and single-center. The results of our study and our clinical observation suggest that CAM shows a different pattern than non-COVID-19-related ROCM. However, some of our results did not reach statistical significance due to the low number of cases. Studies with larger sample sizes are needed.

Conclusions

Rhino-orbital cerebral mucormycosis, as it is known, is a very mortal disease. Although it is a rare disease, a significant increase in its frequency has been observed with the COVID-19 pandemic. In addition to widespread steroid use and diabetes, immune dysregulation caused by COVID-19 infection may lead to the development of mucormycosis. In parallel, we have observed a significant increase in the number of cases admitted to our clinic in the last 6 months. Most of the cases had rapidly progressive disease accompanied by orbital and intracranial involvement. While the mortality rate is 50–80% in cases of rapidly progressive disease with orbital and intracranial involvement, on the contrary, in cases associated with COVID-19 in our series, the mortality rate was significantly lower. Furthermore, in this patient group, our clinical observation is that orbital exenteration has no significant survival benefit. It has been considered that the cumulative effect of steroid use, diabetes and COVID-19 infection on the immune system causes rapidly progressive disease, but improving of the immune dysregulation with tight blood sugar control, adequate supportive treatment and liposomal amphotericin-B treatment that can be used at high doses ameliorates the course of the disease. Finally, although we have attained hints that the essential factor in the treatment is the control of the underlying disease and to be cautious about early aggressive surgical treatment, multicenter studies with larger sample sizes seem necessary.

Author contributions Concept: CE and OT; design: CE, OT, OS, and MD; supervision: OT, OS, MD, AHU, and SO; resources: CE, IT, BU, and EO; data collection and/or processing: CE, IT, and SPYK; analysis and/or interpretation: CE, OT, OS, SPYK, EO, and SO; literature search: CE, IT, SPYK, BU, EO, and AHU; writing manuscript: CE, OT, OS, MD, IT, SPYK, BU, EO, AHU, and SO; critical review: CE, OT, OS, MD, IT, SPYK, BU, EO, AHU, and SO.

Funding Our study did not receive funding support.

Declarations

Conflict of interest The authors declare that they have no conflict of interest.

Ethics committee approval The Cukurova University Faculty of Medicine Non-Invasive Clinical Research Ethics Committee.

References

- Reid G, Lynch JP 3rd, Fishbein MC, Clark NM (2020) Mucormycosis. *Semin Respir Crit Care Med* 41(1):99–114. <https://doi.org/10.1055/s-0039-3401992>
- Roden MM, Zaoutis TE, Buchanan WL et al (2005) Epidemiology and outcome of zygomycosis: a review of 929 reported cases. *Clin Infect Dis* 41(5):634–653. <https://doi.org/10.1086/432579>
- Skiada A, Lass-Floerl C, Klimko N, Ibrahim A, Roilides E, Petrikos G (2018) Challenges in the diagnosis and treatment of mucormycosis. *Med Mycol* 56(suppl_1):93–101. <https://doi.org/10.1093/mmy/myx101>
- Farnoosh G, Alishiri G, Hossseini Z Sr et al (2020) Understanding the severe acute respiratory syndrome coronavirus 2 (SARS-CoV-2) and coronavirus disease (COVID-19) based on available evidence—a narrative review. *J Mil Med* 22(1):1–11
- Petrikkos G, Skiada A, Lortholary O, Roilides E, Walsh TJ, Kontoyiannis DP (2012) Epidemiology and clinical manifestations of mucormycosis. *Clin Infect Dis* 54(Suppl 1):S23–34. <https://doi.org/10.1093/cid/cir866>
- Song G, Liang G, Liu W (2020) Fungal co-infections associated with global COVID-19 pandemic: a clinical and diagnostic perspective from China. *Mycopathologia* 185(4):599–606. <https://doi.org/10.1007/s11046-020-00462-9>
- Rammaert B, Lanternier F, Zahar JR, Dannaoui E, Bougnoux ME, Lecuit M, Lortholary O (2012) Healthcare-associated mucormycosis. *Clin Infect Dis* 54(Suppl 1):S44–54. <https://doi.org/10.1093/cid/cir867>
- Ferguson BJ (2000) Mucormycosis of the nose and paranasal sinuses. *Otolaryngol Clin N Am* 33(2):349–365. [https://doi.org/10.1016/s0030-6665\(00\)80010-9](https://doi.org/10.1016/s0030-6665(00)80010-9)
- Uçkay I, Chalandon Y, Sartoretto P, Rohner P, Berney T, Hadaya K, van Delden C (2007) Invasive zygomycosis in transplant recipients. *Clin Transplant* 21(4):577–582. <https://doi.org/10.1111/j.1399-0012.2007.00684.x>
- Werthman-Ehrenreich A (2021) Mucormycosis with orbital compartment syndrome in a patient with COVID-19. *Am J Emerg Med* 42:264.e5–264.e8. <https://doi.org/10.1016/j.ajem.2020.09.032>
- Mehta S, Pandey A (2020) Rhino-orbital mucormycosis associated with COVID-19. *Cureus* 12(9):e10726. <https://doi.org/10.7759/cureus.10726>
- Gangneux JP, Bougnoux ME, Dannaoui E, Cornet M, Zahar JR (2020) Invasive fungal diseases during COVID-19: we should be prepared. *J Mycol Med* 30(2):100971. <https://doi.org/10.1016/j.mycmed.2020.100971>
- Sweeny JM, Barouqa M, Krause GJ, Gonzalez-Lugo JD, Rahman S, Gil MR (2020) Evidence for secondary thrombotic microangiopathy in COVID-19. medRxiv Preprint. <https://doi.org/10.1101/2020.10.20.20215608>
- Balai E, Mummadi S, Jolly K, Darr A, Aldeerawi H (2020) Rhinocerebral Mucormycosis: A Ten-Year Single Centre Case Series. *Cureus* 12(11):e11776. <https://doi.org/10.7759/cureus.11776>
- Singh AK, Singh R, Joshi SR, Misra A (2021) Mucormycosis in COVID-19: a systematic review of cases reported worldwide and in India. *Diabetes Metab Syndr* 15(4):102146. <https://doi.org/10.1016/j.dsx.2021.05.019>
- Chegini Z, Didehdar M, Khoshbayan A, Rajaeih S, Salehi M, Shariati A (2020) Epidemiology, clinical features, diagnosis and treatment of cerebral mucormycosis in diabetic patients: A systematic review of case reports and case series. *Mycoses* 63(12):1264–1282. <https://doi.org/10.1111/myc.13187>
- Szarpak L, Chirico F, Pruc M, Szarpak L, Dzieciatkowski T, Rafique Z (2021) Mucormycosis—A serious threat in the

- COVID-19 pandemic? *J Infect* 83(2):237–279. <https://doi.org/10.1016/j.jinf.2021.05.015>
18. Prakash H, Ghosh AK, Rudramurthy SM et al (2019) A prospective multicenter study on mucormycosis in India: Epidemiology, diagnosis, and treatment. *Med Mycol* 57(4):395–402. <https://doi.org/10.1093/mmy/myy060>
 19. Bellanger AP, Navellou JC, Lepiller Q, Brion A, Brunel AS, Milon L, Berceanu A (2021) Mixed mold infection with *Aspergillus fumigatus* and *Rhizopus microsporus* in a severe acute respiratory syndrome Coronavirus 2 (SARS-CoV-2) patient. *Infect Dis Now* 51(7):633–635. <https://doi.org/10.1016/j.idnow.2021.01.010>
 20. Pasero D, Sanna S, Liperi C et al (2021) A challenging complication following SARS-CoV-2 infection: a case of pulmonary mucormycosis. *Infection* 49(5):1055–1060. <https://doi.org/10.1007/s15010-020-01561-x>
 21. Buil JB, van Zanten ARH, Bentvelsen RG et al (2021) Case series of four secondary mucormycosis infections in COVID-19 patients, the Netherlands, December 2020 to May 2021. *Euro Surveill* 26(23):2100510. <https://doi.org/10.2807/1560-7917.ES.2021.26.23.2100510>
 22. Hanley B, Naresh KN, Roufosse C et al (2020) Histopathological findings and viral tropism in UK patients with severe fatal COVID-19: a post-mortem study. *Lancet Microbe* 1(6):e245–e253. [https://doi.org/10.1016/S2666-5247\(20\)30115-4](https://doi.org/10.1016/S2666-5247(20)30115-4)
 23. Seidel D, Simon M, Sprute R et al (2022) Results from a national survey on COVID-19-associated mucormycosis in Germany: 13 patients from six tertiary hospitals. *Mycoses* 65(1):103–109. <https://doi.org/10.1111/myc.13379>
 24. Unnikrishnan R, Misra A (2020) Infections and diabetes: Risks and mitigation with reference to India. *Diabetes Metab Syndr* 14(6):1889–1894. <https://doi.org/10.1016/j.dsx.2020.09.022>
 25. Gamaletsou MN, Sipsas NV, Roilides E, Walsh TJ (2012) Rhino-orbital-cerebral mucormycosis. *Curr Infect Dis Rep* 14(4):423–434. <https://doi.org/10.1007/s11908-012-0272-6>
 26. Peterson KL, Wang M, Canalis RF, Abemayor E (1997) Rhino-cerebral mucormycosis: evolution of the disease and treatment options. *Laryngoscope* 107(7):855–862. <https://doi.org/10.1097/00005537-199707000-00004>
 27. Elinav H, Zimhony O, Cohen MJ, Marcovitch AL, Benenson S (2009) Rhinocerebral mucormycosis in patients without predisposing medical conditions: a review of the literature. *Clin Microbiol Infect* 15(7):693–697. <https://doi.org/10.1111/j.1469-0691.2009.02884.x>
 28. González Ballester D, González-García R, Moreno García C, Ruiz-Laza L, Monje GF (2012) Mucormycosis of the head and neck: report of five cases with different presentations. *J Cranio-maxillofac Surg* 40(7):584–591. <https://doi.org/10.1016/j.jcms.2011.10.015>
 29. Gillespie MB, O'Malley BW (2000) An algorithmic approach to the diagnosis and management of invasive fungal rhinosinusitis in the immunocompromised patient. *Otolaryngol Clin North Am* 33(2):323–334. [https://doi.org/10.1016/s0030-6665\(00\)80008-0](https://doi.org/10.1016/s0030-6665(00)80008-0)
 30. Cornely OA, Alastruey-Izquierdo A, Arenz D et al (2019) MSG Global Guideline Writing Group. Global guideline for the diagnosis and management of mucormycosis: an initiative of the European Confederation of Medical Mycology in cooperation with the Mycoses Study Group Education and Research Consortium. *Lancet Infect Dis* 19(12):e405–e421. [https://doi.org/10.1016/S1473-3099\(19\)30312-3](https://doi.org/10.1016/S1473-3099(19)30312-3)
 31. Munir N, Jones NS (2007) Rhinocerebral mucormycosis with orbital and intracranial extension: a case report and review of optimum management. *J Laryngol Otol* 121(2):192–195. <https://doi.org/10.1017/S0022215106003409>

Publisher's Note Springer Nature remains neutral with regard to jurisdictional claims in published maps and institutional affiliations.