

OPEN

A Case Report of Local Recurrence Developing 24 Years After Mastectomy for Breast Cancer Recurrence From Breast Cancer After 24 Years

Linlin Xiao, MS, Xudong Hu, MD, Suzhen Wang, MS, Gao Yong-Sheng, MS, Qingxi Yu, MS, Song Gao, MS, Hui Zhang, MS, Yuchun Wei, MS, Qian Zhao, MS, and Shuang-Hu Yuan, PhD, MD

Abstract: Introduction: Breast cancer is a commonly diagnosed cancer, in which most patients' metastases (about 75%) occurred in 5 years after the initial diagnosis, especially in 3 years. Recrudescence exceeding 20 years is rarely reported in the past several decades.

Case information: A 68-year-old female patient presented with breast cancer in which 3 focal increased 18F-fluorodeoxyglucose uptake in the right supraclavicular lymph node, the mediastinum and sternum were found on positron emission tomography and computed tomography. Then we learned that the patient had suffered from breast cancer and been given a right-sided mastectomy 24 years ago. Histopathology from the mediastinum revealed metastatic, moderately differentiated breast adenomatous cell carcinoma.

Conclusion: We report this late recurrence of breast cancer 24 years following mastectomy, suggesting that possible recurrence of this disease with a 24-year latency period should be taken into consideration.

(*Medicine* 95(22):e3807)

Abbreviations: ALDH1 = aldehyde dehydrogenase 1, CD133 = differentiation 133, CK = cytokeratin, CT = computed tomography, DFS = disease-free survival, ER = estrogen receptors, FDG = fluorodeoxyglucose, HER2 = human epidermal growth factor receptor-2, ITP = idiopathic thrombocytopenic purpura, PET = positron emission tomography, PR = progesterone receptors, STC-1 = stanniocalcin-1, STC-2 = stanniocalcin-2, SUV = standard uptake value, TSC = tumor stem cells.

INTRODUCTION

Breast cancer is a commonly diagnosed cancer and a serious threat to women's health and even life. Surgery, chemotherapy, radiotherapy, and endocrine therapy are commonly used therapeutic tools for breast cancer. Local recurrence is common in patients with breast cancer after relevant treatments. Among

Editor: Huitao Fan.

Received: February 4, 2016; revised: April 30, 2016; accepted: May 5, 2016.

From the School of Medicine and Life Sciences (L-LX, HZ, Y-CW, QZ), University of Jinan-Shandong Academy of Medical Sciences; (L-LX, X-DH, S-ZW, Y-SG, QXY, SG, HZ, Y-CW, QZ, S-HY), Shandong cancer hospital affiliated to Shandong University, Jinan, Shandong, China; and (S-HY), Shandong Academy of Medical Sciences, Jinan, Shandong, China. Correspondence: Shuang-Hu Yuan, Shandong cancer hospital affiliated to Shandong University, 440 JiYan Road, JiNan, ShanDong 250117, China (e-mail: yuanshuanghu@sina.com).

The authors have no funding and conflicts of interest to disclose.

Copyright © 2016 Wolters Kluwer Health, Inc. All rights reserved.

This is an open access article distributed under the terms of the Creative Commons Attribution-NonCommercial-ShareAlike 4.0 License, which allows others to remix, tweak, and build upon the work non-commercially, as long as the author is credited and the new creations are licensed under the identical terms.

ISSN: 0025-7974

DOI: 10.1097/MD.0000000000003807

the 5 subtypes of breast cancer, luminal A is associated with a low risk of recurrence, then the luminal B and luminal HER2, while the subtype of no-luminal HER2 and triple negative have a high risk.^{1,2} Most patients' recurrence (about 75%) occurred in 5 years after the initial diagnosis, especially in 3 years.^{3,4} Although there are a few recurrences after more than 10 years, the recrudescence exceeding 20 years is rare. Only sporadic cases have been published in the past several decades.⁵⁻⁷ Here, we report a case of a patient with recurrence after 24 years, which was confirmed by the tissue biopsy and immunohistochemistry.

CASE REPORT

A 68-year-old female patient presented herself to our outpatient oncological clinic. She presented with complaints of facial edema, palpebral edema, pectoral tightness that was aggravated by activity but reduced after rest. Breast ultrasonic examination performed: the right breast was after-surgery absence. According to requirements by her family, the patient was underwent a follow-up 18F-FDG -PET/CT scan. Three lesions of increased FDG accumulation were observed in the right supraclavicular lymph node, the mediastinum and sternum, revealing 3 focal lesions with increased FDG uptake in these regions, referred to as "mass A," "mass B," and "mass C" (Figure 1A: arrows, SUVmax = 13.8; Figure 1B: arrows, SUVmax = 15.98; Figure 1C: arrows, SUVmax = 6.1).

When asking about the patient's medical history, we learned that the patient had breast cancer 24 years ago. In 1991, the patient was admitted to the surgical department and was given a right-sided mastectomy with removal of the enlarged lymph nodes in the inferior level of the right axilla and chest-wall. Postoperative histopathological examination confirmed breast infiltrating ductal carcinoma. After operation the patient carried out 4 cycles of chemotherapy. Then she took Tamoxifen for 5 years and checked regularly every year.

A computed tomography (CT)-guided gun biopsy was taken from the lymph node (mass B) in mediastinum. Histopathology from mass B revealed nested invasive breast adenomatous cell carcinoma (Figure 2). Immunohistochemistry showed that malignant cells were strong positive for estrogen receptors (ER) and progesterone receptors (PR) (Figure 3). Staining for human epidermal growth factor receptor-2 (HER2) was moderate positive. In addition, the cells showed positive staining for CK7; although the intensity was weaker than that of ER and PR, their presence was distinct in breast cancer. Based on these pathologic findings, mass B was diagnosed as a local recurrence of breast cancer. For further studying the relationship between the recurrence and the mechanism of tumor dormancy, we carried out deeper molecular analyses on newly occurred metastases (Figure 4). Immunohistochemistry showed that staining for stanniocalcin-1 (STC-1), stanniocalcin-2 (STC-2), and

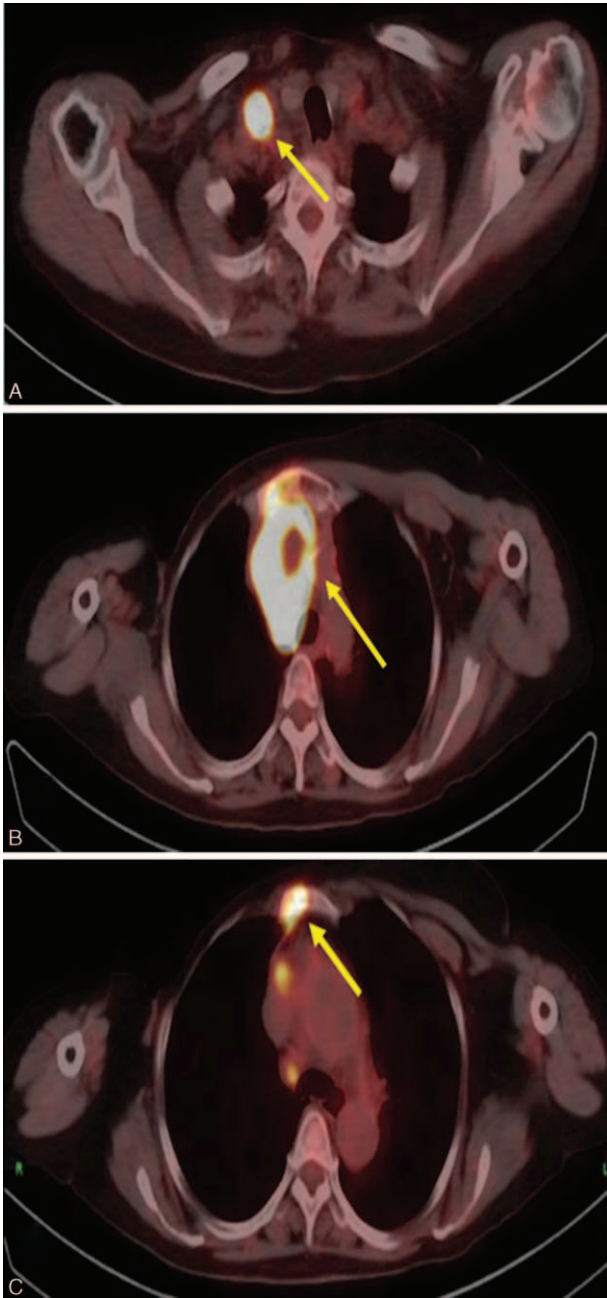


FIGURE 1. Coronal series showed 3 dense consolidation with areas of increased uptake, and these lesions were pointed by yellow arrows. A, It was mass A in the right supraclavicular lymph node. B, It was mass B in mediastinum. C, It was mass C in sternum.

differentiation 133(CD133) was positive, the aldehyde dehydrogenase 1 (ALDH1) was negative.

The patient has consented for the publication of the present case report.

DISCUSSION

Here, we report a case of breast cancer that recurred after a 24-year latency period. This late recurrence of breast cancer has

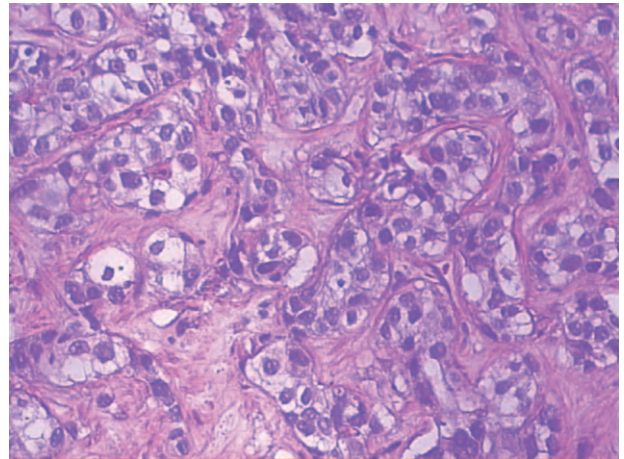


FIGURE 2. Pathological result of mediastinum was observed under a light microscope (Olympus BX51, Tokyo, Japan; hematoxylin-eosin staining, original magnification 200) and representative photos were taken. CT-guided biopsy of mass B in the mediastinum revealed nested invasive breast adenomatous cell carcinoma. CT = computed tomography.

been described historically as extremely rare. Only sporadic cases have been published in the past several decades.⁵⁻⁷ These patients had different symptoms with different metastatic sites, such as lymphedema in arm, slight dyspnea, idiopathic thrombocytopenic purpura accompanied. In this case, our patient had some symptoms: facial edema, palpebral edema, pectoral tightness. We think that all of the above symptoms were associated with the mass of lymph nodes in the supraclavicular, mediastinum, and sternum. We report this case of breast cancer with local recurrence after initial therapy 24 years later, suggesting that possible recurrence of this disease with more than a 24-year latency period should be taken into consideration.

Breast cancer is a kind of malignant tumor and a serious threat to women’s health and life. A survey of woman breast cancer statistics in the United States offered by the American Cancer Society⁸ showed that about 226,870 new cases of breast cancer and 39,510 deaths were predicted to occur among US women in 2012. In 1996, the study of Demicheli et al⁹ demonstrated that the recurrence after mastectomy appeared to be double-peaked, with the first peak at about 18 months after mastectomy and the second at about 60 months. Although tardus breast cancer metastasis could occur in 15 years after surgery, most patients’ metastases (about 75%) occurred in 5 years after the initial diagnosis, especially in 3 years. The study of Largillier et al³ showed that the median time to recurrence and metastasis was 23.1 months, and the result of Andre et al⁴ was 29 months.

The differences in the recurrence and survival of patients with breast cancer may be related to the tumor size, age, menopause status, individual biological differences, therapeutic method, and so on. Primary tumor size is an important factor affecting prognosis. Behm et al¹⁰ had found that the primary tumor that is more than 2-cm diameter has higher recurrent risk. The controversy about the influence of age on breast cancer survival still exists in current studies. Young patients represent a unique entity as they have specific issues including personal and clinical aspects, such as the much higher malignant tumors that will lead to a worse prognosis.¹¹⁻¹³ However, some researches

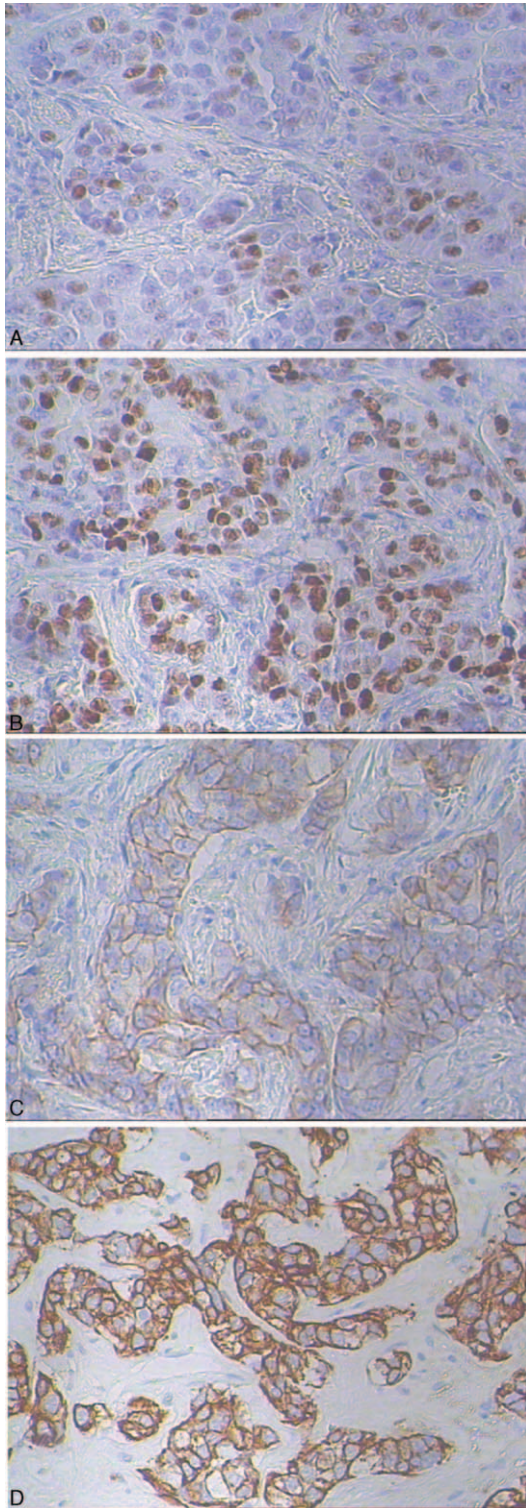


FIGURE 3. In the immunohistochemical detection of mass B in the mediastinum, PR and ER appeared strong positive in nucleus (A, B) with magnification of 200. Her2 appeared positive in cytomembrane (C) with magnification of 200. CK7 appeared positive in cytoplasm (D) with magnification of 200. CK = cytokeratin, ER = estrogen receptors, HER2 = human epidermal-growth factor receptor-2, PR = progesterone receptors.

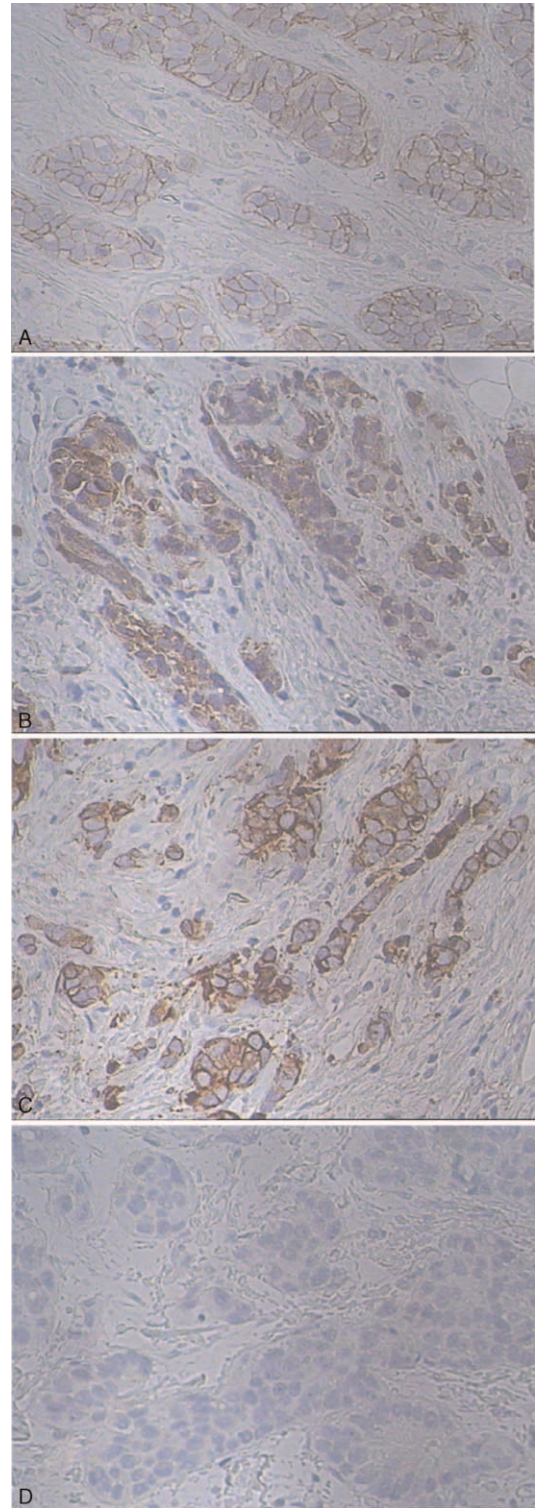


FIGURE 4. In the further immunohistochemical detection of mass B in the mediastinum, CD133 appeared positive in cytoplasm (A) with magnification of 200. STC-1 and STC-2 appeared positive in cytoplasm (B, C) with magnification of 200. ALDH1 appeared negative in cytoplasm (D) with magnification of 200. ALDH1 = aldehyde dehydrogenase 1, CD133 = differentiation 133, STC-1 = stanniocalcin-1, STC-2 = stanniocalcin-2.

showed that age is not an independent prognostic factor when comparing with characteristics and treatment of breast cancer.¹⁴ A study of Demicheli et al¹⁵ proved that among premenopausal women, the recurrence after mastectomy also appeared to be double-peaked, the first narrow peak at about 8 to 10 months after mastectomy and the second peak was at 28 to 30 months; while among postmenopausal patients, the peak appeared at about 18 to 20 months. It has been widely confirmed that adjuvant chemotherapy after surgery can effectively reduce the recurrence rate. Extension therapy by tamoxifen or aromatase inhibitor after 5 years of tamoxifen and for a total duration of 10 years significantly reduces further the risk of late recurrence and improves overall survival.¹⁶ In recent years, with the in-depth study of molecular biology, the expression of ER/PR receptor had played more and more important effect in the prognosis of breast cancer.^{17–19} The prognosis of HER2-positive and triple negative breast cancer was worse than that of Luminal subtype.

The patient had taken Tamoxifen for 5 years after the operation, Tamoxifen is considered the standard therapy for nonmenopausal female patients. Endocrine therapy is a compulsory step in the adjuvant management of early breast cancer expressing the estrogen receptor, by reducing as much as possible serum and tissue levels of estrogens. Increasing evidence²⁰ supports the use of extended endocrine therapy with tamoxifen for 5 years to reduce breast cancer recurrence and mortality, while low adherence to adjuvant endocrine therapy for women with breast cancer increases the risk of recurrence and death. We regard high adherence to adjuvant endocrine therapy may be 1 reason for our patient's long disease-free survival (DFS).

In breast cancer, upregulation of STC-1 and STC-2 expression was observed in patients who experienced later relapse and considered as the factors contributing to tumor dormancy.^{21–23} And they may be exploited as biomarkers for metastasis and targeted therapy in human breast cancer via activation of phosphoinositide 3-kinase (PI3K)/AKT or Protein Kinase C (PKC)/Claudin-1-mediated signaling pathway.^{22,23} Delayed recurrences in this case report of breast cancer are well explained by the concept of tumor dormancy. As Meng et al²⁴ reported circulating tumor cells (CTCs), which are shed from persisting tumor in patients with cancer dormancy, are present in 33% of patients who survived many years after mastectomy without disease. The phenomena of dormant tumor are also associated with tumor stem cells (TSC).²⁵ Some related studies have revealed a close association between breast cancer TSC markers, including ALDH1 and CD133, and tumor angiogenesis which is considered the leading factor to the growth and metastasis of tumors.²⁶ The persistence of stem cells may help explain why solid tumors, which were successfully eliminated after various forms of radiation and chemotherapy, almost inevitable relapse in later stage. Unfortunately, we are currently in the little understanding of the dormant cancer cells. When we know more information about the biological mechanism of that, we may have ability to explore an appropriate method to treat diseases related to dormancy, then more and more cancer patients are able to gain much longer survival.

REFERENCES

- Arvold ND, Taghian AG, Niemierko A, et al. Age, breast cancer subtype approximation, and local recurrence after breast-conserving therapy. *J Clin Oncol*. 2011;29:3885–3891.
- Shim HJ, Kim SH, Kang BJ, et al. Breast cancer recurrence according to molecular subtype. *Asian Pac J Cancer Prev*. 2014;15:5539–5544.
- Andre F, Slimane K, Bachelot T, et al. Breast cancer with synchronous metastases: trends in survival during a 14-year period. *J Clin Oncol*. 2004;22:3302–3308.
- Largillier R, Ferrero JM, Doyen J, et al. Prognostic factors in 1,038 women with metastatic breast cancer. *Ann Oncol*. 2008;19:2012–2019.
- Kusama M, Kaise H, Nakayama S, et al. [A case of postoperative lung and pleural recurrence after 20 years in a breast cancer patient with marked response to orally administered UFT and cyclophosphamide]. *Gan To Kagaku Ryoho*. 2000;27: 1573–1576.
- Igarashi T, Itoh K, Fujii H, et al. Successful treatment by radiation and hormone therapy of isolated local recurrence of breast cancer 24 years after mastectomy accompanied by immune thrombocytopenia: a case report. *Jpn J Clin Oncol*. 1998;28:270–275.
- Tashima Y, Kawano K. [A case of local recurrence developing thirty-nine years after mastectomy for breast cancer]. *Gan To Kagaku Ryoho*. 2014;41:357–359.
- Siegel R, Naishadham D, Jemal A. Cancer statistics, 2012. *CA Cancer J Clin*. 2012;62:10–29.
- Demicheli R, Abbattista A, Miceli R, et al. Time distribution of the recurrence risk for breast cancer patients undergoing mastectomy: further support about the concept of tumor dormancy. *Breast Cancer Res Treat*. 1996;41:177–185.
- Behm EC, Beckmann KR, Dahlstrom JE, et al. Surgical margins and risk of locoregional recurrence in invasive breast cancer: an analysis of 10-year data from the Breast Cancer Treatment Quality Assurance Project. *Breast*. 2013;22:839–844.
- Cancello G, Maisonneuve P, Mazza M, et al. Pathological features and survival outcomes of very young patients with early breast cancer: how much is “very young”. *Breast*. 2013;22:1046–1051.
- Azim HA, Michiels S, Bedard PL, et al. Elucidating prognosis and biology of breast cancer arising in young women using gene expression profiling. *Clin Cancer Res*. 2012;18:1341–1351.
- Collins LC, Marotti JD, Gelber S, et al. Pathologic features and molecular phenotype by patient age in a large cohort of young women with breast cancer. *Breast Cancer Res Treat*. 2012;131:1061–1066.
- Conlon N, Howard J, Catalano J, et al. Breast carcinoma in young women: no evidence of increasing rates of metastatic breast carcinoma in a single tertiary center review. *Breast J*. 2016.
- Demicheli R, Bonadonna G, Hrushesky WJ, et al. Menopausal status dependence of the timing of breast cancer recurrence after surgical removal of the primary tumour. *Breast Cancer Res*. 2004;6:R689–696.
- Salte-Fulero A, Donnadieu A, Leman-Detours S, et al. [New options in adjuvant endocrine therapy in breast cancer]. *Bull Cancer*. 2016;103:104–112.
- Purwanto I, Kurnianda J, Hariadi KW, et al. Concentration of serum HER-2/neu as a prognostic factor in locally advanced breast cancer (LABC) and metastatic breast cancer (MBC). *Acta Med Indones*. 2011;43:23–28.
- Onitilo AA, Engel JM, Greenlee RT, et al. Breast cancer subtypes based on ER/PR and Her2 expression: comparison of clinicopathologic features and survival. *Clin Med Res*. 2009;7:4–13.
- Van Belle V, Van Calster B, Brouckaert O, et al. Qualitative assessment of the progesterone receptor and HER2 improves the Nottingham Prognostic Index up to 5 years after breast cancer diagnosis. *J Clin Oncol*. 2010;28:4129–4134.
- Makubate B, Donnan PT, Dewar JA, et al. Cohort study of adherence to adjuvant endocrine therapy, breast cancer recurrence and mortality. *Br J Cancer*. 2013;108:1515–1524.

21. Joensuu K, Heikkilä P, Andersson LC. Tumor dormancy: elevated expression of stanniocalcins in late relapsing breast cancer. *Cancer Lett.* 2008;265:76–83.
22. Murai R, Tanaka M, Takahashi Y, et al. Stanniocalcin-1 promotes metastasis in a human breast cancer cell line through activation of PI3K. *Clin Exp Metastasis.* 2014;31:787–794.
23. Hou J, Wang Z, Xu H, et al. Stanniocalcin 2 suppresses breast cancer cell migration and invasion via the PKC/claudin-1-mediated signaling. *PLoS One.* 2015;10:e0122179.
24. Meng S, Tripathy D, Frenkel EP, et al. Circulating tumor cells in patients with breast cancer dormancy. *Clin Cancer Res.* 2004;10:8152–8162.
25. Vera-Ramirez L, Sanchez-Rovira P, Ramirez-Tortosa CL, et al. Gene-expression profiles, tumor microenvironment, and cancer stem cells in breast cancer: latest advances towards an integrated approach. *Cancer Treat Rev.* 2010;36:477–484.
26. Lv X, Wang Y, Song Y, et al. Association between ALDH1+/CD133+ stem-like cells and tumor angiogenesis in invasive ductal breast carcinoma. *Oncol Lett.* 2016;11:1750–1756.