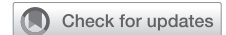

Ischemic dual papillary muscle rupture in a postpartum patient with vascular Ehlers-Danlos syndrome



J. Mark Erfe, MD,^a Paul Devlin, MD,^a Jonathan Rich, MD,^a Lisa Wilsbacher, MD,^a Daniel Schimmel, MD,^a Patrick McCarthy, MD,^a and Amit Pawale, MD,^{a,b} Chicago, Ill, and St Louis, Mo

From the ^aFeinberg School of Medicine, Northwestern Memorial Hospital, Chicago, Ill; and ^bWashington University School of Medicine, Barnes-Jewish Hospital, St Louis, Mo.

Disclosures: Dr Schimmel began consulting for and received speaking fees from Inari after resolution of this case. All other authors reported no conflicts of interest.

The *Journal* policy requires editors and reviewers to disclose conflicts of interest and to decline handling or reviewing manuscripts for which they have a conflict of interest. The editors and reviewers of this article have no conflicts of interest.

Read at *The American Association for Thoracic Surgery Mitral Conclave Workshop, Boston, Massachusetts, May 13-14, 2022.*

Received for publication May 16, 2022; accepted for publication June 6, 2022; available ahead of print July 3, 2022.

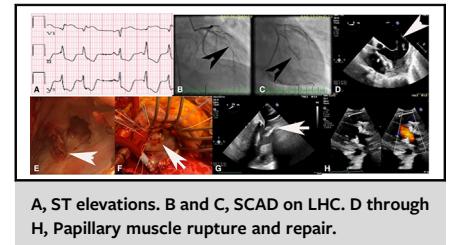
Address for reprints: J. Mark Erfe, MD, Northwestern Memorial Hospital, 675 N Saint Clair St, 7th Floor, Suite 700, Chicago, IL 60611 (E-mail: jmerfe@gmail.com).

JTCVS Techniques 2022;15:84-6

2666-2507

Copyright © 2022 The Authors. Published by Elsevier Inc. on behalf of The American Association for Thoracic Surgery. This is an open access article under the CC BY-NC-ND license (<http://creativecommons.org/licenses/by-nc-nd/4.0/>).

<https://doi.org/10.1016/j.jtc.2022.06.012>



A, ST elevations. B and C, SCAD on LHC. D through H, Papillary muscle rupture and repair.

CENTRAL MESSAGE

We explain the case of a 28-year-old postpartum woman presenting with bilateral papillary muscle rupture, as an index presentation of vascular Ehlers-Danlos syndrome.

CLINICAL SUMMARY

We present a case of a 28-year-old postpartum woman in refractory cardiogenic shock due to spontaneous coronary artery dissection of her left anterior descending artery and obtuse marginal artery, with rupture of both papillary muscles and subsequent vascular Ehlers-Danlos syndrome (vEDS) diagnosis. Institutional review board approval was waived because the report did not include any identifiable personal information, and it was deemed unnecessary at the time. The patient provided verbal but not written consent for publication. She presented on postpartum day 10 with acute chest pain and shortness of breath, in flash pulmonary edema. Electrocardiogram showed ST depressions (Figure 1, A), troponins were elevated. Left heart catheterization showed spontaneous coronary artery dissection of the left anterior descending artery (Figure 1, B) and obtuse marginal artery (Figure 1, C) with diffuse right coronary artery spasm. Femoral intra-aortic balloon pump was placed. Transthoracic echocardiogram demonstrated severe mitral regurgitation with flail anterior leaflet of the mitral valve and left ventricular ejection fraction (LVEF) of 65%. She was in refractory cardiogenic shock despite femoral intra-aortic balloon pump and high dose inotropes. She had bilateral iliac artery spasm, which precluded peripheral venous-arterial extracorporeal membrane oxygenation (VA ECMO). She was taken to the operating room for emergency surgery.

The patient underwent median sternotomy. Cardiopulmonary bypass was established with ascending aortic and bicaval cannulation after systemic heparinization. Antegrade and retrograde cardioplegia was used. Intraoperative transesophageal echocardiogram (TEE) showed ruptured anterolateral and posteromedial papillary muscles, bileaflet flail pathology, and severe mitral regurgitation (Figure 1, D). Her tissues were extremely fragile, with large hematomas present on the epicardium. The left atrium (LA) was opened through Sondergaard's groove. Both the anterolateral and posteromedial papillary muscles had ruptured (Figure 1, E and F). The leaflets were excised. There was diffuse hematoma in the atrioventricular groove and below in the myocardium. The mitral valve (MV) was replaced with a 27 mm porcine bioprosthesis. The LA suture line and antegrade cardioplegia sites required multiple pledgeted suture reinforcements. A right atrial tear extending in the inferior vena cava was repaired with bovine pericardium. A decision was made not to do bypass for the dissected coronaries.

TEE showed good prosthetic MV function with severely globally impaired left ventricle (LV). cardiopulmonary bypass was converted to central VA ECMO. The chest was packed and left open due to severe coagulopathy and diffuse epicardial bleeding. She required mediastinal washouts over the next 3 days. TEE on postoperative day 3 showed a large layered thrombus on LA side of the

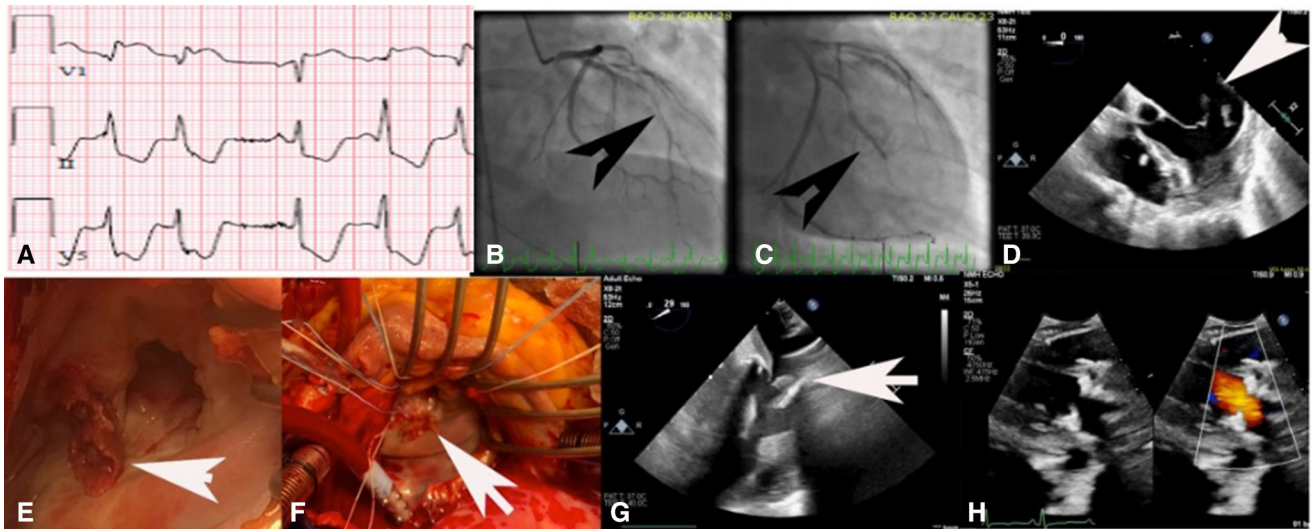


FIGURE 1. A, Diffuse ST depressions in electrocardiogram. B and C, spontaneous coronary artery dissection of *left* anterior descending artery and obtuse marginal artery on coronary angiogram. D, Intraoperative transesophageal echocardiogram showing bileaflet mitral flail with ruptured papillary muscles. E and F, Ruptured papillary muscles to both leaflets on direct inspection. G, Prosthetic mitral valve thrombosis. H, Predischarge transthoracic echocardiogram showing no mitral regurgitation and mild mitral stenosis.

prosthetic MV causing severe mitral stenosis (mean gradient, 12 mm Hg) (Figure 1, G). She was started on intravenous heparin. Over the next few days, her LVEF improved allowing lower ECMO flow and more blood flow through LA. This was aided by inotropes, more minute ventilation, and lower sweep on ECMO.

On postoperative day 8, TEE showed persistent severe mitral stenosis secondary to the organized thrombus. The next day, while on ECMO support, transeptal LA thrombectomy was performed via femoral vein using Penumbra (Penumbra) and FlowTriever (Inari Medical) devices along with percutaneous cerebral embolic protection device deployed via radial artery, resulting in improved mitral stenosis (mean gradient decreased to 5 mm Hg from 13 mm Hg). With continuing hemodynamic improvement, ECMO was decannulated on postoperative day 11, and the chest was closed. She was extubated on postoperative day 18. She required femoral artery dissection repair on postoperative day 17. She was discharged 2 months postoperatively. Her transthoracic echocardiogram showed no mitral regurgitation, mean mitral gradient of 6 mm Hg, and LVEF of 65% (Figure 1, H). Six months postoperatively, she is doing well in New York Heart Association functional class I.

DISCUSSION

vEDS is caused by autosomal dominant mutation of the *COL3A1* gene encoding type III collagen.¹ True prevalence of vEDS is unknown, although data suggest a frequency of at least 1 in 100,000 (4% of EDS cases).² Unlike classic

EDS, vEDS is distinguished by its increased risk of spontaneous vascular or visceral rupture and the absence of large-joint hyperextensibility. Rupture of internal organs such as intestine and muscles have been reported in most patients by aged 40 years, and peripartum mortality is higher than average.² Papillary muscle rupture in postpartum patients with EDS is extremely rare.³ To our knowledge, this is the first report of ischemic double papillary muscle rupture in vEDS.

In this case when LA/prosthetic MV thrombus was noticed causing severe mitral stenosis while on central VA ECMO support, we decided not to do repeat surgery given the fragile tissues. If there would be reduced LVEF coming off bypass again after another aortic crossclamp and complex surgery due to friable tissues, it could have led to a continued need for mechanical circulatory support with high probability of repeat thrombus formation.

We attempted catheter thrombectomy after failure of a trial of anticoagulation. Although catheter-guided thrombectomy is used for right heart thrombus, pulmonary embolism,⁴ this was unconventional for this case and was performed after discussing with patient's family due to the high risk of surgery. This unique case also highlights the need for patients with such clinical presentation to be investigated for vEDS.¹

References

1. Pepin M, Schwarze U, Superti-Furga A, Byers PH. Clinical and genetic features of Ehlers-Danlos syndrome type IV, the vascular type. *N Engl J Med.* 2000;342:673-80. Erratum in: *N Engl J Med.* 2001;344:392.
2. Pepin MG, Byers PH. Ehlers-Danlos syndrome type IV. In: Pagon RA, Bird TD, Dolan CR, et al. eds. *GeneReviews*TM [Internet]. University of Washington; 2011.

3. Seve P, Dubreull O, Farhat F, Plauchu H, Toubul P, Broussolle C. Acute mitral regurgitation caused by papillary muscle rupture in the immediate postpartum period revealing Ehlers-Danlos syndrome type IV. *J Thorac Cardiovasc Surg.* 2005;129:680-1.
4. Bishay VL, Adenikinju O, Todd R. FlowTriever Retrieval System for the treatment of pulmonary embolism: overview of its safety and efficacy. *Expert Rev Med Devices.* 2021;18:1039-48.