

# Esophageal Bronchial Artery Fistulaization: A Complication of an Endobronchial Ultrasound

Sonal Jadeja, DO<sup>1</sup>, Kevin Green, MD<sup>1</sup>, Asim Shuja, MD<sup>2</sup>, Miguel Malespin, MD<sup>2</sup>, and Silvio De Melo, MD<sup>2</sup>

<sup>1</sup>Department of Internal Medicine, University of Florida College of Medicine, Jacksonville, FL

<sup>2</sup>Division of Gastroenterology, University of Florida College of Medicine, Jacksonville, FL

## ABSTRACT

Bronchial artery pseudoaneurysms are an extremely rare cause of upper gastrointestinal bleeding. The presence of a bronchial artery pseudoaneurysm resulting in an esophageal fistula is an entity that, to our knowledge, has yet to be described. Successful management requires an interdisciplinary approach to guide closure of the defects. We present a novel case of an esophageal fistula and bronchial artery pseudoaneurysm resulting from an endobronchial ultrasound-guided transbronchial needle aspiration successfully managed by endoscopic therapy and coil embolization.

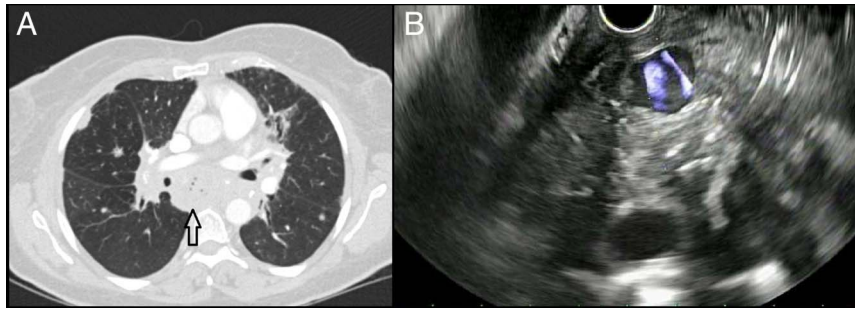
## INTRODUCTION

Transbronchial needle aspiration (TBNA) is a routine diagnostic modality used in the evaluation of lung masses and mediastinal/hilar lymphadenopathy. Although an endobronchial ultrasound-guided TBNA (EBUS-TBNA) has been described as a relatively safe procedure with very low complication rates, the complications that have been reported were severe. The most common complications include hemorrhage, infection, pneumothorax, and, rarely, death.<sup>1-3</sup> Cervical esophageal perforation and esophageal mediastinal fistulation are the most frequently encountered gastrointestinal complications. However, the incidence is unknown because of the rarity of these conditions.<sup>4</sup> When clinical suspicion of fistula occurs, thoracic and abdominal computed tomography (CT) with oral contrast, followed by endoscopy, is used for diagnosis. Nonoperative treatment options include conservative management, esophageal stenting, endoclip application, and endoscopic fibrin application.<sup>2,3</sup> Management largely depends on the location of the fistula, size of the anatomic defect, and clinical status of the patient. No cases thus far have reported esophageal bronchial artery pseudoaneurysm fistulation as a complication of EBUS-TBNA.

## CASE REPORT

A 50-year-old woman with a medical history of human immunodeficiency virus infection and gastroesophageal reflux disease presented with intermittent productive cough and dyspnea on exertion. A thoracic CT showed bilateral pulmonary nodules and fibrotic changes with mediastinal and hilar lymphadenopathy. An EBUS-TBNA of the right hilar and subcarinal lymph nodes with bronchoalveolar lavage was performed. The procedure was complicated by mild postoperative hemoptysis, which was self-limiting. The pathological evaluation of the lymph nodes was negative for malignancy or autoimmune processes. One month after her EBUS-TBNA, she returned with complaints of chest pain, hemoptysis, and hematemesis. She presented without signs of systemic infection; however, she was noted to have a drop in her hemoglobin from 10 to 8 g/dL. Thoracic CT revealed numerous foci of gas within the posterior mediastinum and adenopathy adjacent to the esophagus suspicious for esophageal fistula formation. Bronchoscopy showed no evidence of active bleeding.

Endoscopic ultrasound (EUS) demonstrated a 13 × 15-mm circular anechoic structure in the mediastinum anterior to the esophagus with visible arterial Doppler flow suggestive of a pseudoaneurysm at the level of the subcarinal region, a small fistula in the middle third of the esophagus, and abnormal lymph nodes in the paratracheal region (Figure 1). Immediately after EUS-fine needle aspiration of the lymph nodes via the transesophageal approach, endoscopy revealed gross blood in the middle third of the esophagus emanating from the fistulous tract along with a hiatal hernia and moderate-sized Schatzki ring. No other site of gastrointestinal bleeding was identified. The fistula was located 25 cm from the incisors and was treated with placement of an endoclip because of the active extravasation of

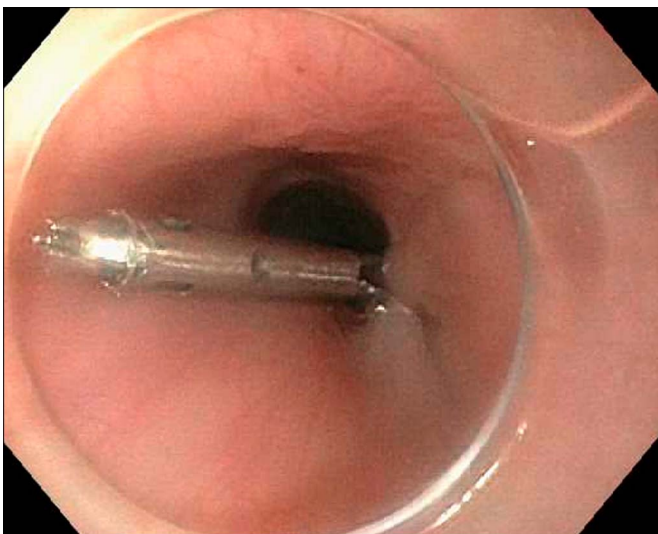


**Figure 1.** Endoscopic ultrasound showing (A) numerous foci of gas within the posterior mediastinal adenopathy adjacent to the esophagus and (B) a circular anechoic structure with visible Doppler flow seen endosonographically in the anterior mediastinum to the esophagus suggestive of a pseudoaneurysm.

blood (Figure 2). A postprocedural thoracic CT angiogram showed a posterior hyperdense  $9 \times 5$ -mm area, which was enlarged compared with her initial CT on the same admission. This was attributed to a pseudoaneurysm of the bronchial artery. Afterward, a coil embolization of the right T7 bronchial artery was performed with the resolution of her hemoptysis. Pathology from the initial EBUS showed granulomatous tissue and calcifications consistent with sarcoidosis. She was prescribed a 4-week course of amoxicillin/clavulanic acid for empiric treatment of mediastinitis, given the CT imaging findings which were likely due to contamination with esophageal contents. A follow-up endoscopy was recommended for the re-evaluation of her esophageal fistula. However, the patient deferred follow-up. Postembolization CT scan demonstrated the resolution of the pseudoaneurysm and mediastinitis.

## DISCUSSION

Esophageal fistula formation resulting from an abnormal communication within an arterial system may lead to exsanguination from massive hematemesis if not recognized early.



**Figure 2.** Placement of a hemostatic clip overlying the fistula with the resolution of bleeding postprocedure.

Many cases of arterial-esophageal fistulation have been reported, most commonly due to aortic fistulation because of foreign body ingestion, aortic aneurysm, or esophageal malignancy.<sup>5,6</sup>

EBUS-TBNA is generally a very safe procedure with complication rates ranging from 0.8% to 6.8%. Common complications include cough, bleeding, fever, transient bacteremia, and sedation-related effects. Less frequent complications include puncture of surrounding mediastinal structures, pneumothorax, pneumomediastinum, hemomediastinum, mediastinitis, and fistula formation. As far as we know, there have not been any cases that reported the formation of a fistula between the esophagus and a bronchial artery pseudoaneurysm after an EBUS-TBNA. The needle puncture likely caused injury to the arterial wall, which weakened over time, thus resulting in the formation of an aneurysm. The aneurysm within the high-pressure system of the bronchial arteries was deemed responsible for the patient's hematemesis and hemoptysis. Transversion of the subcarinal lymph nodes during needle aspiration also led to a secondary defect, allowing a fistula formation between the pseudoaneurysm and the esophagus. The presence of this secondary defect led to the reflux of gastrointestinal contents into the mediastinum resulting in mediastinitis and mediastinal lymphoid hyperplasia resulting in the focal pockets of gas seen on CT. No evidence of bronchial fistulation was seen. Evidence of mediastinal gas on CT post-procedure is not anticipated and should raise concern for infectious or traumatic procedural complications.

The initial management of a patient presenting with hemoptysis and hematemesis should include initiating general resuscitative measures. After stabilization, diagnostic evaluation by thoracic CT angiogram and esophagogastroduodenoscopy can be performed for localization of the bleeding site.<sup>7,8</sup> Endoscopic clipping has become the preferred method for ulcer hemostasis. However, it may also be used for closure of mucosal defects, endoscopic marking, and ligation of vascular bleeding.<sup>9</sup> EUS offers additional diagnostic utility in its ability to evaluate the posterior mediastinum and better localize aneurysms with the use of Doppler. In this case, EUS was used for fine-needle aspiration of multiple abnormal lymph nodes before clipping the mucosal defect.<sup>4,10,11</sup>

Esophageal fistula formation is a serious condition that may be fatal if left untreated. Aspiration of gastrointestinal contents into the bronchial tree may lead to aspiration pneumonia resulting in mediastinitis, followed by acute respiratory distress syndrome.<sup>12</sup> Surgical closure of esophageal fistulas is not routinely performed because of the higher mortality rate and development of less invasive endoscopic techniques.<sup>10</sup> Fistulas may be closed by bronchoscopic or endoscopic clipping or stenting the tracheal or esophageal segments, respectively. However, these procedures may result in complications such as mucus plugging, perforation, and stent migration.<sup>11</sup>

In conclusion, our case demonstrated a successful multidisciplinary approach to the treatment of a bronchial artery pseudoaneurysm with esophageal fistula formation after EBUS-TBNA. It highlights the importance of early recognition and a team-based approach to achieve an optimal outcome. Modern diagnostic and therapeutic modalities now involve transluminal interventions, as seen in this case. These techniques can cause damage to nearby structures despite their favorable safety profile. Thus, a high index of suspicion and a detailed investigation are paramount when evaluating possible postprocedural complications.

## DISCLOSURES

Author contributions: S. Jadeja wrote the manuscript and is the article guarantor. K. Green, A. Shuja, and M. Malespin edited the manuscript. S. De Melo approved the final manuscript.

Financial disclosure: None to report.

Informed consent was obtained for this case report.

Received November 2, 2019; Accepted February 3, 2020

## REFERENCES

1. Pal K, Seeram VK, Cury JD. An unusual case of iatrogenic haemoptysis. *BMJ Case Rep.* 2014;2014:10–6.
2. Misselt AJ, Krowka MJ, Misra S. Successful coil embolization of mediastinal bronchial artery aneurysm. *J Vasc Interv Radiol.* 2010;21(2):295–6.
3. Bernasconi M, Koegelenberg CFN, Koutsokera A, et al. Iatrogenic bleeding during flexible bronchoscopy: Risk factors, prophylactic measures and management. *ERJ Open Res.* 2017;3(2):26–37.
4. Hashemi SMS, Dahele M, Daniels JMA, Smit EF. Complications of endoscopic ultrasound-guided needle aspiration. *Acta Oncol.* 2014;53(9):1265–8.
5. Kokatnur L, Rudrappa M. Primary aorto-esophageal fistula: Great masquerader of esophageal variceal bleeding. *Indian J Crit Care Med.* 2015;19(2):119–21.
6. Heckstall RL, Hollander JE. Aortoesophageal fistula: Recognition and diagnosis in the emergency department. *Ann Emerg Med.* 1998;32(4):502–5.
7. Larici AR, Franchi P, Occhipinti M, et al. Diagnosis and management of hemoptysis. *Diagn Interv Radiol.* 2014;20(4):299–309.
8. Chun JY, Morgan R, Belli AM. Radiological management of hemoptysis: A comprehensive review of diagnostic imaging and bronchial arterial embolization. *Cardiovasc Intervent Radiol.* 2010;33(2):240–50.
9. Anastasiades CP, Baron TH, Wong Kee Song LM. Endoscopic clipping for the management of gastrointestinal bleeding. *Nat Clin Pract Gastroenterol Hepatol.* 2008;5(10):559–68.
10. Zhang J, Samarasena JB, Milliken J, Lee JG. Large esophageal fistula closure using an over-the-scope clip: Two unique cases. *Ann Thorac Surg.* 2013;96(6):2214–6.
11. Lázár G, Paszt A, Mán E. Role of endoscopic clipping in the treatment of oesophageal perforations. *World J Gastrointest Endosc.* 2016;8(1):13–22.
12. Zuluaga CP, Aluja Jaramillo F, Velásquez Castaño SA, Rivera Bernal AL, Granada JC, Carrillo Bayona JA. Aortic pseudoaneurysm secondary to mediastinitis due to esophageal perforation. *Case Rep Radiol.* 2016;2016:7982641.

**Copyright:** © 2020 The Author(s). Published by Wolters Kluwer Health, Inc. on behalf of The American College of Gastroenterology. This is an open-access article distributed under the terms of the Creative Commons Attribution-Non Commercial-No Derivatives License 4.0 (CCBY-NC-ND), where it is permissible to download and share the work provided it is properly cited. The work cannot be changed in any way or used commercially without permission from the journal.