

Access this article online
Quick Response Code:

Website: www.e-tjo.org
DOI: 10.4103/tjo.tjo_17_19

# *Alternaria chartarum* sclerokeratouveitis: A new fungus cause

Luz Elena Concha del Río<sup>1\*</sup>, Carolina Ramirez-Dominguez<sup>1</sup>, Virginia Vanzini-Zago<sup>1</sup>, Lourdes Arellanes-Garcia<sup>2</sup>

## Abstract:

We report a case of *Alternaria chartarum* sclerokeratouveitis with an unfavorable response to treatment. To the best of our knowledge, there are no previous reports of this fungus invading the sclera. A 68-year-old diabetic farmer male patient presented with a 3-week history of pain and redness and a decrease in visual acuity occurring 5 days before admittance in the right eye. Examination revealed severe mixed hyperemia and a scleral calcified plaque with a surrounding area of ischemia and lysis. The cornea showed diffuse infiltrates, stromal edema, and hypopyon. Initial scrapings were negative, and empiric antibiotics were started. After a fungus was reported, topical and systemic antifungals were initiated, but there was no clinical response. The eye was enucleated. A slow-growing fungus *A. chartarum*, resistant to voriconazole, was isolated. Fungal etiology must be kept in mind when dealing with infectious scleritis. Despite treatment, the outcome of this case was unfavorable due to the slow-growing nature of the fungus and this strain's resistance to voriconazole.

## Keywords:

*Alternaria chartarum*, fungus, sclerokeratouveitis

## Introduction

Scleritis is an immune-mediated disease. Infectious causes represent 5%–10% of cases.<sup>[1-3]</sup> Necrotizing presentation is the most frequent form, with a calcified plaque and no response to anti-inflammatory treatment.<sup>[3]</sup>

Although bacteria, particularly *Pseudomonas aeruginosa*, are among the most prevalent pathogens,<sup>[1-4]</sup> in developing countries fungi are also common causes, most likely because of climate differences.<sup>[2,3]</sup> Fungal scleritis has a more chronic initial course than bacterial scleritis.<sup>[2]</sup> Predisposing factors such as surgery, trauma, and immunosuppression have been identified.<sup>[3]</sup>

We report a case of *Alternaria chartarum* sclerokeratouveitis in a diabetic elderly man with prior pterygium surgery.

This is an open access journal, and articles are distributed under the terms of the Creative Commons Attribution-NonCommercial-ShareAlike 4.0 License, which allows others to remix, tweak, and build upon the work non-commercially, as long as appropriate credit is given and the new creations are licensed under the identical terms.

For reprints contact: WKHLRPMedknow\_reprints@wolterskluwer.com

## Case Report

A 68-year-old Mexican farmer presented to the clinic with decreased visual acuity of the right eye of 5 days' duration and a 3-week history of pain and hyperemia of the same eye. He had a history of diabetes mellitus, arterial hypertension, primary open-angle glaucoma, and pterygium surgery in his right eye 12 years ago. Treatment before referral included: topical moxifloxacin/dexamethasone q3 h, tropicamide/phenylephrine bid, dorzolamide/timolol/brimonidine bid, and oral prednisone 80 mg daily.

His best-corrected visual acuity was OD (right eye) counting fingers at 20 cm and OS 20/25. Intraocular pressure was 10 mmHg and 11 mmHg in OD and OS, respectively. Slit-lamp examination of the right eye revealed diffuse hyperemia, ciliary injection, and a scleral calcified

**How to cite this article:** Concha del Rio LE, Ramirez-Dominguez C, Vanzinni-Zago V, Arellanes-Garcia L. *Alternaria chartarum* sclerokeratouveitis: A new fungus cause. Taiwan J Ophthalmol 2021;11:190-2.

<sup>1</sup>Inflammatory Eye Diseases Clinic, Hospital Dr. Luis Sánchez Bulnes, Asociación Para Evitar La Ceguera En México, Mexico City, Mexico, <sup>2</sup>Department of Microbiology, Hospital Dr. Luis Sánchez Bulnes, Asociación Para Evitar La Ceguera En México, Mexico City, Mexico

### \*Address for correspondence:

Prof. Luz Elena Concha del Río, Inflammatory Eye Diseases Clinic, Hospital Dr. Luis Sánchez Bulnes, Asociación Para Evitar La Ceguera En México, Mexico City, Mexico. E-mail: luzelena.concha@apec.com.mx

Submission: 28-03-2019  
Accepted: 10-02-2020  
Published: 27-04-2020

plaque with a surrounding area of ischemia and lysis nasally [Figure 1a]. The cornea showed diffuse infiltrates and stromal edema, and a feathery 2-mm hypopyon was observed in the anterior chamber. Posterior segment examination of the right eye was not possible due to media opacity. The left eye was within normal limits for the anterior segment, and the posterior segment was remarkable for glaucomatous damage of the optic nerve.

B-scan ultrasound in the right eye showed dense mobile vitreous condensations, a thickened choroid with sub-Tenon's infiltration, and an apparent inferior serous detachment.

A systemic workup was performed, and a complete blood count was relevant for leukocytosis 12,200/mm<sup>3</sup>, while the chemistry panel found hyperglycemia (174 mg/dl). Venereal Disease Research Laboratory, Fluorescent treponemal antibody-absorption, purified protein derivative, antineutrophil cytoplasmic antibodies, and antinuclear antibody were all reported as negative.

We diagnosed a sclerokeratouveitis with necrosis of probable infectious etiology in OD.

A scraping of the conjunctival and scleral lesion was performed and was Gram staining negative for bacteria, Giemsa stain positive only for conjunctival epithelial cells, and periodic acid-Schiff (PAS) negative for fungus and *Candida*. Initial treatment was started with topical moxifloxacin qh, prednisolone acetate q2 h and tropicamide/phenylephrine tid, oral moxifloxacin 400 mg bid, and oral prednisone was tapered to 45 mg/daily.

At the 7<sup>th</sup> day after incubation, the conjunctiva sample inoculated on Sabouraud-Emmons dextrose agar, the microbiology laboratory reported 10 slow-growing colonies of a white-brown cotton-like fungus. Therapy was switched to topical voriconazole 1% qh and oral itraconazole 100 mg bid. Prednisolone acetate q2 h, tropicamide/phenylephrine tid, and oral prednisone 45 mg/daily were maintained.

By the 10<sup>th</sup> day, visual acuity was light perception OD with a worsening clinical picture; therefore, oral itraconazole

was switched to oral voriconazole 400 mg qd, and intracameral moxifloxacin and voriconazole 1% were administered after an aqueous humor tap.

It is on the 14<sup>th</sup> day that the microbiology laboratory reported 6–7 colonies of a moderately slow-growing unclassified melanized fungus in the sclera sample. Clinically, the patient was not responding to treatment, with an increase in the level of hypopyon and thinning around the scleral plaque [Figure 1b].

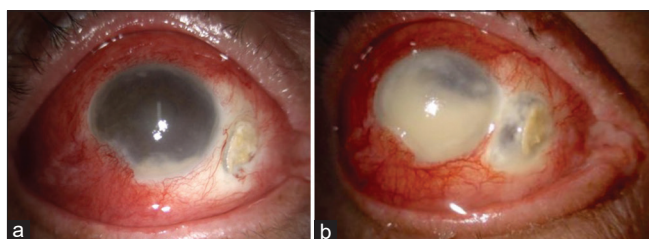
Because of an inadequate response to treatment and the risk of systemic dissemination, the decision to enucleate the eye was made on the 16<sup>th</sup> day. Pathology reported a mycotic ulcerative keratitis with diffuse perforated scleritis with necrosis and mycotic exogenous endophthalmitis. Microbiology found multiple thin hyphae septate, branched intensely, positive to PAS and Grocott-Gomori's staining [Figure 2a].

Due to the slow growth of the fungus, it is until the 27<sup>th</sup> day after the first visit that the microbiology department concludes cultures which are positive for *A. chartarum* resistant to voriconazole 1 mcg/ml by diffusion method, according to breakpoints defined [Figure 2b].<sup>[5]</sup> In Atlas of Clinical Mycology version 4.1 (2013), the susceptibility of *A. chartarum* is reported in minimum inhibitory concentration in 5 strains, 5.3 mcg/ml for amphotericin, 6.7 mcg/ml for itraconazole, and 2.4 mcg/ml for miconazole; this mean is resistant to all antimycotic drugs.<sup>[6]</sup>

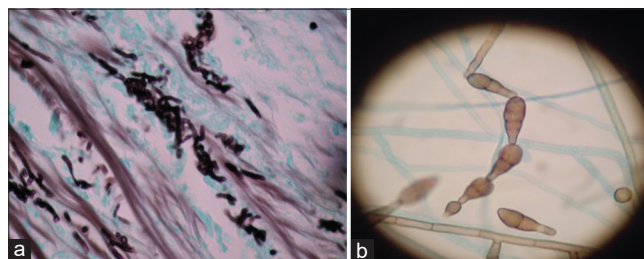
## Discussion

*A. chartarum* is a pigmented filamentous fungus with a ubiquitous presence in soil, vegetation, food, and indoor air that causes opportunistic human infections.<sup>[7]</sup> It is uncommonly reported as a cause of keratitis<sup>[7]</sup> and to our knowledge has not been identified as a source of scleritis.

Risk factors for infectious scleritis in this patient included older age,<sup>[3]</sup> diabetes mellitus,<sup>[4]</sup> and pterygium excision, even though the use of adjunctive therapy such as beta-radiation, mitomycin C, and excessive cautery<sup>[1-4]</sup> that also predispose to this condition could not be determined.



**Figure 1:** (a) Slit-lamp photograph showing diffuse hyperemia, ciliary injection, corneal edema, hypopyon, and nasal scleral calcified plaque with necrosis. (b) Slit-lamp photograph showing an increase in hypopyon and scleral thinning surrounding the calcified plaque



**Figure 2:** (a) Hyphae in the sclera (arrow) (Grocott-Gomori's stain x40). (b) Alternate septated hyphae (lactophenol cotton blue wet mount x400)

Compared to other ocular surgical procedures associated with infectious scleritis, pterygium excision has a longer interval to presentation,<sup>[1,3,4]</sup> and it is unknown why the infection becomes active after a long latency period.<sup>[3]</sup> Associated features can include scleral necrosis, calcified plaques, anterior segment inflammation, and corneal involvement<sup>[2]</sup> like those found in this case.

When suspecting an infectious etiology, scrapings and cultures are always recommended, especially if there is no response to treatment.<sup>[3]</sup> This case illustrates the fact that fungal infections take longer to diagnose than bacterial ones. Ferrer *et al.* have reported the efficiency of polymerase chain reaction as a rapid diagnostic method for this microorganism.<sup>[8]</sup>

*A. chartarum* responds variably to topical and systemic antifungals,<sup>[7]</sup> as illustrated by this case. There is limited information available concerning the *in vitro* antifungal susceptibility of *Alternaria* spp.<sup>[7]</sup> Even when voriconazole is reported to be a promising treatment due to its bioavailability,<sup>[7]</sup> it was not successful in this patient. Surgical debridement is proposed as a way to debulk the microbial load and facilitate treatment penetration.<sup>[2,4]</sup> Because this patient already had intraocular involvement, this was not considered to be a favorable option.

The unfavorable outcome of enucleation is common. Hodson *et al.*<sup>[1]</sup> reported that it can be required in 25% of cases, whereas Tittler *et al.*<sup>[4]</sup> found it to be necessary in 18%. Worse outcomes in infectious scleritis are consistently associated with fungal etiology, corneal involvement, endophthalmitis, exclusive (nonsurgical) medical treatment, and poor visual acuity at presentation,<sup>[1,3]</sup> as seen in this case.

The use of topical or oral steroids is questionable. Our patient upon admission was not responsive to high dose of prednisone, which delayed diagnosis; it was tapered and continued alongside antifungal therapy. Prescription of steroids is for a rapid control of the destructive inflammation and for pain control. But they can worsen the disease when dose and route is not well-established.<sup>[10]</sup>

Even though fungal sclerokeratouveitis is rare, it is a serious and vision-threatening entity that should always be considered in the differential diagnosis to avoid treatment delay and improve outcomes.

As far as we know, this is the first case of *A. chartarum* sclerokeratouveitis to be reported in the literature. It reflects the need to maintain a high index of suspicion for fungal etiology when dealing with infectious scleritis

with predisposing risk factors. It also highlights the importance of fungal cultures to determine the final diagnosis and microbial sensitivity. Despite treatment, the outcome in this case was unfavorable due to the slow-growing nature of the fungus and this particular strain's resistance to voriconazole.

### Declaration of patient consent

The authors certify that they have obtained all appropriate patient consent forms. In the form the patient has given his consent for his images and other clinical information to be reported in the journal. The patient understands that his names and initials will not be published and due efforts will be made to conceal their identity, but anonymity cannot be guaranteed.

### Financial support and sponsorship

Nil.

### Conflicts of interest

The authors declare that there are no conflicts of interests of this paper.

## References

1. Hodson KL, Galor A, Karp CL, Davis JL, Albini TA, Perez VL, *et al.* Epidemiology and visual outcomes in patients with infectious scleritis. *Cornea* 2013;32:466-72.
2. Ho YF, Yeh LK, Tan HY, Chen HC, Chen YF, Lin HC, *et al.* Infectious scleritis in Taiwan—a 10-year review in a tertiary-care hospital. *Cornea* 2014;33:838-43.
3. Ramenaden ER, Raiji VR. Clinical characteristics and visual outcomes in infectious scleritis: A review. *Clin Ophthalmol* 2013;7:2113-22.
4. Tittler EH, Nguyen P, Rue KS, Vasconcelos-Santos DV, Song JC, Irvine JA, *et al.* Early surgical debridement in the management of infectious scleritis after pterygium excision. *J Ophthalmic Inflamm Infect* 2012;2:81-7.
5. Pujol I, Aguilar C, Gené J, Guarro J. *In vitro* antifungal susceptibility of *Alternaria* spp. and *Ulocladium* spp. *J Antimicrob Chemother* 2000;46:337.
6. De Hoog GS, Guarro J, Gene J, Figueras MJ. Atlas of Clinical Fungi: The Ultimate Benchmark for Diagnostics. 2<sup>nd</sup> edn/Electronic Version 4.1. Westerdijk Fungal Biodiversity Institute (Former CBS-KNAW), Utrecht, The Netherlands and Universitat Rovira I Virgili, Reus, Spain:2000/2017.
7. Hsiao CH, Yeh LK, Chen HC, Lin HC, Chen PY, Ma DH, *et al.* Clinical characteristics of *alternaria* keratitis. *J Ophthalmol* 2014;2014:536985.
8. Ferrer C, Montero J, Alió JL, Abad JL, Ruiz-Moreno JM, Colom F. Rapid molecular diagnosis of posttraumatic keratitis and endophthalmitis caused by *Alternaria* infectoria. *J Clin Microbiol* 2003;41:3358-60.
9. Pradhan ZS, Jacob P. Infectious scleritis: Clinical spectrum and management outcomes in India. *Indian J Ophthalmol* 2013;61:590-3.
10. Ahmad S, Lopez M, Attala M, Galor A, Stanciu NA, Miller D, *et al.* Interventions and outcomes in patients with infectious *Pseudomonas scleritis*: A 10-year perspective. *Ocul Immunol Inflamm* 2019;27:499-506.