

Rheumatology 2019;58:1691–1692
 doi:10.1093/rheumatology/kez118
 Advance Access publication 9 April 2019

Clinical impact of artifactual hypoglycaemia and its diagnosis at the bedside

Rheumatology key message

- Knowledge of artifactual hypoglycaemia is necessary to prevent unnecessary work-up, therapy and anxiety.

SIR, The term artifactual hypoglycaemia has been proposed for the discrepancy between low capillary and normal plasma glucose levels, and has been described in various conditions, including RP [1]. Early recognition is challenging, but is important to prevent anxiety and unnecessary treatment and diagnostic tests. We present a case of artifactual hypoglycaemia in a patient with SSc and propose a quick method for its diagnosis.

A 57-year-old man was referred from another hospital because of recurrent, asymptomatic hypoglycaemia. His medical history included SSc and RP, treated with low-dose prednisolone, and aortic valve stenosis with intestinal angiodysplasia for which somatostatin had been recently started. Subsequent monitoring of capillary glucose by finger-stick measurements revealed glucose levels ranging between 2.3 and 7.7 mmol/l, with ~15% of these below 3.5 mmol/l.

Screening diagnostic analysis for insulinoma, performed before the patient was referred, was reportedly negative. Somatostatin, which was thought to have caused the low glucose levels, had been discontinued, the dose of prednisolone was increased (from 5 to 10 mg daily) and continuous feeding over a nasogastric tube had been initiated. However, none of these interventions had led to a clear, sustainable glucose-increasing effect (Fig. 1), although his body weight had increased by 4 kg. The patient had become increasingly anxious about the apparent treatment resistance of his hypoglycaemia.

The patient occasionally reported non-specific symptoms like blurred vision and tremor that were unrelated to the capillary glucose level and did not respond to ingestion of dextrose. We concluded that the criteria of Whipple's triad for hypoglycaemia were not met [2] and suspected a measurement artefact. Because his sclerosis-affected skin hindered venous access, we performed simultaneous measurements on the patient's earlobe when finger-stick measurement suggested hypoglycaemia. These measurements revealed glucose levels to be ~2.8 mmol/l higher in earlobe capillary blood, with none of them being in the hypoglycaemic range.

Screening for diabetes in people at elevated risk is routine practice at all levels of clinical care across medical specialties. Hypoglycaemia in such a patient not treated with glucose-lowering agents should raise the health care provider's suspicion of artifactual hypoglycaemia,

especially when the event is based on capillary blood glucose, measured by finger-stick. Unawareness of this phenomenon may lead to unnecessary diagnostic and therapeutic interventions, as exemplified in our patient.

Artifactual hypoglycaemia, previously referred to as pseudo-hypoglycaemia, has been described in patients with RP, circulatory shock, peripheral arterial disease, Eisenmenger syndrome, acrocyanosis or hypothermia [1]. It has been ascribed to reduced perfusion of the peripheral microcirculation with decelerated glucose transit and increased glucose uptake into the surrounding tissue [3]. Additionally, the term has also been used to describe falsely low plasma glucose values resulting from increased glycolysis by leukocytes, e.g. in chronic myeloid leukaemia [1, 3]. Diagnosis of artifactual hypoglycaemia relies on simultaneous glucose measurements in capillary blood and a venous specimen [1]. Because venous access can be difficult in patients with SSc because of their fibrotized skin and stiffened veins, we chose the earlobe as alternative site for glucose measurement. Earlobe measurements reflect also capillary blood glucose; however, the earlobe remains unaffected by SSc, because it lacks connective tissue [4, 5]. In addition, it allows for diagnosis at the bedside with the same glucose metre, thus circumventing any differences in accuracy with laboratory methods.

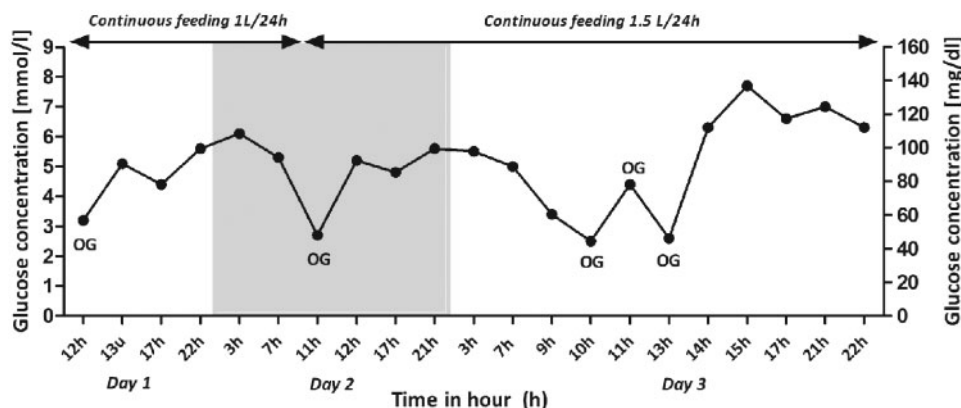
Our case has potential clinical consequences for patients with SSc and RP at risk for or having been diagnosed with diabetes. Indeed, artifactual normal or lower than expected finger-stick glucose values in these patients may give false assumptions of the level of glucose control in people with (coexistent) diabetes or even refute its diagnosis, potentially withholding patients from appropriate treatment. This phenomenon must be particularly considered if there is a discrepancy between the haemoglobin A1c level and glucose values measured by finger-stick. Whenever frequent glucose monitoring is required, e.g. with insulin treatment, switching from finger-stick to earlobe capillary glucose measurement may be considered.

This case illustrates the importance of awareness of artifactual hypoglycaemia, not only to avoid unnecessary work-up and therapy, but also to prevent anxiety associated with the belief of having a medical condition that appears unsolvable. We suggest performing simultaneous glucose measurements on the patient's earlobe and finger-stick whenever this phenomenon is likely to occur, not only in patients with supposedly hypoglycaemia, but also in case of lower than expected glucose levels in patients with (poorly controlled) diabetes mellitus.

Acknowledgements

All authors were involved in the treatment of the patient and the conception of the report. L.C.A.D. researched the data and wrote the first draft of the manuscript. R.J.H.M.V. and B.E.d.G. provided input and commented on the writing of the manuscript at all further stages. L.C.A.D. is the guarantor of the work, had full access to

Fig. 1 Three-day capillary glucose profile



Three-day capillary glucose profile, while the patient received 10 mg prednisolone and continuous tube feeding, the dose of which was increased from 1 to 1.5 l per 24 h; other interventions included oral administration of glucose (OG) to normalize glucose levels.

the data and takes responsibility for the integrity of the data.

Funding: No specific funding was received from any funding bodies in the public, commercial or not-for-profit sectors to carry out the work described in this manuscript.

Disclosure statement: The authors have declared no conflicts of interest.

Linda C. A. Drenthen ¹,
Rebecca J. H. M. Verheggen¹ and
Bastiaan E. de Galan¹

¹Department of Internal Medicine, Division of Diabetology, Radboud University Medical Center, Nijmegen, The Netherlands

Accepted 7 March 2019

Correspondence to: Linda C. A. Drenthen, Department of Internal Medicine 463, Radboud University Medical Center, PO Box 9101, 6500 HB Nijmegen, The Netherlands.
E-mail: lcadrenthen@gmail.com

References

- 1 Tarasova VD, Zena M, Rendell M. Artfactual hypoglycemia: an old term for a new classification. *Diabetes Care* 2014;37:e85–6.
- 2 Cryer PE, Axelrod L, Grossman AB *et al.* Evaluation and management of adult hypoglycemic disorders: an Endocrine Society Clinical Practice Guideline. *J Clin Endocrinol Metab* 2009;94:709–28.
- 3 Bishay RH, Suryawanshi A. Artfactual hypoglycaemia in systemic sclerosis and Raynaud's phenomenon: a clinical case report and short review. *Case Rep Endocrinol* 2016;2016:1.
- 4 Toledo FG, Taylor A. Alternative site testing at the earlobe tip: reliability of glucose measurements and pain perception. *Diabetes Care* 2004;27:616–7.
- 5 Anzalone P. Equivalence of earlobe site blood glucose testing with finger stick. *Clin Nurs Res* 2008;17:251–61.

Rheumatology 2019;58:1692–1694

doi:10.1093/rheumatology/kez135

Advance Access publication 22 April 2019

Abatacept concentrations in maternal serum and breast milk during breastfeeding and an infant safety assessment: a case study

Rheumatology key message

- Abatacept was secreted into breast milk at levels 1/200–1/300 of those in serum.

SIR. The demand for biologic DMARDs has been increasing in female patients with autoimmune diseases such as RA who wish to bear children. While women with RA often show remission during pregnancy, disease exacerbation is common during the post-partum period [1] and it is therefore desirable to ensure that drug treatment is compatible with breastfeeding. To achieve this goal, more data must be accumulated about the safety of anti-rheumatic drugs during pregnancy and breastfeeding [2, 3].

Abatacept is a selective T cell co-stimulation modulator approved in multiple countries for the treatment of RA. It is a soluble fusion protein that consists of the extracellular domain of human cytotoxic T lymphocyte-associated antigen 4 linked to the modified Fc portion of human IgG1 [4]. According to label instructions, abatacept must not be used in pregnancy unless it is imperative, and women in childbearing years should apply effective contraceptive methods throughout treatment and until 14 weeks after their last abatacept dose [5]. Furthermore, due to insufficient data, women should avoid breastfeeding throughout treatment and until 14 weeks after the last abatacept dose [6, 7]. A EULAR task force also indicated that abatacept should be avoided during lactation if another therapy is available to control the disease, but if no other options are available, then lactation should not be discouraged [8].