



Novel dual-action tissue through-the-scope clip for endoscopic closure

Dennis Yang, MD, Kambiz Kadkhodayan, MD, Mustafa A. Arain, MD, Muhammad K. Hasan, MD

INTRODUCTION

Third space endoscopy, also known as submucosal endoscopy, has continued to evolve and expand as a minimally invasive alternative to surgery for the management of various GI diseases. Safe and effective endoscopic mucosal defect closure during many of these procedures is crucial. Conventional through-the-scope (TTS) clips are the most used devices for defect closure given the familiarity and ease of use.¹ However, large mucosal defects can be difficult to close by using conventional TTS clips alone, given the inherent restrictions in clip opening width and inability to approximate large gaps firmly and securely.²

The Dual Action Tissue (DAT) clip (Micro-Tech Endoscopy, USA Inc, Ann Arbor, Mich, USA) is a novel TTS clip designed for endoscopic closure of large mucosal defects. Zhang and colleagues³ recently reported the first experimental study in live pigs evaluating the safety and efficacy of the DAT clip. In all, the DAT clip effectively closed all 13 mucosal defects (mean size of 4.1 ± 0.9 cm) in 5 live pigs. There were no adverse events. At 1-month follow-up, all the mucosal defects had healed with scar formation, and all the DAT clips had spontaneously detached. The authors concluded that the DAT clip was easy to operate, safe, and effective for mucosal defect closure in a live animal model.

The DAT clip was recently approved by the Food and Drug Administration. Performance of the DAT clip has not been evaluated in humans. In this video, we describe the use of this novel TTS clip and share our initial clinical experience.

DAT TTS CLIP

The DAT clip is a 3-arm TTS clip. Compared to conventional TTS clips, the DAT clip has an additional center post or fixed column in the middle position (Fig. 1; Video 1, available online at www.giejournal.org). The DAT clip catheter is 2.9 mm wide and must be inserted through an endoscope with a working channel inner diameter of 3.2 mm and above. The 2 arms of the DAT clip operate independently of each other, with an overall maximum opening width of 15 mm and a 60-degree angle. Opening

and closing of each arm is controlled by the 2 color-coded handles, which facilitates distinguishment of the clip arms during operation (Fig. 1). The current version of the DAT clip is not rotatable. Although the price for the DAT clip has not been determined, it is expected to be priced comparable to 2 to 3 conventional TTS clips.

Figure 2 illustrates the operation of the DAT clip using an inanimate model. The arm on one side of the DAT clip is opened to clamp the edge of the defect. The clamped mucosa is pulled close to the other side of the defect. The second arm of the DAT is then opened to clamp the opposite edge. Once both edges of the defect are secured by the arms of the DAT clip, the clip can be deployed by firmly pressing and releasing both handles simultaneously.

CASE PRESENTATION

A 67-year-old man with medical history significant for bilateral lung transplant, GERD, and severe postsurgical gastroparesis was referred for gastric peroral endoscopic myotomy (G-POEM). Following uneventful completion of the G-POEM, we proceeded with endoscopic closure of the 25-mm mucosal entry incision in the gastric antrum.

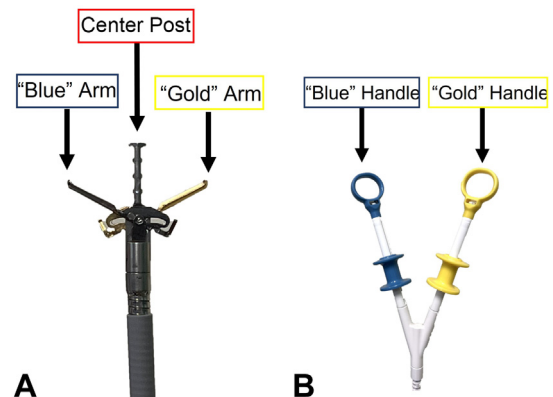


Figure 1. A, The Dual Action Tissue clip has a center post in addition to 2 clip arms that can open and close independently of one another. **B,** Opening and closing of each arm is controlled by 2 color-coded handles, enabling distinguishment of the arms during operation.

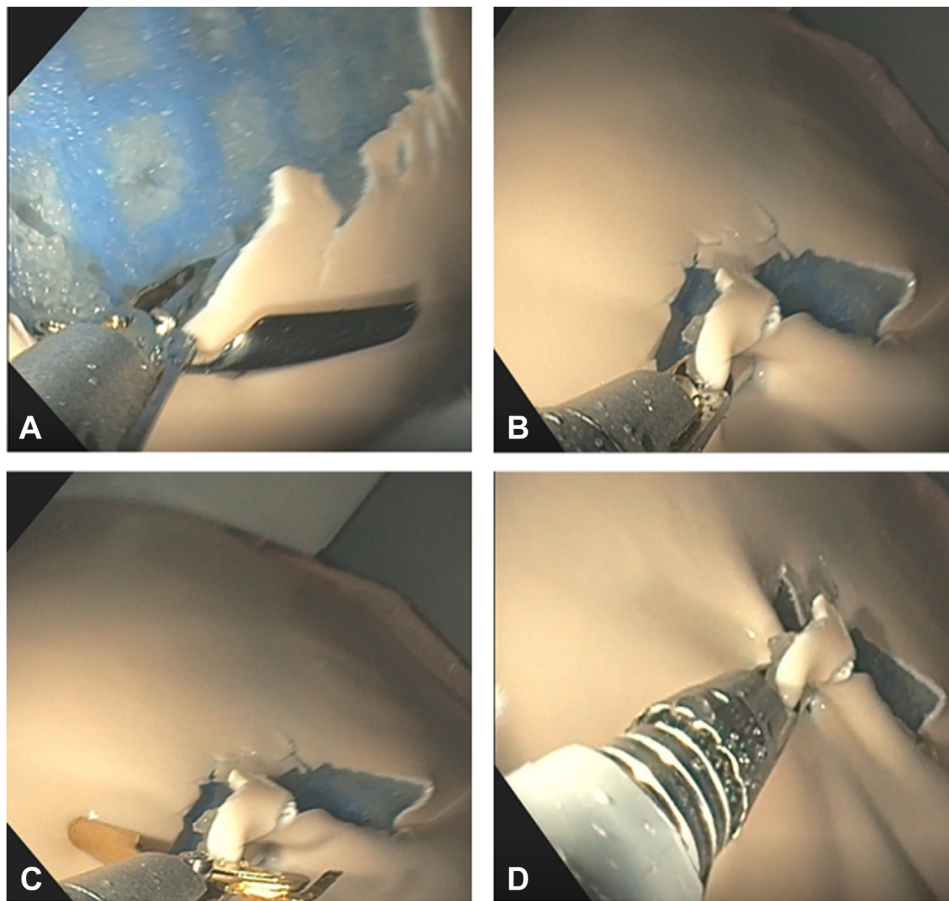


Figure 2. **A**, The arm of one side of the Dual Action Tissue clip is opened to clamp the edge of the defect. **B**, The clamped mucosa is approximated toward the other side of the defect. **C**, The second arm of the Dual Action Tissue clip is used to clamp the opposite edge. **D**, Both edges are secured before clip deployment.

The independent dual-action arms of the DAT clip allowed easy grasping and approximation of the mucosal edges (Fig. 3A). A total of 3 DAT clips were placed along the lateral edges and the middle of the mucosal incision with the goal of reducing the gap between the incision margins (Fig. 3B). Once this was achieved, the remainder smaller gaps were easily closed by using conventional TTS clips (Fig. 3C).

ADVERSE EVENTS AND TROUBLESHOOTING

We have not encountered any adverse events in our first 9 cases using the DAT clip in humans. From our experience, we recommend avoiding bridging very wide gaps to reduce the tension exerted on the tissue from the closed clip and avoid inadvertent mucosal tearing. Similar to the operation of other conventional TTS clips, optimizing scope position and minimizing looping facilitates easy advancement and opening of the DAT clip arms.

SUMMARY

The DAT clip is a novel TTS clip with dual independent arm action, which allows secure grasping of tissue at one edge of the mucosal defect followed by approximation to the other side of the defect prior to clip deployment. This unique feature facilitates secure closure of mucosal defects larger than 2 cm, which can be technically challenging with currently available TTS clips. Additional studies are needed to establish the safety and efficacy of the DAT clip for endoscopic closure in the GI tract.

DISCLOSURES

Dr Yang is a consultant for Olympus, Fujifilm, Apollo Endosurgery, Medtronic, and Microtech. Dr Arain is a consultant for Boston Scientific, Olympus, Cook Medical and Medtronic. Dr Hasan is a consultant for Boston Scientific and Olympus. Dr Kadkbodayan disclosed no financial relationships.

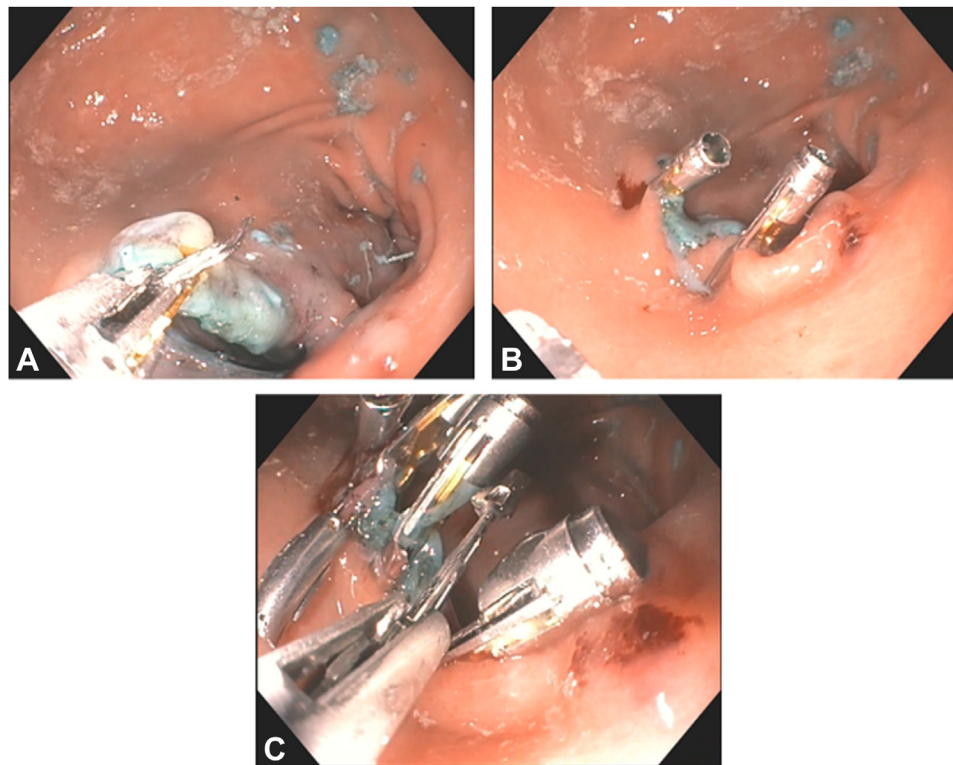


Figure 3. **A**, The dual-action independent arms of the Dual Action Tissue clip facilitate tissue manipulation and approximation prior to clip deployment. **B**, Placement of the Dual Action Tissue clips at the ends of the mucosal incision narrowed the gap between the incision edges. **C**, The remainder of smaller gaps are easily closed with conventional through-the-scope clips.

Abbreviations: DAT, Dual Action Tissue; G-POEM, gastric peroral endoscopic myotomy; TTS, through-the-scope.

REFERENCES

1. Chuttani R, Barkun A, Carpenter S, et al. Technology Assessment Committee. Endoscopic clip application devices. *Gastrointest Endosc* 2006;63:746-50.
2. Wang TJ, Aihara H, Thompson AC, et al. Choosing the right through-the-scope clip: a rigorous comparison of rotatability, whip, open/close precision, and closure strength (with videos). *Gastrointest Endosc* 2019;89:77-86.
3. Zhang Q, Jin H, Shen Z, et al. Novel through-the-scope twin clip for the closure of GI wounds: the first experimental survival study in pigs (with videos). *Gastrointest Endosc* 2021;94:850-8.

Center for Interventional Endoscopy, AdventHealth, Orlando, Florida.

Copyright © 2022 American Society for Gastrointestinal Endoscopy. Published by Elsevier Inc. This is an open access article under the CC BY-NC-ND license (<http://creativecommons.org/licenses/by-nc-nd/4.0/>).

<https://doi.org/10.1016/j.vgje.2022.07.004>