



Tuberculosis-Infected Giant Bulla Treated by Percutaneous Drainage Followed by Obliteration of the Pulmonary Cavity Using Talc: Case Report

Jeongwon Heo, M.D.^{1,2}, So Hyeon Bak, M.D., Ph.D.³, Se Min Ryu, M.D., Ph.D.⁴, Yoonki Hong, M.D.^{1,2}

¹Department of Internal Medicine, Kangwon National University Hospital; Departments of ²Internal Medicine, ³Radiology, and ⁴Thoracic and Cardiovascular Surgery, Kangwon National University School of Medicine, Chuncheon, Korea

ARTICLE INFO

Received August 11, 2020
Revised October 26, 2020
Accepted October 26, 2020

Corresponding author

Yoonki Hong
Tel 82-33-258-9364
Fax 82-33-258-2404
E-mail h-doctor@hanmail.net
ORCID
<https://orcid.org/0000-0002-1607-6777>

Tuberculosis (TB)-infected giant bullae are rare. A 55-year-old man was referred when an infected bulla did not respond to empirical treatment. Computed tomography showed a giant bulla in the right upper lobe with an air-fluid level and surrounding infiltrate. Sputum culture, acid-fast bacilli (AFB) stain, and polymerase chain reaction (PCR) for TB were negative. Percutaneous drainage of the bullous fluid was performed. AFB stain and PCR were positive in the drained fluid. The patient was given anti-TB drugs and later underwent obliteration of the pulmonary cavity using talc. To summarize, we report a patient with a TB-infected giant bulla that was treated successfully with anti-TB drugs and obliteration of the pulmonary cavity using talc.

Keywords: Bullae, Tuberculosis, Case report

Case report

A 55-year-old man was referred to Kangwon National University Hospital with an infected bulla that did not respond to empirical treatment. He was a current smoker with a history of 70 pack-years. The patient complained of worsening dyspnea beginning 4 months earlier, and fever and productive cough beginning 4 weeks previously. He was treated empirically with amoxicillin-clavulanate and levofloxacin at a local hospital for 2 weeks with a diagnosis of pneumonia. The acid-fast bacillus (AFB) stain and culture at admission were negative. He was discharged from that hospital after clinical improvement, but his symptoms worsened within a few days after discharge; he had dyspnea and productive cough.

At the time of the initial presentation, he had a blood pressure of 110/70 mm Hg, pulse rate of 98 beats/min, respiratory rate of 20 breaths/min, temperature of 36.9°C, and peripheral oxygen saturation of 93% in room air. He was alert and oriented. He had scale III breathing symptoms according to the modified Medical Research Council dyspnea scale. There were decreased breath sounds in the

right upper lung, with no wheezing, and his heart sounds were regular.

The results of laboratory tests were as follows: white blood cell (WBC) count, $10.8 \times 10^3/\mu\text{L}$ (reference range, $3.8\text{--}10.0 \times 10^3/\mu\text{L}$); hemoglobin, 9.8 g/dL (range, 13.3–16.5 g/dL); platelet count, $405 \times 10^3/\mu\text{L}$ (range, $140\text{--}400 \times 10^3/\mu\text{L}$); C-reactive protein, 3.0 mg/dL (range, 0.0–0.5 mg/dL); aspartate aminotransferase, 21 U/L (range, 0–34 U/L); alanine aminotransferase, 24 U/L (range, 10–49 U/L); lactate dehydrogenase (LDH), 683 U/L (range, 208–378 U/L); and procalcitonin, 0.08 ng/mL (range, 0.0–0.1 ng/mL).

Chest radiography and computed tomography (CT) revealed a thin-walled cavitary lesion with an air-fluid level in the right upper hemithorax (Figs. 1, 2). Comparing the chest radiograph taken at admission with a radiograph taken 9 days earlier, the amount of fluid had increased markedly. We thought that an antibiotic-resistant organism was present or that the previous period of antibiotics was insufficient. Piperacillin-tazobactam and ciprofloxacin were given empirically after sputum and blood cultures, AFB staining and culture, and polymerase chain reaction (PCR) for tuberculosis (TB) were performed. No specific



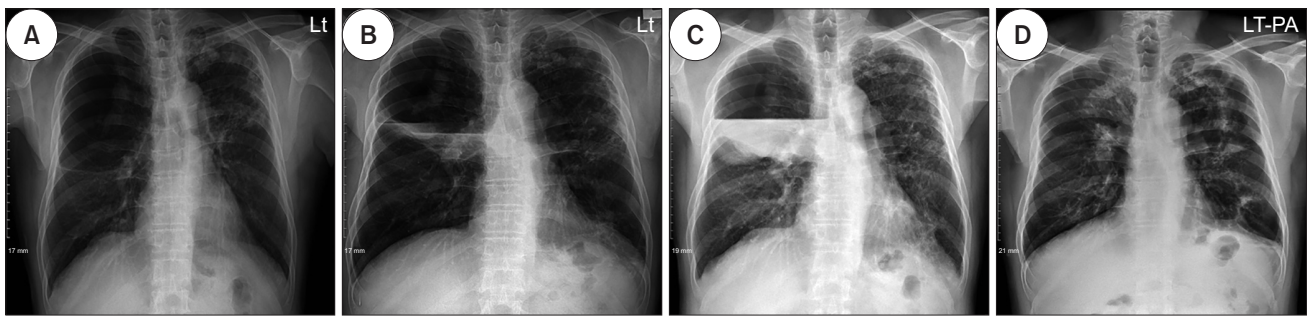


Fig. 1. Changes in chest radiographs over time. (A) Two years before admission, a giant bulla occupied more than half of the right upper hemithorax; (B) 9 days before admission, a chest radiograph at another hospital showed an air-fluid level within the bulla; (C) the amount of fluid in the bulla had increased on the chest radiograph taken at admission; and (D) 7 months after diagnosis, there was near-complete resolution of the infectious bulla after tuberculosis treatment. Lt, left; PA, posteroanterior.

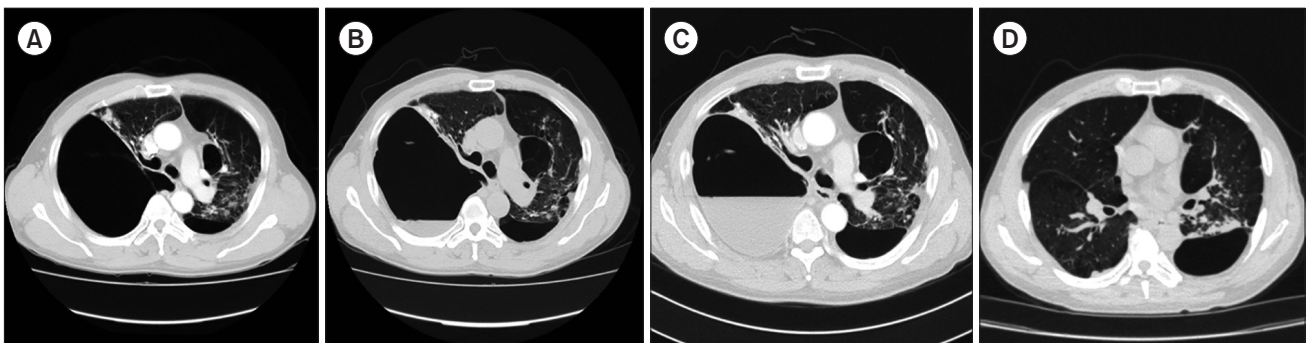


Fig. 2. Changes in chest computed tomography images over time. (A) Two years before admission, there was a large thin-walled subpleural bulla in the right lung; (B) 9 days before admission, there was an air-fluid level within the bulla, suggestive of an infection; (C) on admission, there was increased fluid within the bulla; and (D) after tuberculosis treatment, resolution of the infectious bulla (7 months after diagnosis) was observed.

findings were found in sputum or blood cultures, and the AFB stain/culture and PCR were negative for TB. Despite the use of antibiotics for 2 weeks, there was no improvement or deterioration. Chest CT was performed (Fig. 2C).

Percutaneous drainage (PCD) of the bullous fluid was performed under bedside ultrasonography guidance to determine the antibiotic sensitivity of the infecting organism. A 14F chest tube (Thal-Quick Chest Tube; Cook Medical, Bloomington, IN, USA) was placed in the cavity under ultrasonography and attached to an underwater seal drainage unit. Initially, 300 mL of yellowish turbid fluid was drained with air leakage.

Fluid analysis revealed the following findings for the drained fluid: pH, 7.103; LDH, 15,716 U/L; glucose, 4 mg/dL; protein, 2,648 mg/dL; WBC, 36,850 cells/ μ L (70% polymorphonuclear cells); and adenosine deaminase, 207 U/L. The drained fluid was also positive for AFB and TB PCR.

Anti-TB drugs were started. The patient's symptoms improved rapidly after treatment with the PCD and anti-TB drugs. Forty-five days after the chest tube was inserted, the

daily drainage dropped to 10–30 mL.

Talc was administered through a 14F chest tube before chest tube removal. To rule out the presence of a bulla-bronchus fistula and prevent the sclerosant from spreading to the contralateral lung, the patient was instilled with a small amount of normal saline (less than 5 mL) through the chest tube before sclerosant instillation. There were no symptoms or signs of aspiration. Then the patient was slowly instilled with 1 g of sterile talc (STERITALC; Novatech, La Ciotat, France) suspended in 15 mL of normal saline through the chest tube. During the talc slurry procedure, the patient was positioned in the right-down decubitus position and the chest tube was clamped. Chest CT showed marked contraction and shrinkage of the bullous cavity. The chest tube was removed from the patient without complications. The patient was discharged 2 months after chest tube insertion, and completed 6 months of anti-TB drugs as an outpatient. The TB-infected giant bulla was treated successfully and the right-deviated trachea normalized anatomically (Fig. 2D).

The patient provided written informed consent for the publication of his clinical details and images.

Discussion

Bullae are defined as air spaces in the lungs, measuring more than 1 cm in diameter when distended, while giant bullae occupy at least 30% of the hemithorax [1]. The general management of giant bullae involves treating the underlying chronic obstructive pulmonary disease, and bullectomy, lung volume reduction surgery, and lung transplantation in the management of advanced emphysema play important roles [2]. Patients with giant bullae occasionally develop multiple infections [3,4]. The clinical manifestations may include fever, cough, purulent sputum, dyspnea, and pleuritic chest pain. Laboratory findings may include leukocytosis and positive sputum cultures. The diagnosis of an infected bulla is based on clinical evidence of respiratory infection, the absence of another source, and the presence of a new air-fluid level in a bulla. Although the diagnosis of infected bullae has been reported, TB as a causative pathogen is rare and there have been no reports of the successful treatment of TB-infected giant bullae with anti-TB drugs and obliteration of the pulmonary cavity using talc.

Giant bullae typically develop as a consequence of cigarette smoking, although some are idiopathic and others have less common associations. It is difficult to accurately determine the natural history of these bullae, but their enlargement causes symptom exacerbation and mechanical disturbance of ventilation [5]. Patients with giant bullae occasionally develop superimposed infections within 1 or more bullae without evidence of adjacent pneumonitis on imaging [3,4]. Giant bullae, which are rarely confused with pneumothorax, cause symptoms such as dyspnea and can have a variety of complications. Infection with *Mycobacterium tuberculosis*, *Mycobacterium intracellulare*, or methicillin-resistant *Staphylococcus aureus* that is unresponsive to empirical antibiotics can cause difficulties for clinicians and patients [6-8]. Our patient also had an infected bulla that did not respond to empirical antibiotics. The empirical antibiotics used to treat pneumonia, including levofloxacin, improved the patient's symptoms and signs, but delayed the time to isolate bacteria by PCD of the bullous fluid. If PCD had been performed before the antibiotic escalation, TB might have been diagnosed about 2 weeks earlier. However, the patient's vital signs were stable at that time, and we wanted to give the antibiotics sufficient time to have an effect on the infected bulla.

PCD was started 14 days after escalating the antibiotics. A small tube (10F-14F) is usually adequate for draining pus. Here, we used a set of chest tubes (14F, Thal-Quick Chest Tube; Cook Medical) that can be utilized for the Seldinger technique, and we were able to insert chest tubes of the desired diameter into the bulla [8].

TB-infected bullous fluid differs from that of tuberculous pleurisy or pericarditis. Neutrophil dominance and extremely low glucose levels are also uncommon features of the fluid analysis. There have been reports of neutrophil dominance and extremely low glucose in TB pleurisy. However, no case series has conducted fluid analyses of TB-infected bullae.

The patient's condition is the indication for surgical intervention in giant bullae. Surgical intervention is usually performed in patients with dyspnea or complications such as pneumothorax or prolonged air leakage after tube insertion [9]. In our case, the patient was reluctant to undergo a surgical intervention, so we performed medical obliteration of the pulmonary cavity using talc. However, direct talc slurry instillation into the pulmonary cavity may cause potentially fatal side effects such as acute respiratory distress syndrome [10]. Therefore, in patients with limitations for surgery, our method can be used carefully considering the patient's age and general condition.

There are no guidelines on the duration of anti-TB drug use for a TB-infected giant bulla. We treated our patient for 6 months, based on standard therapy for pulmonary TB. There has been no recurrence of TB after 2 years of follow-up.

We report a case of a TB-infected giant bulla that was treated by PCD followed by late obliteration of the pulmonary cavity using talc. To the best of our knowledge, this is the first report of a TB-infected giant bulla treated with obliteration of the pulmonary cavity. As in this case, anti-TB drugs for 6 months and PCD followed by obliteration of the pulmonary cavity using talc may be a good option for treating TB-infected giant bullae in patients with limitations for surgery.

Conflict of interest

No potential conflict of interest relevant to this article was reported.

Acknowledgments

This study was supported by 2018 Research Grant from Kangwon National University.

ORCID

Jeongwon Heo: <https://orcid.org/0000-0001-7694-6730>

So Hyeon Bak: <https://orcid.org/0000-0003-1039-7016>

Se Min Ryu: <https://orcid.org/0000-0003-2290-5778>

Yoonki Hong: <https://orcid.org/0000-0002-1607-6777>

References

1. Sharma N, Justaniah AM, Kanne JP, Gurney JW, Mohammed TL. *Vanishing lung syndrome (giant bullous emphysema): CT findings in 7 patients and a literature review.* J Thorac Imaging 2009;24:227-30.
2. Palla A, Desideri M, Rossi G, et al. *Elective surgery for giant bullous emphysema: a 5-year clinical and functional follow-up.* Chest 2005; 128:2043-50.
3. Stern EJ, Webb WR, Weinacker A, Muller NL. *Idiopathic giant bullous emphysema (vanishing lung syndrome): imaging findings in nine patients.* AJR Am J Roentgenol 1994;162:279-82.
4. Chandra D, Soubra SH, Musher DM. *A 57-year-old man with a fluid-containing lung cavity: infection of an emphysematous bulla with methicillin-resistant Staphylococcus aureus.* Chest 2006;130:1942-6.
5. Kayawake H, Chen F, Date H. *Surgical resection of a giant emphysematous bulla occupying the entire hemithorax.* Eur J Cardiothorac Surg 2013;43:e136-8.
6. Johnson MK, Smith RP, Morrison D, Laszlo G, White RJ. *Large lung bullae in marijuana smokers.* Thorax 2000;55:340-2.
7. Ferreiro L, Suarez-Antelo J, Valdes L. *Pleural procedures in the management of malignant effusions.* Ann Thorac Med 2017;12:3-10.
8. Wali SO, Shugaeri A, Samman YS, Abdelaziz M. *Percutaneous drainage of pyogenic lung abscess.* Scand J Infect Dis 2002;34:673-9.
9. Snider GL. *Reduction pneumoplasty for giant bullous emphysema: implications for surgical treatment of nonbullous emphysema.* Chest 1996;109:540-8.
10. Brant A, Eaton T. *Serious complications with talc slurry pleurodesis.* Respiriology 2001;6:181-5.