

ALTERNATE FORMAT RESEARCH ARTICLE

Locus coeruleus in the pathogenesis of Alzheimer's disease: A systematic review

Yuqing Chen¹ | Teng Chen² | Ruihua Hou³

¹ School of Clinical Medicine, Addenbrooke's Hospital, University of Cambridge, Cambridge, UK

² Department of Neurosurgery, Qilu Hospital of Shandong University, Jinan, Shandong, China

³ Clinical and Experimental Sciences, Faculty of Medicine, University of Southampton, Southampton, UK

Correspondence

Yuqing Chen, School of Clinical Medicine, Addenbrooke's Hospital, University of Cambridge, Hills Road, Cambridge, CB2 0SP, UK. Email: Yc501@cam.ac.uk

Abstract

The locus coeruleus (LC) is a nucleus in the brain stem producing noradrenaline. While cognitive decline in Alzheimer's disease (AD) has primarily been related to cholinergic depletion, evidence indicates extensive LC degeneration as its earliest pathological marker. The current study aimed to systematically evaluate current evidence investigating the role of the LC in the pathogenesis of AD. A systematic search of the literature was performed on electronic databases including PubMed and Web of Science. Twelve animal, human *post mortem*, and human imaging studies were included in this review. Screening, data extraction, and quality assessment were undertaken following Preferred Reporting Items for Systematic Reviews and Meta-Analyses guidelines for preferred reporting of systematic reviews. Significant associations were identified between LC changes and cognitive decline. Significant reductions in fiber density, neuronal number, and LC volume were seen to correlate with other pathological degenerative markers. Current evidence indicates an important role of the LC in pathogenesis of AD and suggests its potential in both diagnosis and treatment of AD. This systematic review advances our understanding of the role of the LC in AD by synthesizing available evidence, identifying research gaps, highlighting methodological challenges, and making recommendations for future work.

KEYWORDS

Alzheimer's disease, locus coeruleus, neuromelanin-sensitive magnetic resonance imaging, noradrenaline, norepinephrine, systematic review

1 | NARRATIVE

1.1 | Introduction

The locus coeruleus (LC) is located in the posterior area of the pons in the lateral floor of the fourth ventricle. The name originates from the Latin word for "blue spot," which arises from the pigment in its cells.¹ It is the major site of synthesis and secretion of the catecholamine neurotransmitter noradrenaline and is therefore also known as a noradren-

ergic cell group.² The LC has >50% of the noradrenergic neurons in the entire central nervous system (CNS). The nucleus has widespread projections that innervate just about every part of the brain: the spinal cord, cerebellum, hypothalamus, thalamic relay nuclei, amygdala, basal telencephalon, and cortex.¹

Previous studies of Alzheimer's disease (AD) pathology have mainly focused on the role of the hippocampus on cognition but have largely neglected the LC. LC cells are involved in the regulation of attention, arousal, and sleep-wake cycles.¹ The noradrenaline (NA) released from

This is an open access article under the terms of the [Creative Commons Attribution-NonCommercial-NoDerivs](https://creativecommons.org/licenses/by-nc-nd/4.0/) License, which permits use and distribution in any medium, provided the original work is properly cited, the use is non-commercial and no modifications or adaptations are made.

© 2022 The Authors. *Alzheimer's & Dementia: Diagnosis, Assessment & Disease Monitoring* published by Wiley Periodicals, LLC on behalf of Alzheimer's Association

neurons in the LC has an excitatory effect on the hippocampus and cortex, so this region is also important for cognitive functions such as learning and memory.³ The loss of neurons in the LC and thalamic relay nuclei has been demonstrated to be a pathological characteristic of AD. Another study reported degeneration and enlarged cell bodies, and a significant reduction (50%) in cell number, of LC cells in people with AD compared to those without AD.⁴

Recent research has found extensive LC degeneration and NA depletion among the earliest pathologies in AD. Evidence indicates that restoration of NA slows neurodegeneration in animal models. However, the contribution of the LC and NA to cognitive decline in disease progression in AD has been underappreciated and underinvestigated due to methodological difficulties of directly measuring LC activity. Recent imaging work suggests that direct visualization of the LC degeneration is possible. The work of detection of LC degeneration by neuroimaging has important implications for our understanding of the role of the LC in disease progression. This has potential implications for the development of new treatment for patients with AD targeting the locus coeruleus-noradrenergic (LC-NA) pathway to restore NA, increase NA transmission, and reverse effects on cognition.

1.1.1 | The LC-NA system in AD

The LC is the major source of NA, a neuromodulator that has a key role in cognition, mood, and behavior. While cognitive decline in AD has primarily been related to dysfunction within the cholinergic system in the nucleus basalis, there is considerable research evidence that dysfunction in the LC is important also.

This evidence indicates that there is extensive LC degeneration in AD⁵ and that it is among the earliest pathologies,⁶ with *post mortem* data indicating that tau deposition in the LC may be the first identifiable pathology of AD.⁷ The loss of LC neurons in AD is greater than that observed in normal aging and interestingly there is significantly more neuron loss from the LC than cholinergic neuron loss in the nucleus basalis.⁸ It has been reported that as pathological changes in the LC occur early in AD, they may be related to the early cognitive changes in the disorder.⁹ LC degeneration is progressive throughout the course of the illness and there is a positive correlation between the duration of illness and the magnitude of LC neuron loss.¹⁰ Furthermore, there are positive correlations between the magnitude of LC neuron loss and dementia severity.¹¹ Therefore, the early vulnerability of the LC to AD is of considerable clinical significance, as this raises the possibility that the changes of the LC activity may provide early detection markers to assist clinical diagnosis.

Alongside the reduced LC neuron density, mean brain NA concentration is lower in AD than in healthy controls¹² and a reduced cortical NA level has also been found.¹³ Experimental research indicates that loss of NA incites a neurotoxic proinflammatory condition, reduces amyloid beta (A β) clearance, and negatively impacts cognition—recapitulating key aspects of AD.¹⁷ A number of studies have demonstrated significant correlations between LC neuron loss, decreased cortical NA levels, and severity and duration of dementia in

RESEARCH IN CONTEXT

- 1. Systematic Review:** A systematic search of the literature was performed on online databases including PubMed and Web of Science. This included studies published in English before December 2019. The Population, Intervention, Comparison, Outcomes and Study framework was used to guide the search strategy. Studies selected in this review included animal, human *post mortem*, and human *imaging* studies. Studies were included based on the outlined inclusion/exclusion criteria.
- 2. Interpretation:** To our knowledge, this is the first systematic review to investigate the role of the locus coeruleus (LC) in the pathogenesis of Alzheimer's disease (AD) patients. Analysis of animal, human *post mortem*, and human imaging studies strongly indicates a link between LC changes and cognitive decline. Significant reductions in fiber density, neuronal number, and LC volume were seen to correlate with other pathological degenerative markers. This leads to the potential implications in the use of the LC in both diagnosis and treatment of AD. These results suggest that AD patients may benefit from therapies that modulate levels of noradrenalin and serotonin, presenting a possible window for effective treatment and the identification of potential therapeutic targets prior to the onset of cognitive decline. This systematic review advances our understanding of the role of the LC in AD by synthesizing available evidence, identifying research gaps, highlighting methodological challenges, and making recommendations for future work.
- 3. Future Directions:** Data from this systematic review can be used to inform future work, in which imaging techniques can be used to collect biological and physiological markers of LC activity, which can then be developed for disease diagnosis, and for monitoring of preventative and therapeutic targets for AD. Future research directions include clinical trials of noradrenaline (NA) pathway targeting pharmacological therapies to provide proof-of-concept. Such research explores the potential for future intervention strategies, such as the use of pharmacotherapeutic interventions targeting the locus coeruleus-noradrenergic (LC-NA) pathway to restore NA, increase NA transmission, and reverse effects on cognition, which may lead to changes in treatment approaches for patients with AD.

AD.¹⁰ Neurofibrillary changes in the LC have also been found to occur in mild cognitive impairment (MCI).⁹ Therefore, the LC-NA pathway could potentially be an early pharmacotherapeutic target for treating AD by modifying tau deposition.

1.1.2 | LC and inflammation

A recent Lancet review suggests that AD pathogenesis is not restricted to the neuronal compartment but includes strong interactions with immunological mechanisms in the brain.¹⁴ Emerging evidence suggests that inflammation has a causal role in disease pathogenesis and understanding the control of interactions between the immune system and the nervous system might be key to the prevention or delay of most late-onset CNS diseases. In AD, neuroinflammation is not a passive system activated by emerging senile plaques and neurofibrillary tangles (NFTs), but instead contributes as much (or more) to pathogenesis as do plaques and tangles themselves.¹⁵ The important role of neuroinflammation is supported by published genome-wide association studies (GWAS) of late-onset AD showing that the immune and inflammatory response pathway is the most substantial, accounting for 11 of the 22 genes identified to date with a rare mutation in receptor expression on myeloid cells 2, giving a 3-fold increase in the risk of AD.^{16–20}

NA, in addition to its role as a neurotransmitter, has potent anti-inflammatory, anti-oxidative, neurotrophic, and neuroprotective actions.²¹ NA released from LC projections acts on adrenergic receptors expressed on neurons and glial cells, including microglia and astrocytes. While the number of cells in the LC and concentration of NA in the brain decrease during normal aging,²² more pronounced cell loss occurs in patients with AD.⁸ Experimental lesions of the LC in animal models of AD leads to increased inflammation and neuronal damage, and an increase in A β plaque burden.²³ Thus, early degeneration of the LC and subsequent loss of NA-mediated innervation could substantially promote the inflammatory response to any stimulus, including A β . Experimental loss of NA compromises microglial migration and A β phagocytosis *in vivo*, suggesting that a loss of NA increases not only A β deposition, but also inflammation. Remarkably, restoration of NA reverses these effects and slows neurodegeneration in animal models.²⁴

There has been growing research interest in the role of the LC in the progression of AD. However, research work has been conducted using different study designs and methodologies; there has been no work which has reviewed and synthesized all available evidence. This project review aims to address this gap to allow for a more comprehensive understanding of how the LC plays a role in the pathogenesis of AD. The work followed the standard protocol for a systematic review, in which a systematic method was used to identify, select, and critically appraise available studies investigating the role of the LC in AD, and to collect and analyze data from the studies that are selected in this review.

1.2 | Results

Overall, the initial search identified 63 relevant papers. After abstract and title screening and duplicate removal, this was reduced to 41 papers and the subsequent full-text articles were retrieved. After full-text screening, a total of 22 papers were further check for eligibility and a total number of 12 papers were included in this review. Figure 1 pro-

vides a Preferred Reporting Items for Systematic Reviews and Meta-Analyses (PRISMA) flowchart outlining the search strategy and study selection process. Predefined data points were entered into a structured data extraction table. Studies were grouped according to animal studies, human *post mortem* studies, and human imaging studies. Key study characteristics—including study design, sample and age range of subjects, and outcome measures used to identify the LC were extracted from each study. For this review, quantitative measurements of the LC were the primary outcome measures extracted.

1.2.1 | Correlations between LC and other characteristic AD pathologies as observed in animal studies

Table 1 shows data extraction from animal studies. All four animal studies included in this review comprised a cohort study design using the mice/rat model of AD, with subjects housed under standardized conditions and infused with a human tau protein expresser. These were analyzed alongside non-infused wild-type (WT) mice controls, to detect significant differences in LC volume, neuronal numbers, network connections, fiber numbers, and axonal density.

In both the Ghosh et al.²⁵ and the Ahnaou et al.²⁶ studies, the human tau gene was expressed, using TH-Cre rats and tauP301L mice, respectively. Subjects were anaesthetized, brains extracted, and specimens sectioned and cut. Immunohistochemistry (IHC) was performed with suitable staining technique; for example, stereotaxically injected with 1% toluidine blue.

From the IHC, Ghosh et al. found that the axonal density and neuron number within the LC was significantly reduced due to the presence of tau, shown as the purple specks. This suggests that Braak's hypothesis that human AD originates from LC pretangle tau stages is plausible.¹⁴ The cognitive decline shown in odor discrimination tests is similar to human odor deficits seen with aging and preclinical AD. When initiated in aged rats, pretangle stages were seen to progress rapidly and cause significant LC cell loss and these age-related outcomes are associated with more severe learning impairment consistent with memory decline in Braak stages III and IV when LC neurons are also lost.

Ahnaou et al. found robust functional changes in the hippocampus of mice seeded with tau aggregates in the deeper brainstem LC area, with decreased neuronal activity as well as alterations in functional connectivity of specific neural networks. This suggests the potential impairment in synaptic plasticity. Findings of these works highlight to the field the relevance of development of tau pathology in the LC in the early stages of AD and understanding the causal factors for functional deterioration.

Liu et al.²⁷ conducted a randomized, case-controlled study with mice carrying mutant amyloid precursor protein (APP) and presenilin-1 genes (APP/PS1 double transgenic mice). APP/PS1 mice were assigned to two groups according to age: young mice (5–6 months old) and aged mice (16–17 months old), and age-matched WT mice were used as controls. IHC for tyrosine hydroxylase (TH), marker of catecholaminergic neurons in the LC, revealed that APP/PS1 mice had 23% fewer cells in

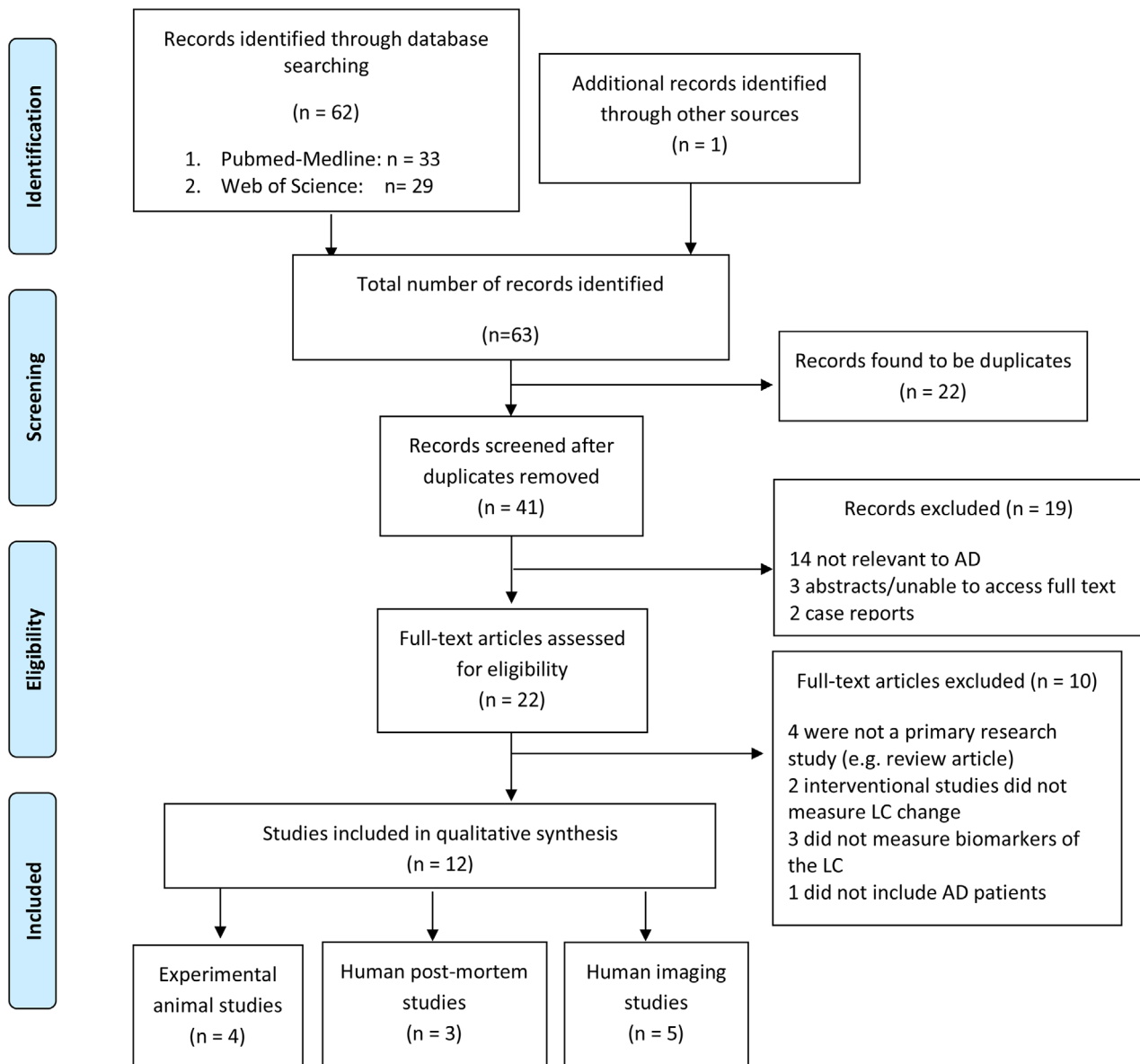


FIGURE 1 PRISMA (Preferred Reporting Items for Systematic Reviews and Meta-Analyses) flow diagram of study selection. AD, Alzheimer's disease; LC, locus coeruleus

the LC and more cell bodies of neurons positive for TH compared to aged WT mice. The pathological alterations observed here reflect those in human brains with AD after death, further suggesting that APP/PS1 double transgenic mice can closely model pathological changes in AD.

Rorabaugh et al.²⁸ used a transgenic rat (TgF344-AD) model that also expressed disease-causing mutant APP/PS1. In these rats, hyperphosphorylated tau was detected in the LC prior to accrual in the entorhinal cortex (EC) or hippocampus, and tau pathology in the LC was negatively correlated with noradrenergic innervation in the EC. They also displayed progressive loss of hippocampal noradrenaline levels and LC fibers. These results, alongside the other experimental studies, indicate that there are existing animal models that can suitably and accurately be used to study and predict LC pathology and dysfunction early in AD progression, suggesting a substantial window of opportunity for development of LC/NA-based therapeutics.

Key findings from all four studies support LC loss in AD. Subjects infused with the tau or amyloid-producing gene presented with significantly reduced axonal/fiber density, neuron number, neural activity, and connectivity compared to WT subjects. This homogeneity allows a reliable conclusion to be made that there is a strong association between LC degeneration and characteristic AD pathology.

1.2.2 | Correlations between LC and other characteristic AD pathologies as observed in human *post mortem* studies

Table 2 shows data extraction from *post mortem* studies. All three *post mortem* studies used stereological analysis of human brainstems conducted by Theofilas et al.,²⁹ Ehrenberg et al.,³⁰ and Kelly et al.³¹

TABLE 1 Data extraction from four selected animal studies

Study	Study design	Population sampled	Age range	Identification of LC	Main findings
Ghosh et al., 2019 ³²	Animal cohort study	56 tau gene-infused rats of 2–3 or 14–16-months	2–16 months	Viral vector carrying human tau gene infused. Anesthetized, brains extracted, cut and IHC performed. LC fiber density, length, cell count calculated using ImageJ analysis software.	Reduced LC axonal density in the olfactory cortex and upregulated β 1-adrenoceptors. LC neuron number was reduced. Human tau appeared in the microglia and cortical neurons.
Ahnaou et al., 2019 ³³	Animal cohort study	16 male transgenic tau-expressing mice	3 months	Anesthetized, IHC technique, stained, specimens of brain sectioned. Equipped with six steel electrodes in frontal cortex. EEG recordings of amplitudes taken, and relative power spectra recorded.	Decreasing neuronal activity in hippocampus of mice seeded with tau in brainstem LC area. Alterations in the functional connectivity of specific functional neural network connections, suggesting impaired synaptic plasticity.
Rorabaugh et al., 2017 ³⁴	Case-controlled animal study	48 TgF344-AD rats/WT littermates	6–16 months	2/3 brain sections analyzed using ImageJ quantification based on size and shape for neurons, glia, and nuclei. Line scan analysis determined fiber density.	LC fibers reduced in TgF344-AD rats. Hyperphosphorylated tau accumulation in LC neurons negatively correlated with LC fiber density in mEC. No neuronal loss.
Liu et al., 2013 ³⁵	Case-controlled animal studies	24 APP/PS1 double transgenic mice/WT mice	5–6 months 16–17 months	Sections of brain tissue containing LC were dehydrated, embedded, cut, and stained with TH, which was a marker for catecholaminergic neurons. Results obtained using investigator software for total quantity and size of positive noradrenergic neurons.	Degenerative alterations found in noradrenergic neurons and fibers in the LC of APP/PS1 (APP and presenilin-1) transgenic mice; 23% fewer cells in the LC compared to aged WT mice, age-related increase in numbers of cell bodies of neurons positive for TH. Mean volume of TH-positive neurons was positively correlated with the total volume of the LC.

Abbreviations: AD, Alzheimer's disease; EEG, electroencephalogram; IHC, immunohistochemistry; LC, locus coeruleus; mEC, medial entorhinal cortex; TH, tyrosine hydroxylase; WT, wild-type.

Brainstems were severed from the brain upon autopsy, fixed samples containing the dorsal pons were cut horizontally and subsequent sections immunostained.

In a study conducted in 2016 by Theofilas et al.,²⁹ sections were also immunostained for TH as well as phosphorylated tau (p-tau), and volume reconstructions made. Stereological analyses of the LC were used to estimate the neuronal population and LC volume. Statistical analyses showed significant reductions in LC volume for each increment of the Braak and Braak (BB) stage. Compared to a subset of individuals at BB stages 0 and I, linear regression models showed no significant association between age and changes in the LC, which is evidence to sug-

gest that normal aging does not affect LC volume and neuron number. Future in vivo imaging studies could determine the predictive value of these changes to AD pathology and, from an early diagnostic perspective, provide a method of screening and monitoring biomarkers to AD.

Tau pathology was investigated in further detail by Ehrenberg et al. in 2017.³⁰ Hyperphosphorylated tau neuronal cytoplasmic inclusions (ht-NCI) are thought to be the best protein correlate of clinical decline in AD. In this study, unbiased stereology was used to quantify the accretion of ht-NCI in the LC and dorsal raphe nucleus (DRN), having conducted immunostaining for p-tau. The number of ht-NCI+ neurons significantly increased by about 1.9 \times between Braak stages 0 to I in LC

TABLE 2 Data extraction from three selected *post mortem* studies

Study	Study design	Population sampled	Age range	Identification of LC	Main findings
Ehrenberg et al., 2017 ³⁶	Cross-sectional	48 controls and early AD stages	44–88 years	Brainstems severed from brain upon autopsy, fixed in 10% neutral buffered formalin, embedded in 8% celloidin, blocks cut horizontally in serial alternating 300 μm stained with galloycyanin-chromalum and 5 \times 60 μm sections immunostained for phosphor-Serine 202-tau. Estimates for neuronal number per nuclei from published parameters. Formula determined total number of ht-NCI+ neurons.	Number of ht-NCI+ LC neurons does not vary with age, sex, years of education, or brain weight. Number of ht-NCI+ LC neurons significant increase (two-fold) from Braak stages 0 to I. A significantly higher percent of LC neuron population with ht-NCI+ neurons detected in late stages than early stages.
Theofilas et al., 2017 ³⁷	Cross-sectional	68 controls and early AD stages	44–96 years	300 μm -thick horizontal histological sections across the LC stained with galloycyanin and immunostained for TH. LC border segmentation comparable to the TH-immunostained sections and brings the advantage of including the TH-negative neurons. Volume reconstructions of the human brainstem (glass) and LC.	As the Braak stage increases by one unit, the LC volume decreases by 8.4%. Neuronal loss started only midway through AD progression. No significant changes in LC volume and population across the age groups, suggesting findings related to progression of AD pathology not normal ageing.
Kelly et al., 2017 ³⁸	Case-controlled	29 subjects who died with an antemortem clinical diagnosis of NCI ($n = 11$), aMCI ($n = 10$), or mild/moderate AD ($n = 8$)	77–96 years	Sections of fixed brainstem samples containing LC immunostained for TH to visualize noradrenergic neurons. Number of neurons determined using microscope coupled to computer-controlled x-y-z motorized stage and high-sensitivity camera.	Significant 30% decrease in number of LC neurons in aMCI compared to NCI cases, with an additional 25% decrease in AD compared to aMCI. Strong association between reduction in LC neuron number and decline in cognitive status.

Abbreviations: AD, Alzheimer's disease; aMCI, amnesic mild cognitive impairment; AITH, tyrosine hydroxylase; ht-NCI, hyperphosphorylated tau neuronal cytoplasmic inclusions; LC, locus coeruleus; TH, tyrosine hydroxylase.

($P = .02$), significant difference between Braak stage I and II were not detected. Also, the number of ht-NCI+ neurons remained stable in DRN between all stages 0 and II. The ht-NCI increases along AD progression on both nuclei, but quantitative changes in LC precede DRN changes. This offers more precise understanding of the early pathological framework by which AD progresses and quantifying ht-NCI burden in LC and DRN across early disease stages may contribute to a framework for more effective treatment.

In line with the above *post mortem* work, Kelly et al. used immunostaining of TH to visualize noradrenergic neurons and determine the number of LC neurons.³¹ A significant 30% decrease in number of LC neurons was found in MCI subjects compared to healthy controls, with an additional 25% decrease in AD compared to MCI. A strong associa-

tion was found between reduction in LC neuron number and reduction in cognitive decline.

Characterizing these differences in brain stem structures affected early in AD can help build the foundation for therapeutic targeting and mechanistic drug development by overcoming the gap in knowledge regarding early AD pathogenesis.

1.2.3 | Significantly reduced LC-contrast ratios in patient groups as observed in human imaging studies

Table 3 shows data extraction from human imaging studies. The contribution of LC degeneration and NA depletion to cognitive decline

TABLE 3 Data extraction from five human imaging studies

Study	Study design	Population sampled	Age range	Identification of LC by NM-MRI	Main findings
Hou et al., 2019 ⁴⁴	Case-controlled, cross-sectional study	22 AD patients (11 mild and 11 moderate) and 22 controls	57–82	LC-CR The average signal intensity of the LC on the left (LLC) and the right (RLC) on the axial slice which was approximately 7 mm below the inferior colliculi was calculated. Contrast ratio was then calculated using the following formula: (mean signal intensity of LC ROI – mean signal intensity of PT ROI)/mean signal intensity of PT ROI.	Significant reduced LC contrast ratio in AD (0.12) compared to controls (0.16), no difference between mild and moderate AD. Significant correlation between MMSE and LC-CR ($P < .01$)
Olivieri et al., 2019 ³⁹	Case-controlled	16 atypical AD, 21 typical AD, and 17 controls	60–75	LC-I T1-weighted images from the lower part of the pons to the upper part of the midbrain, covering the entire LC. a reference region for the normalization of the signal between subjects, which allows the direct comparison of intensity values between subjects. Used in-house software to automatically determine the 10 brightest connected voxels bilaterally, which were considered the LC areas.	The LC-I was lower in the whole AD group compared to controls. The LC-I was also lower in each typical and atypical AD subgroup. There was no statistical difference between typical and atypical AD patients. The LC-I was significantly lower in prodromal and mild demented AD patients compared to controls. No significant correlation with MMSE or amyloid load; but correlation between LC-CR and MMSE in typical AD.
Betts et al., 2019 ⁴⁰	Case-controlled	11 with AD, 16 with MCI, 21 with subjective cognitive decline and 25 controls	Mean age: 68–71	LC-CR quantified using 3D T ₁ -weighted FLASH imaging (0.75 mm isotropic resolution). Bootstrapped Pearson's correlations between LC contrast, CSF amyloid, and tau were performed in 44 individuals with CSF biomarker status.	A significant regional decrease in LC MRI contrast was observed in patients with AD dementia, providing evidence for direct association between LC and CSF biomarkers of AD pathology. A negative association between LC MRI contrast and levels of CSF amyloid but not with CSF tau was found.
Dordevic et al., 2017 ⁴¹	Cross-sectional	10 patients and 10 controls	68–80	LC-CR Visualized using high-resolution T1-TSE. maximum contrast values extracted; ratios determined within each slice by dividing the maximum value of LC with pontine reference. Two contrast ratios for each side of LC for each slice.	The section located 10 millimeters below the inferior colliculus has the highest potential in differentiating between healthy controls and patients, with the contrast-ratio difference between groups of 12.3% and effect size of 1.577. Appears that left side of LC has higher potential in differentiating between healthy controls and patients.

(Continues)

TABLE 3 (Continued)

Study	Study design	Population sampled	Age range	Identification of LC by NM-MRI	Main findings
Takahashi et al., 2015 ⁴²	Case-controlled	22 with AD, 47 with MCI, and 26 controls		LC-CR High resolution T1-TSE. Signal intensities in the LC manually measured and expressed relative to pontine tegmentum (pons) as contrast ratios.	LC-CR significantly reduced in patient groups with AD and MCI, but there was no significant difference between these groups.

Abbreviations: AD, Alzheimer's disease; CSF, cerebrospinal fluid; FLASH, fast low-angle shot; LC, locus coeruleus; LC-CR, LC contrast ratios; LC-I, LC signal intensity; MCI, mild cognitive impairment; MMSE, Mini-Mental State Examination; MRI, magnetic resonance imaging; ROI, region of interest.

in the development and progression AD has been underappreciated and underinvestigated due to methodological difficulties. But recent advances in neuroimaging have offered the opportunity for direct visualization of LC degeneration.

Detection of the LC by neuroimaging has been used by several imaging studies. Five studies were found from the literature search, which all used neuromelanin-sensitive magnetic resonance imaging (NM-MRI).

Olivieri et al.,³² Betts et al.,³³ Dordevic et al.,³⁴ Takahashi et al.³⁵ and Hou et al.⁴⁴ all performed MRI measurements on a Siemens Verio. To visualize the LC, high-resolution T1-TSE NM-sensitive images were acquired perpendicular to the posterior border of the brainstem, from the lower part of the pons to the upper part of the midbrain, covering the entire LC.

All neNM-sensitive images were analyzed, and contrast ratios or intensities compared. This was performed by manually defining regions of interest and use of a reference region for the normalization of the signal between subjects, avoiding any other structure that could be considered "bright" such as the substantia nigra. This normalization allowed the direct comparison of intensity values between subjects. Software was used to automatically determine the brightest connected voxels bilaterally, which were considered the LC areas. The appropriate location of voxels in the LC area was checked visually on each image and data was analyzed using SPSS 24.

Olivieri et al. used the LC signal intensity (LC-I) to assess the LC integrity in AD and controls. All others averaged the left and right values of the LC signal intensity and LC contrast ratios (LC-CR) were calculated using the following equation: $LC-CR = (SI_{LC} - SI_{PT}) / SI_{PT}$, where SI_{LC} is the averaged signal intensity the left and right LC, and SI_{PT} is the signal intensity of the adjacent pons, PT.

LC-CR/LC-I were found to be significantly reduced in patient groups with AD compared to the healthy control group in all six studies. Takahashi et al. found that there was no significant difference in the LC-CR among the AD and MCI groups, suggesting signal attenuation in the LC of patients with AD or with MCI whose pathology may or may not eventually convert to AD.³⁵ Betts et al. observed a significant regional decrease in LC MRI contrast in patients with AD dementia but not MCI.³³ A negative association between LC MRI contrast and levels of cerebrospinal fluid (CSF) amyloid but not with CSF tau was found. These results provide first evidence for a direct association between LC

MRI contrast using in vivo T₁-weighted imaging and CSF biomarkers of AD pathology. Supporting this, Hou et al. found significant reduced LC contrast ratio in AD compared to controls and a significant correlation between Mini-Mental State Examination (MMSE) and LC-CR.⁴⁴ These findings mimic what has been observed in *post mortem* studies, which show a reduction in LC cell count in AD brains compared to those without cognitive impairment.

Dordevic et al. sought to determine the location of the highest LC-to-pons ratio within the LC and results showed that the section located 10 millimeters below the inferior colliculus has the highest potential in differentiating between healthy controls and patients, with the contrast-ratio difference between groups of 12.3% and effect size of 1.577.³⁴ This method is a promising tool to aid AD diagnosis workup for clinical application.

Olivieri et al. found that the LC-I was decreased in AD regardless of typical and atypical presentation.³² In contrast to Betts et al., LC-I between groups varied independent of amyloid load, and these conflicting findings likely reflect the variations between LC segments and relationships with CSF biomarker status. Betts et al., for instance, found no significant associations in the lower LC third with amyloid nor tau. It should also be noted that both studies used different measures of LC and both have a relatively small number of subjects studies, which may also contribute to these different findings. The LC-I was correlated with memory performance of typical AD. This supports a critical role the LC plays in the pathogenesis of AD and may thus be a potential therapeutic target to prevent cognitive decline.

1.3 | Discussion

Preclinical studies suggest the potential for NA-enhancing therapies to reduce neuroinflammation and amyloid burden, and to ameliorate cognitive impairment; clinical observations of AD patients also suggest a potential to impact behavioral symptoms.³⁶ It has even been proposed that compensatory mechanisms for NA depletion may in fact produce an elevated NA in some cases of AD.³⁷ Treatments targeting the LC-NA pathway therefore present a new paradigm for prognosis and therapy, and may have the potential to delay or prevent AD-related pathology.²⁴

These results suggest that AD patients may benefit from therapies that modulate levels of noradrenalin and serotonin, presenting a

possible window for effective treatment and the identification of potential therapeutic targets prior to the onset of cognitive decline.³⁸ Therefore, detection of LC degeneration by neuroimaging has important implications for our understanding of the role of the LC in disease progression and to the development of new pharmacotherapeutic targets. The imaging, inflammatory, and physiological markers can be used for monitoring of these pharmacotherapeutic interventions targeting the LC-NA pathway. Due to the widespread clinical use of drugs with a NA-based mechanism of action in other medical conditions, immediate opportunities to repurpose existing medications for AD will arise. Such drugs could be selective noradrenaline reuptake inhibitors,³⁹ α 2-adrenoceptor antagonists,⁴⁰ and the noradrenaline precursor L-threo-3,4-dihydroxy phenylserine,⁴¹ which increase endogenous NA concentrations, thereby potentially reducing neuroinflammation and providing rescue of microglial functions.

Until relatively recently, drug discovery in the field of AD has been focused on therapies that reduce the levels of soluble or insoluble A β in the brain; however, numerous high-profile late-stage failures in clinical trials have resulted in a shift in focus to reducing the levels of tau in the brain far earlier, in the presymptomatic stage of the disease.⁴² A great deal of work is currently ongoing to investigate biomarkers of deteriorating brain function that could aid early diagnosis and act as indicators of therapeutic efficacy. The back-translational value of using functional biomarkers in preclinical AD drug discovery could be extremely high; the ability to predict whether an experimental therapeutic compound will have a functional benefit in humans before costly clinical testing would save the pharmaceutical industry time and money, and allow scientists to better identify the best compounds to take to the next stage.

While significant correlations are seen between LC pathology and later Braak NFT staging, further studies are warranted to identify and isolate the role of the LC, particularly in early AD progression independent to pathogenesis in other brain regions. This has important implications for developing new treatment targets. In addition, previous studies⁴³ suggest that pathological seeding begins in the EC and spreads to the LC, according to the prion model. Further analysis of tauopathy and quantification of seeding activity may shed greater light on this early phase of AD pathology and neurodegeneration progression.

1.4 | Conclusions

Animal studies and human *post mortem* studies found LC degeneration, marked by significant reductions in fiber density and neuronal number. Human imaging studies of AD patients indicates a significant correlation between LC-CR and cognitive impairment. This suggests the potential for NA-enhancing therapies to reduce neuroinflammation and amyloid burden, and to ameliorate cognitive impairment. All this suggests the possibility that treatments targeting the LC-NA pathway may have the potential to delay or prevent AD-related pathology, proposing a new paradigm for prognosis and therapy.

Detection of LC degeneration by neuroimaging has important implications for our understanding of the role of the LC in disease

progression and to the development of new pharmacotherapeutic targets. Data from this systematic review can be used to inform future work, in which imaging techniques can be used to collect biological and physiological markers of LC activity, which can then be developed for disease diagnosis, and for monitoring of preventative and therapeutic targets for AD. This suggests the potential for future intervention strategies, such as the use of pharmacotherapeutic interventions targeting the LC-NA pathway to restore NA, increase NA transmission, and reverse the effects on cognition, which may lead to changes in treatment approaches for patients with AD.

2 | CONSOLIDATED RESULTS AND STUDY DESIGN

2.1 | Summary of animal studies

All four animal studies included in this review comprised a cohort study design using the mice/rat model of AD, with subjects housed under standardized conditions and infused with a human tau protein expresser. These were analyzed alongside non-infused WT mice controls, to detect significant differences in LC volume, neuronal numbers, network connections, fibre numbers and axonal density. Key findings from all four studies support LC loss in AD. Subjects infused with the tau or amyloid-producing gene presented with significantly reduced axonal/fibre density, neuron number, neural activity and connectivity compared to WT subjects. This homogeneity allows a reliable conclusion to be made that there is a strong association between LC degeneration and characteristic AD pathology.

2.2 | Summary of human *post mortem* studies

All three post-mortem studies used stereological analysis of human brainstems. Brainstems were severed from the brain upon autopsy, fixed samples containing the dorsal pons were cut horizontally, and subsequent sections immunostained. A significant 30% decrease in number of LC neurons was found in MCI subjects compared to healthy controls, with an additional 25% decrease in AD compared to MCI. A strong association was found between reduction in LC neuron number and decline in cognitive decline.

By characterizing these differences in brainstem structures affected early in AD, this can help to build the foundation for therapeutic targeting and mechanistic drug development by overcoming the gap in knowledge regarding early AD pathogenesis.

2.3 | Summary of human *imaging* studies

The contribution of LC degeneration and NA depletion to cognitive decline in the development and progression AD has been underappreciated and under investigated due to methodological difficulties.

But recent advances in neuroimaging have offered the opportunity for direct visualisation of LC degeneration. Detection of the LC by neuroimaging has been used by several imaging studies. Five studies were found from the literature search, which all used NM-MRI. All neuromelanin-sensitive images were analyzed, and contrast ratios or intensities compared. This was performed by manually defining regions of interest and use of a reference region for the normalisation of the signal between subjects.

LC-CR/LC-I were found to be significantly reduced in patient groups with AD compared to the healthy control group in all six studies. These results provide first evidence for a direct association between LC MRI contrast using in vivo T1-weighted imaging and CSF biomarkers of AD pathology. These findings mimic what has been observed in post-mortem studies, which show a reduction in LC cell count in AD brains compared to those without cognitive impairment. Studies also sought to determine the location of the highest LC:pons ratio within the LC demonstrating promise as a tool to aid AD diagnosis.

3 | DETAILED METHODS AND RESULTS

3.1 | Search strategy

The work followed the standard protocol for a systematic review, in which a systematic method was used to identify, select, and critically appraise available studies investigating the role of the LC in AD, and to collect and analyze data from the studies that are selected in this review.

A systematic search of the literature was performed on online databases including PubMed and Web of Science. This included studies published in English before December 2019. The PICOS framework was used to guide the search strategy:

Population and comparison:

- Individuals who meet diagnostic criteria for AD and/or controls
- Animal models of AD and/or controls

Outcomes of interest:

- Measures of LC change

Setting:

- Lab or
- Community or
- Hospital.

Study design:

- Observational longitudinal or
- Cross-sectional or
- Cohort studies.

The search strategy developed from the framework above, is outlined below.

1. Scope search on Medline and Web of Science for studies including keywords: "locus coeruleus[Title] OR locus ceruleus[Title] AND alzheimer's[Title]"
2. Search reference lists of relevant articles to identify appropriate references and journals.
3. Search and review authors known to have conducted research. One author was contacted in the field to obtain unpublished data, which has since been published.⁴⁴

3.2 | Inclusion/exclusion criteria

Studies selected in this review included animal, human *post mortem*, and human imaging studies. Studies were included based on the following criteria:

Inclusion criteria:

- Study design: longitudinal, cross-sectional, or cohort studies;
- Study populations: animal models of AD or patients with AD and/or controls;
- Reported measures of the LC in AD and/or controls;
- Published in English language;
- Full-text paper accessible.

Exclusion criteria:

- There was no measure of the LC loss/change;
- There were no AD models or populations with AD;
- Published in languages other than English;
- Only abstracts accessible.

ACKNOWLEDGMENTS

Ruihua Hou was awarded a pilot project grant from Alzheimer's Research UK (grant reference: ARUK PPG2016A-6) to conduct a case-control study of the locus coeruleus degeneration in Alzheimer's disease.

CONFLICTS OF INTEREST

No conflicts of interest declared. Authors confirm that no consent was necessary.

AUTHOR CONTRIBUTIONS

Yuqing Chen and Ruihua Hou conceived of the idea and designed the outlined search strategy. Yuqing Chen carried out the literature scope search according to inclusion/exclusion criteria. Teng Chen acted as the second reviewer to conduct complete dual review process.

REFERENCES

1. Boron WF, Boulpaep EL. *Medical Physiology*. 2nd ed. Saunders; 2012.

2. Bouret S, Sara SJ. Network reset: a simplified overarching theory of locus coeruleus noradrenaline function. *Trends Neurosci.* 2005;28(11):574-582.
3. German DC, Nelson O, Liang F, et al. The PDAPP mouse model of Alzheimer's disease: locus coeruleus neuronal shrinkage. *J Comp Neurol.* 2005;492(4):469-476.
4. Busch C, Bohl J, Ohm TG, et al. Spatial, temporal and numeric analysis of Alzheimer changes in the nucleus coeruleus. *Neurobiol Aging.* 1997;18(4):401-406.
5. Lyness SA, Zarow C, Chui HC. Neuron loss in key cholinergic and aminergic nuclei in Alzheimer disease: a meta-analysis. *Neurobiol Aging.* 2003;24:1-23.
6. Mann DM, Lincoln J, Yates PO, Stamp JE, Toper S. Changes in the monoamine containing neurons of the human CNS in senile dementia. *Br J Psychiatry.* 1980;136:533-541.
7. Attems J, Thomas A, Jellinger K. Correlations between cortical and subcortical tau pathology. *Neuropathol Appl Neurobiol.* 2012;38:582-590.
8. Zarow C, Lyness SA, Mortimer JA, Chui HC. Neuronal loss is greater in the locus coeruleus than nucleus basalis and substantia nigra in Alzheimer and Parkinson diseases. *Arch Neurol.* 2003;60:337-341.
9. Grudzien A, Shaw P, Weintraub S, Bigio E, Mash DC, Mesulam MM. Locus coeruleus neurofibrillary degeneration in aging, mild cognitive impairment and early Alzheimer's disease. *Neurobiol Aging.* 2007;28:327-335.
10. German DC, Manaye KF, White CL, et al. Disease-specific patterns of locus coeruleus cell loss. *Ann Neurol.* 1992;32:667-676.
11. Bondareff W, Mountjoy CQ, Roth M, et al. Neuronal degeneration in locus coeruleus and cortical correlates of Alzheimer disease. *Alzheimer Dis Assoc Disord.* 1987;1:256-262.
12. Hoogendijk WJ, Feenstra MG, Botterblom MH, et al. Increased activity of surviving locus coeruleus neurons in Alzheimer's disease. *Ann Neurol.* 1999;45:82-91.
13. Matthews KL, Chen CPL-H, Esiri MM, Keene J, Minger SL, Francis PT. Noradrenergic changes, aggressive behavior, and cognition in patients with dementia. *Biol Psychiatry.* 2002;51:407-416.
14. Heneka MT, Carson MJ, El Khoury J, et al. Neuroinflammation in Alzheimer's disease. *Lancet Neurol.* 2015;14:388-405.
15. Zhang B, Gaiteri C, Bodea LG. Integrated systems approach identifies genetic nodes and networks in late-onset Alzheimer's disease. *Cell.* 2013;153:707-720.
16. Harold D, Abraham R, Hollingworth P, et al. Genome-wide association study identifies variants at CLU and PICALM associated with Alzheimer's disease. *Nat Genet.* 2009;41:1088-1093.
17. Lambert JC, Heath S, Even G, et al. and the European Alzheimer's Disease Initiative Investigators. Genome-wide association study identifies variants at CLU and CR1 associated with Alzheimer's disease. *Nat Genet.* 2009;41:1094-1099.
18. Lambert JC, Ibrahim-Verbaas CA, Harold D, et al. Meta-analysis of 74,046 individuals identifies 11 new susceptibility loci for Alzheimer's disease. *Nat Genet.* 2013;45:1452-1458.
19. Hollingworth P, Sweet R, Sims R, et al. Genome-wide association study of Alzheimer's disease with psychotic symptoms. *Mol Psychiatry.* 2012;17:1316-1327.
20. Naj AC, Jun G, Reitz C, et al. Effects of multiple genetic loci on age at onset in late-onset Alzheimer disease: a genome-wide association study. *JAMA Neurol.* 2011;71:1394-1404.
21. O'Donnell ME, Chen YJ, Lam TI, Taylor KC, Walton JH, Anderson SE. Intravenous HOE-642 reduces brain edema and Na uptake in the rat permanent middle cerebral artery occlusion model of stroke. *J Cereb Blood Flow Metab.* 2013;33(2):25-34.
22. Marien MR, Colpaert FC, Rosenquist AC. Noradrenergic mechanisms in neurodegenerative diseases: a theory. *Brain Res Brain Res Rev.* 2004;45:38-78.
23. Heneka MT, Ramanathan M, Jacobs AH, et al. Locus coeruleus degeneration promotes Alzheimer pathogenesis in amyloid precursor protein 23 transgenic mice. *J Neurosci.* 2006;26(5):1343-1354.
24. Chalermphanupap T, Kinkead B, Hu WT, et al. Targeting norepinephrine in mild cognitive impairment and Alzheimer's disease. *Alzheimers Res Ther.* 2013;5:21.
25. Ghosh A, Torraville SE, Mukherjee B, et al. An experimental model of Braak's pretangle proposal for the origin of Alzheimer's disease. *Alzheimers Res Ther.* 2019;11(1):59.
26. Ahnaou A, Walsh C, Manyakov NV, Youssef SA, Drinkenburg WH. Early electrophysiological disintegration of hippocampal neural networks in a novel locus coeruleus tau-seeding mouse model of Alzheimer's disease. *Neural Plast.* 2019;2019:6981268.
27. Liu L, Luo S, Zeng L, Wang W, Yuan L, Jian X. Degenerative alterations in noradrenergic neurons of the locus coeruleus in Alzheimer's disease. *Neural Regen Res.* 2013;8(24):2249-2255.
28. Rorabaugh JM, Chalermphanupap T, Botz-Zapp CA, et al. Chemo-genetic locus coeruleus activation restores reversal learning in a rat model of Alzheimer's disease. *Brain.* 2017;140(11):3023-3038.
29. Theofilas P, Ehrenberg AJ, Dunlop S, et al. Locus coeruleus volume and cell population changes during Alzheimer's disease progression. *Alzheimers Dement.* 2017;13(3):236-246.
30. Ehrenberg AJ, Nguy AK, Theofilas P, et al. Quantifying the accretion of hyperphosphorylated tau in the locus coeruleus and dorsal raphe nucleus: the pathological building blocks of early Alzheimer's disease. *Neuropathol Appl Neurobiol.* 2017;43(5):393-408.
31. Kelly SC, He B, Perez SE, Ginsberg SD, Mufson EJ, Counts SE. Locus coeruleus cellular and molecular pathology during the progression of Alzheimer's disease. *Acta Neuropathol Commun.* 2017;5(1):8.
32. Olivieri P, Lagarde J, Lehericy S, et al. Early alteration of the locus coeruleus in phenotypic variants of Alzheimer's disease. *Ann Clin Transl Neurol.* 2019;6(7):1345-1351.
33. Betts MJ, Cardenas-Blanco A, Kanowski M, et al. Locus coeruleus MRI contrast is reduced in Alzheimer's disease dementia and correlates with CSF A β levels. *Alzheimers Dement (Amst).* 2019;11:281-285.
34. Dordevic M, Müller-Fötti A, Müller P, Schmicker M, Kaufmann J, Müller NG. Optimal cut-off value for locus coeruleus-to-pons intensity ratio as clinical biomarker for Alzheimer's disease: a pilot study. *J Alzheimers Dis Rep.* 2017;1(1):159-167.
35. Takahashi J, Shibata T, Sasaki M, et al. Detection of changes in the locus coeruleus in patients with mild cognitive impairment and Alzheimer's disease: high-resolution fast spin-echo T1-weighted imaging. *Geriatr Gerontol Int.* 2015;15(3):334-340.
36. Katsouri L, Vizcaychipi MP, McArthur S, et al. Prazosin, an $\alpha(1)$ -adrenoceptor antagonist, prevents memory deterioration in the APP23 transgenic mouse model of Alzheimer's disease. *Neurobiol Aging.* 2013;34:1105-1115.
37. Fitzgerald PJ. Is elevated norepinephrine an etiological factor in some cases of Alzheimer's disease? *Curr Alzheimer Res.* 2010;7:506-516.
38. Morsch R, Simon W, Coleman PD. Neurons may live for decades with neurofibrillary tangles. *J Neuropathol Exp Neurol.* 1999;58:188-197.
39. O'Sullivan JB, Ryan KM, Harkin A, Connor TJ. Noradrenaline reuptake inhibitors inhibit expression of chemokines IP-10 and RANTES and cell adhesion molecules VCAM-1 and ICAM-1 in the CNS following a systemic inflammatory challenge. *J Neuroimmunol.* 2010;220(1-2):34-42.
40. Kalinin S, Gavriluk V, Polak PE, et al. Noradrenaline deficiency in brain increases beta-amyloid plaque burden in an animal model of Alzheimer's disease. *Neurobiol Aging.* 2007;28:1206-1214.
41. Kalinin S, Polak PE, Lin SX, Sakharkar AJ, Pandey SC, Feinstein DL. The noradrenaline precursor L-DOPS reduces pathology in a mouse model of Alzheimer's disease. *Neurobiol Aging.* 2012;33:1651-1663.
42. Cummings JL, Morstorf T, Zhong K. Alzheimer's disease drug-development pipeline: few candidates, frequent failures. *Alzheimers Res Ther.* 2014;6(4):37.

43. Kaufman SK, Del Tredici K, Thomas TL, Braak H, Diamond MI. Tau seeding activity begins in the transentorhinal/entorhinal regions and anticipates phospho-tau pathology in Alzheimer's disease and PART. *Acta Neuropathol.* 2018;136(1):57-67.
44. Hou R, Beardmore R, Holmes C, Osmond C, Darekar A. A case-control study of the locus coeruleus degeneration in Alzheimer's disease. *Eur Neuropsychopharmacol.* 2021;43:153-159.

How to cite this article: Chen Y, Chen T, Hou R. Locus coeruleus in the pathogenesis of Alzheimer's disease: A systematic review. *Alzheimer's Dement.* 2022;8:e12257. <https://doi.org/10.1002/trc2.12257>