



## Surgical technique

# A Modified Surgical Technique of Patellar Tendon Reconstruction in Total Knee Arthroplasty Using Achilles Tendon Allograft

Glenys Poon, MBBS<sup>a, \*</sup>, Ing How Moo, MBBS, MRCS, MMed<sup>b</sup>,  
Kein Boon Poon, MD, MSc Orthopaedic, FAMS<sup>c</sup>

<sup>a</sup> Department of Orthopaedic Surgery, National University Hospital, Singapore, Singapore

<sup>b</sup> Department of Orthopaedic Surgery, Changi General Hospital, Singapore, Singapore

<sup>c</sup> Department of Orthopaedic Surgery, Sengkang General Hospital, Singapore, Singapore

## ARTICLE INFO

## Article history:

Received 19 July 2021

Received in revised form

7 October 2021

Accepted 9 October 2021

Available online xxx

## Keywords:

Patellar tendon rupture

Extensor mechanism reconstruction

Achilles tendon allograft

Patellar tendon repair

Total knee arthroplasty

## ABSTRACT

Patellar tendon disruption is one of the most dreaded complications after total knee arthroplasty (TKA) impacting joint function and implant longevity. Management of this condition remains controversial, and no one treatment has provided consistent clinical success. Here we propose a modified technique from the standard Achilles allograft procedure to reconstruct a ruptured patellar tendon after TKA. A fresh-frozen Achilles tendon allograft with attached calcaneal bone graft was used. Our technique offers the advantage of a more stable graft fixation by relying on both quadriceps tendon and transosseous patellar fixation and bone-to-bone allograft fixation to the tibial tuberosity. The patient regained full extension and discontinued walking aids postoperatively. Careful attention to graft preparation, tensioning, stable graft fixation, and postoperative rehabilitation led to encouraging results in this complex problem.

© 2021 The Authors. Published by Elsevier Inc. on behalf of The American Association of Hip and Knee Surgeons. This is an open access article under the CC BY-NC-ND license (<http://creativecommons.org/licenses/by-nc-nd/4.0/>).

## Introduction

Patellar tendon rupture is a devastating complication after total knee arthroplasty (TKA), with a prevalence of 0.17% [1,2]. While the etiology of this condition is multifactorial, this complication is often observed in patients who have multiple previous knee surgeries, numerous comorbidities, and systemic risk factors such as chronic steroid use [3]. Iatrogenic injury to the extensor mechanism itself or the vascular supply of the extensor mechanism during surgery such as in the context of a distal realignment procedure, excessive patella resection, or lateral release has also been implicated in patella tendon rupture. This often occurs in the context of patients with multiply operated knees or stiff knees with subsequent difficulty in everting the patella and gaining surgical exposure [3,4].

Besides the notable extensor lag and functional impairment seen in this condition, the abnormal knee kinetics observed can

increase the stresses on the knee prosthesis and contribute to implant loosening [2]. Nonoperative treatment, such as observation or immobilization in a cast, often relegates the patient to dependence on mobility aids and results in chronic knee instability [3].

Several techniques to address patellar tendon rupture, including primary repair, and various reconstructive techniques using autograft, allograft, or synthetic extensor meshes have been described. Multiple case series and systematic reviews [5,6] have shown that reconstruction has been the most reliable method to date with allograft repairs such as the commonly used Achilles tendon allograft being well established, which leads to consistently improved functional outcomes. However, patients are often hampered by residual extension lag and impaired range of motion, and the improvement of reconstruction techniques remains an area of interest.

We present a modification of the classic Achilles tendon allograft technique for treatment of patellar tendon rupture after TKA. The patient who will be discussed has provided informed consent for her clinical details, imaging data, and clinical photographs to be used. This consent was formally obtained and documented in our electronic medical records before the writing of this case report. To the best of our knowledge, the technique presented has not been described before.

No author associated with this paper has disclosed any potential or pertinent conflicts which may be perceived to have impending conflict with this work. For full disclosure statements refer to <https://doi.org/10.1016/j.artd.2021.10.003>.

\* Corresponding author. 1E Kent Ridge Road, Singapore 119228, Singapore. Tel.: +65 97565039.

E-mail address: [glenys.poon@mohh.com.sg](mailto:glenys.poon@mohh.com.sg)

<https://doi.org/10.1016/j.artd.2021.10.003>

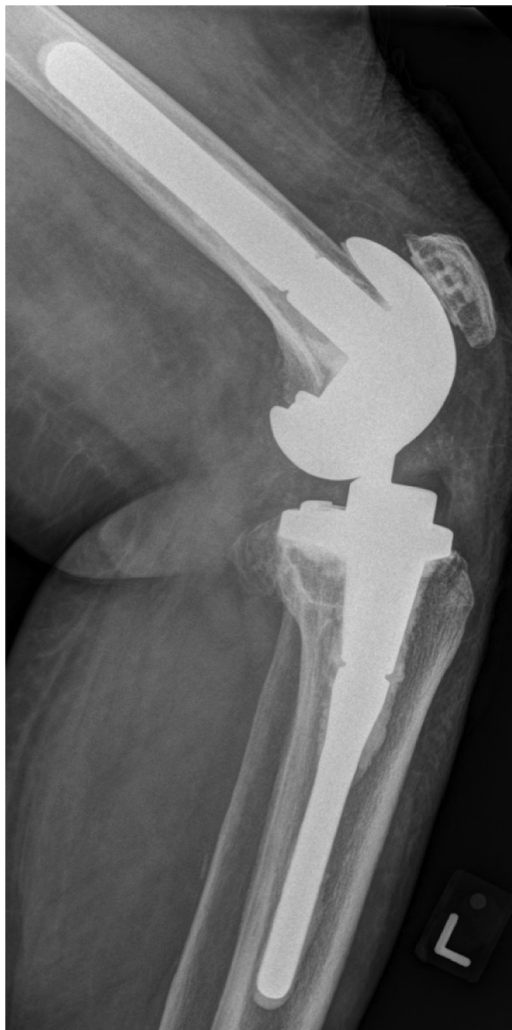2352-3441/© 2021 The Authors. Published by Elsevier Inc. on behalf of The American Association of Hip and Knee Surgeons. This is an open access article under the CC BY-NC-ND license (<http://creativecommons.org/licenses/by-nc-nd/4.0/>).

## Surgical technique

A 74-year-old Chinese female presented to our clinic with sudden-onset left knee pain and loss of extensor function. This was preceded by a loud “pop” sound heard when she was moving from a seated to standing position. She had a past medical history of Cushing syndrome from chronic steroid use, and a left TKA with patellar resurfacing was performed for her left knee osteoarthritis with severe varus deformity a month ago. During her primary surgery, severe attenuation of her medial collateral ligament with significant instability was noted, leading to the decision to proceed with a condylar constrained knee. Her body mass index was 37 kg/m<sup>2</sup>.

Physical examination indicated that her left patella had migrated proximally, and a palpable gap below the patella was noted. There was no active knee extension. The knee remained stable on stress testing. Plain radiography of the left knee showed a high riding patella with no associated fractures (Fig. 1). Ultrasonography confirmed the presence of patella tendon rupture with significant tendon retraction.

Surgical reconstruction of her patella tendon rupture was decided upon. The previous incision was used, and wide exposure of the entire quadriceps tendon, patella, patellar tendon, and the



**Figure 1.** Plain radiography film of patient's left knee taken in the lateral view. Patella is seen to have migrated superiorly.

tibial tubercle achieved. All quadriceps and residual patellar tendon tissue were preserved.

Intraoperatively, the patellar tendon was exposed, and rupture was ascertained to have occurred in the mid substance of the tendon. Remnants of the patellar tendon were thin and fragile (Fig. 2). A primary suture repair of the patellar tendon was first performed to position the patella before reconstruction with the allograft began.

The proximal portion of the tibia was exposed with subperiosteal elevation over the tibia tubercle. Osteotomy was performed on the proximal tibia to create a trapezoidal cavity about 2-cm long by 1.5-cm wide by 1-cm deep, slightly distal and medial to the original insertion of the patellar tendon to preserve the patellar tendon remnant and ensure central patellar tracking (Fig. 3b).

To prepare the allograft, a calcaneal bone block was fashioned to match the shape of the trapezoid cavity, and the tendinous end of the allograft was split into two bundles of approximately 2/3 – 1/3 (Fig. 3c).

The calcaneal bone block was press-fitted into the tibial trapezoidal cavity. Three 20-gauge (1 mm in diameter) cerclage wires were placed at the base of this trough and twisted over the press-fit bone block (Fig. 3a). A transverse tunnel was then made in the quadriceps tendon just proximal to the superior pole of the patella, and the 1/3 portion of the allograft was passed through the tunnel (Fig. 4). The remaining 2/3 portion of the Achilles tendon graft was then laid over anterior to the patella and fixed to the patella through drill holes made on the patella using nonabsorbable Ethibond 5 suture (Fig. 5). The tendon graft continued proximally and was sutured to the quadriceps tendon with Ethibond 5 using the Krackow suture technique. After fixation of the 2/3 portion, the 1/3 portion of the allograft which was passed through the transverse tunnel was then sutured back onto the lower portion of the allograft to form a loop around the patella with Ethibond 5 sutures (Fig. 6). The surgery was performed with the knee kept in strict full extension throughout.

The knee was immobilized in full extension using a functional knee brace postoperatively for 6 weeks with quadriceps isometric exercise having begun immediately under the supervision of a physiotherapist, and the patient was non-weight-bearing on the left knee with a walker. At 6 weeks, active assisted flexion to 40 degrees has begun, with a gradual increase by 10 degrees every week.

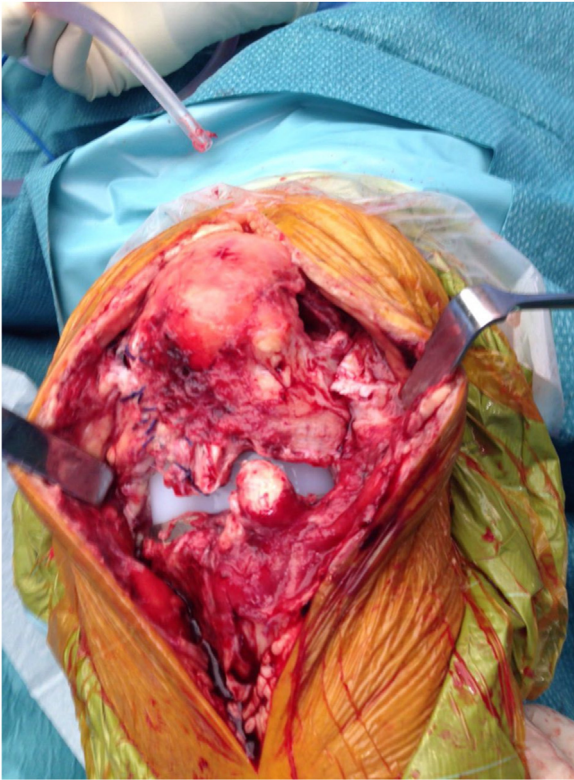At 3 months after the surgery, the patient was able to ambulate independently without the use of braces or walking aids. Full flexion of 90 degrees and extension lag of <10 degrees were achieved (Fig. 7a). At the final follow-up visit at 2 years, extension lag was 0 degrees (Fig. 7b).

At 2-year follow-up visit, plain radiographs showed incorporation of the calcaneal bone block with no resorption (Fig. 8c). A good implant position with no prosthetic loosening and periprosthetic fracture was noted (Fig. 8a and b). There were no patellar tendon re-rupture or postoperative infections. The patient had good quadriceps muscle strength and was able to climb stairs without aids. She was satisfied with her functional outcome.

## Discussion

### *Surgical options in extensor mechanism reconstruction*

Multiple surgical techniques for patellar tendon rupture in TKA have been described; however, few have been able to reliably restore a functional extensor mechanism. Isolated suture fixation is insufficient in patellar tendon rupture in the setting of TKA [1]. The patella retracts by 2 weeks, and the status of the ruptured patellar tendon tissue in the setting of TKA is deficient. Augmented repair



**Figure 2.** Intraoperative photograph of patient's left knee demonstrating a complete rupture of the patella tendon.

using graft is recommended to provide a structurally sound tissue to the deficient tendon tissue to strengthen the construct and allow earlier motion [2,7]. This host tissue is needed both to cover and help anchor the graft. The remaining host tissue should also mechanically support the graft tissue via load sharing.

The use of autografts—such as hamstring tendon and quadriceps tendon-patellar bone graft—has been described to augment the primary repair [8–10]. Spoliti et al. reported an excellent result in nine patients using autologous ipsilateral hamstring tendon grafts [11]. However, the retrospective study only included primary TKAs and excluded patients with risk factors for tendon ruptures such as connective tissue diseases and diabetes. These autografts may not be available in patients who have undergone multiple previous knee procedures. Autograft tendons are also of unreliable length, thickness, strength, and integrity. Jaureguito et al. reported the use of medial gastrocnemius transposition flap for reconstruction [12]; however, this extensive reconstruction approach is very challenging technically and has inherent donor-site morbidity, and three out of seven patients in the series experienced significant extension lag of more than 30 degrees.

The treatment of extensor mechanism disruption has expanded with the widespread availability of allograft tissues. Two different allografts can be used in the reconstruction of extensor mechanism: an Achilles tendon with a calcaneal bone block or an extensor mechanism composite graft consisting of quadriceps tendon-patella-patellar tendon-tibial tubercle. Fresh-frozen allograft, rather than freeze-dried allograft, should be used as it is stronger.

Achilles tendon allograft is preferred as it is less bulky and affords the advantage of longer length for more secure graft anchoring, particularly useful in chronic extensor mechanism disruption whereby the tendon retraction is significant. Reconstruction with the extensor mechanism composite graft presents

several drawbacks. It needs to be side and possibly sex matched (for patellar dimensions). Host patellectomy is often performed to accommodate the patellar allograft and introduces complication associated with patellar graft malalignment [7,13]. Hence, the extensor mechanism composite graft is typically used in patients where the patella is absent or insufficient [14]. Risk of infection also presents a concern in allograft reconstructions with reviews showing up to a 3.8% risk of postoperative infections [15].

Despite potential drawbacks, allograft repair is currently the most consistent surgical technique. In a systematic review by Maffulli et al., outcomes from 254 patients undergoing allograft repair were reviewed and showed good clinical results with a careful operative technique [5].

In recent years, there has also been an increased usage of synthetic meshes over traditional allografts due to cheaper costs, easier availability, and decreased risks of host immune reactions or disease transmission [16]. Meta-analysis such as that by Deren et al. shows comparable outcomes between synthetic mesh repairs and allograft repairs in postoperative complications, need for revision reconstruction, and functional outcomes as measured by the knee society score [15].

#### *Operative factors that increase allograft success*

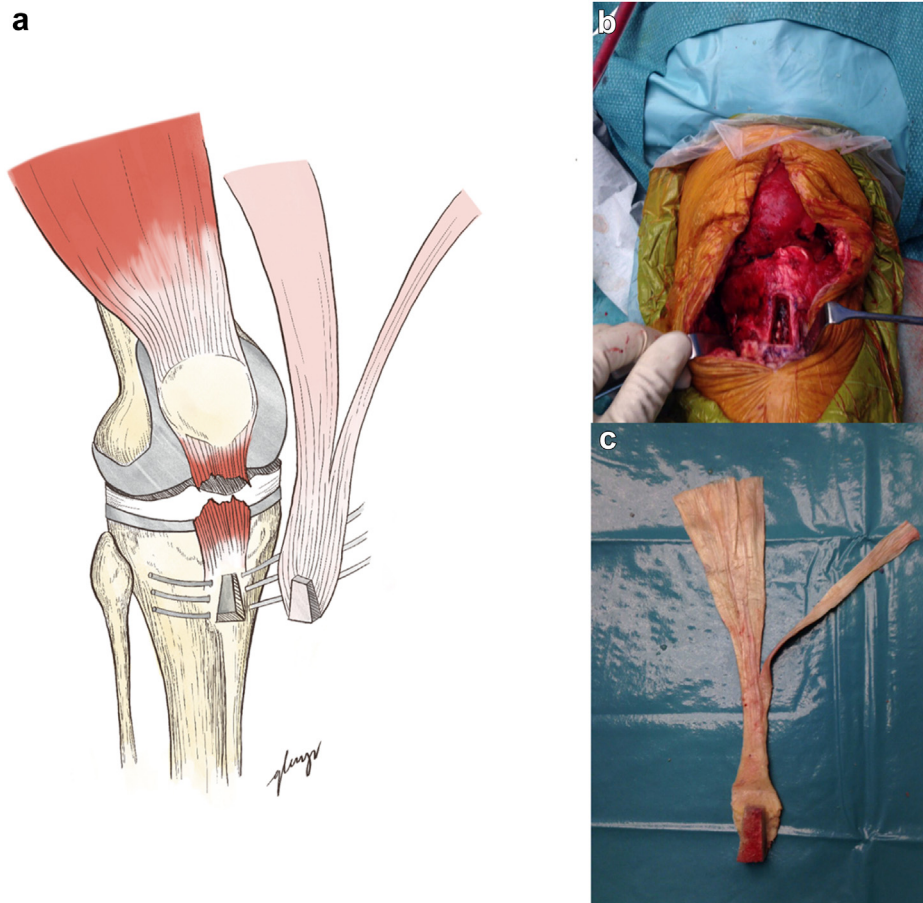
Various factors that increase the success of an allograft tendon reconstruction have been identified.

Rigid fixation of the host-allograft junction is important to improve surgical outcomes. The tendinous portion of the Achilles tendon allograft can be draped and sutured over the quadriceps tendon as described by Crossett et al. [17]. Ares et al. split the Achilles tendon allograft into two bundles, overcrossing these through the distal part of the quadriceps tendon [18]. The modified technique presented in this study offers the advantage of a more stable graft fixation by relying on both quadriceps tendon and transosseous patellar fixation. Patients with patellar tendon rupture in the setting of TKA have poor soft-tissue quality and underlying tendon degeneration. Hence, securing the allograft to the quadriceps tendon alone risks postoperative failure. The Achilles allograft technique presented in this case report has been shown to be safe and feasible and able to effectively restore the extensor mechanism in TKA.

The technique of allograft tensioning also acts as a crucial determinant of the result of the reconstruction of extensor mechanism in TKA. Loosely tensioned allografts cause persistent extension lag and clinical failure. Emerson et al. reported on the use of extensor mechanism composite graft for the treatment of ruptured patellar tendon associated with TKA [19]. Intraoperatively, the allograft was tensioned slightly to allow for 60 degrees of passive flexion [19]. However, long-term follow-up on the same cohort of patients revealed significant extension lag of more than 20 degrees in three of the nine knees and four graft complications [13]. Using the same technique as Emerson et al., Leopold et al. reported consistently poor clinical outcomes [20]. Nazarian and Booth and Burnett et al. modified the technique described by Emerson et al., recommending that the allograft be tightly tensioned in full extension [7,21]. With full intraoperative extension, there was a resultant increase in clinical success with no loss of flexion as compared to minimal tensioning [7,21]. The authors suggest that passive knee flexion should be avoided intraoperatively once the graft is tensioned and secured as it can loosen the already tensioned allograft.

After the surgery, all authors in Maffulli et al.'s review continued to maintain the knee in full extension with either a cast or bracing to prevent accidental flexion for a period of 3–12 weeks postoperatively leading to favorable outcomes [5].

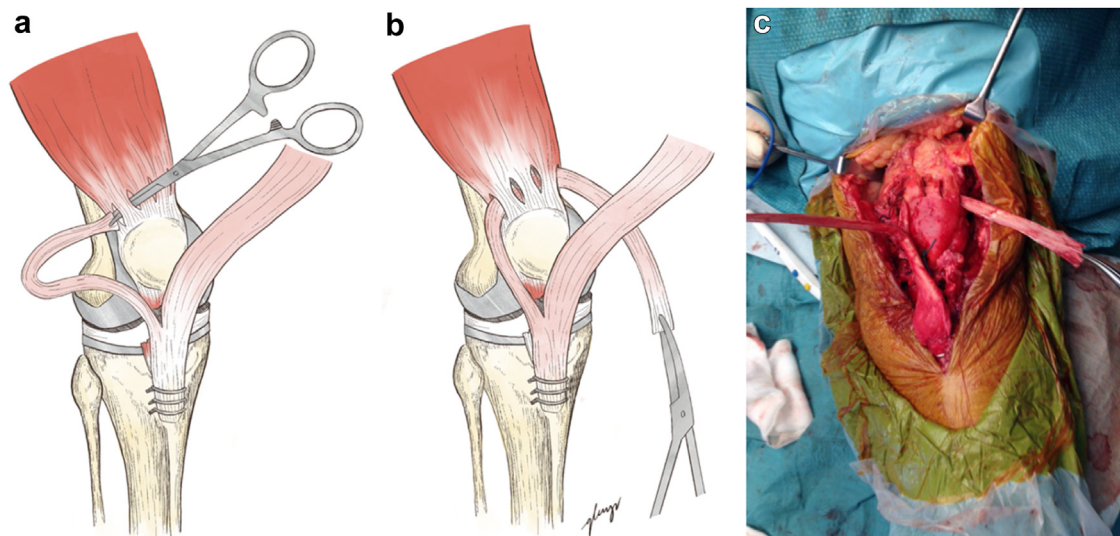




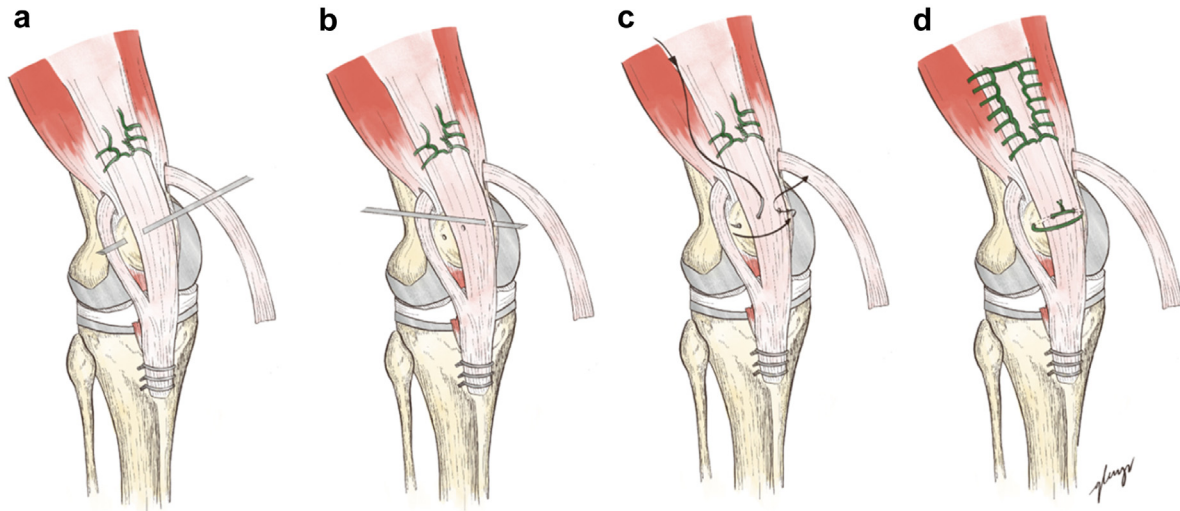
**Figure 3.** (a) Diagram demonstrating fixation of allograft to tibia by press-fitting bone block of the allograft into the tibia osteotomy site and fixing with three cerclage wires over the proximal tibia. (b) Clinical photograph showing tibia osteotomy site. (c) Clinical photograph showing preparation of the Achilles tendon allograft.

From prior case reports and our experience, we summarize the technical points crucial for success. First, no autogenous tissue should be removed in the process of reconstructing the extensor mechanism so that the allograft is embedded with host

tissue, maximizing the possibility of integration (Only the scar tissue from the previous operation may be debrided as needed.). Second, the host-allograft junctions should be secured tightly; rigid internal fixation should be used for the allograft-tibial



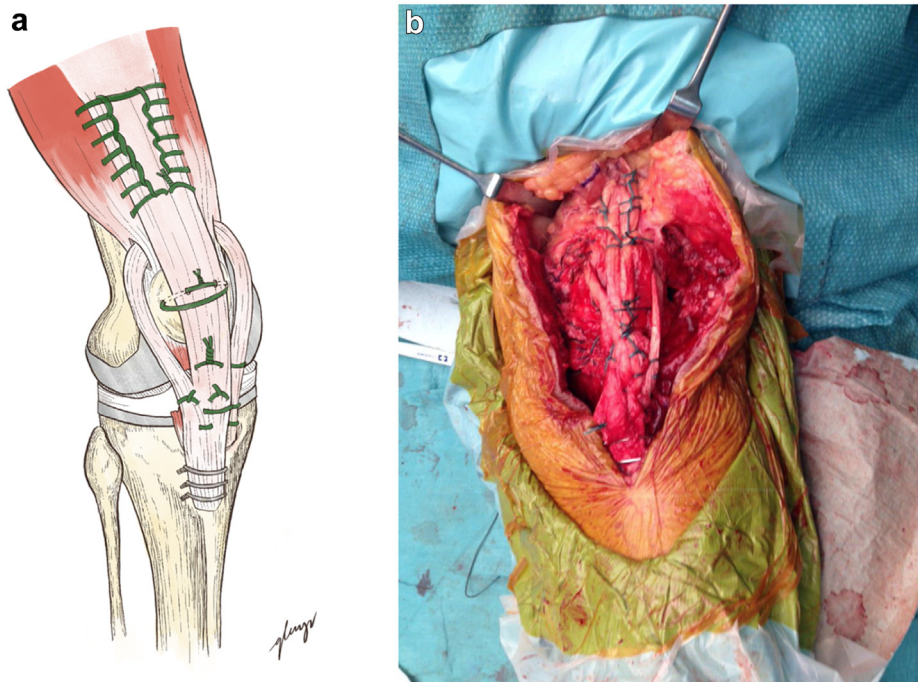
**Figure 4.** (a and b) Diagram illustrating creation of transverse tunnel over the quadriceps tendon and passing of the 1/3 portion of allograft through the transverse tunnel with assistance of artery forceps. (c) Clinical photograph of the knee after passage of the 1/3 portion of allograft through the transverse tunnel.



**Figure 5.** Fixation of the 2/3 portion of Achilles tendon allograft to the patient's quadriceps tendon via nonabsorbable sutures followed by further fixation of the allograft to the patella via drill holes created by 1.8 Kirschner wire. (a and b) Technique of drill hole formation. (c) Passage of nonabsorbable suture through drill holes to enable the allograft tendon to be tied down onto the patella surface. (d) Appearance of fastened 2/3 allograft.

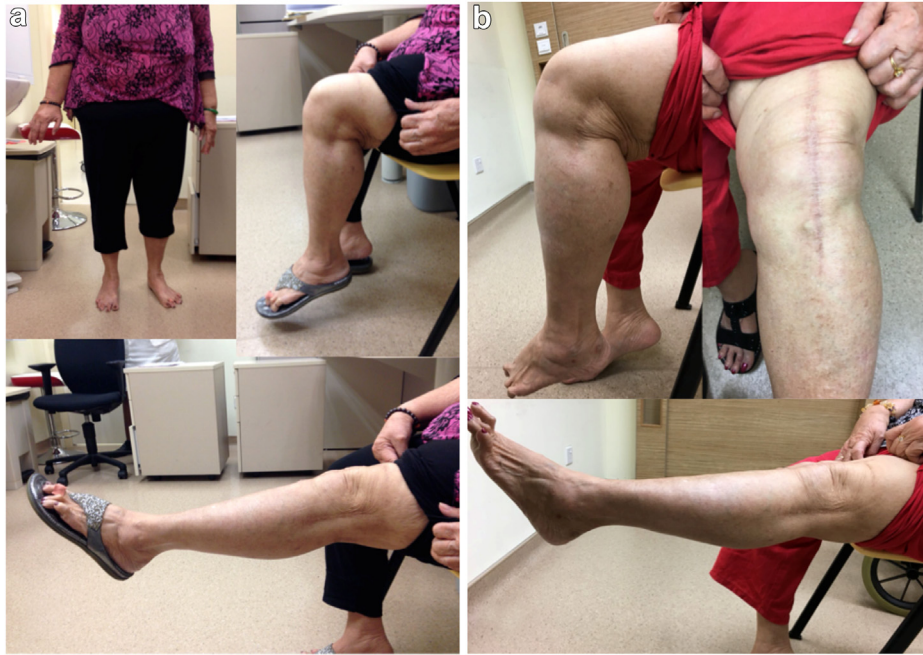tubercle, and interrupted nonabsorbable suture should be used for the tendon anastomosis. The patella should be maintained in the appropriate position on the femoral component to avoid patellofemoral mal-tracking. Third, the allograft should be tensioned at full knee extension without passively flexing the knee after securing the graft. Fourth, allograft should be handled gently to avoid graft damage during preparation. Fifth, component malalignment in TKA predisposes a patient to extensor mechanism dysfunction. Component removal and revision TKA should be performed as necessary. Sixth, healthy skin flaps

should be maintained over the graft with no tension on the closure, which can lead to skin necrosis and infection. The skin and subcutaneous tissue over the knee are usually thin, and most patients have multiple surgeries, which can further compromise the anterior skin. Finally, the knee is to be kept in full extension with usage of a cast or brace in the immediate postoperative period with early initiation of mobilization and isometric quadriceps exercises to prevent deconditioning. This is followed by progressive range of motion exercises after the initial immobilization period to prevent stiffening.

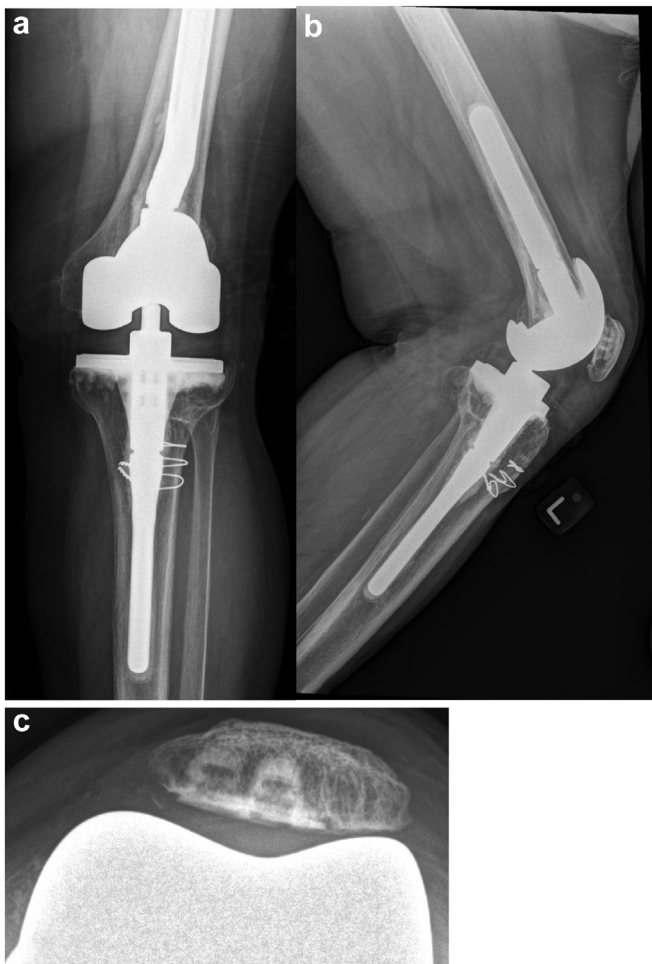

**Figure 6.** (a) Illustration showing final appearance of the reconstruction. The 1/3 portion of allograft which was passed through the transverse tunnel is sutured back onto the common portion of the allograft forming a looped reconstruction of the patella tendon. Further sutures were then placed to secure the construct (b) Correlating clinical photograph demonstrating final appearance of the patella tendon reconstruction.





**Figure 7.** Clinical photographs demonstrating patient knee extension and range of motion at 3 month follow up (a) and 2 years follow-up (b).



**Figure 8.** Plain postoperative radiographs of the knee. (a) Anterior-posterior view. (b) Lateral view. (c) Skyline view.

## Conclusion

Here we describe a new modified reconstructive technique that provided an excellent clinical and functional outcome for our patient. Careful attention to graft preparation and handling, tensioning of the allograft by maintaining full extension intraoperatively, stable graft fixation, and postoperative rehabilitation led to encouraging results in this complex problem.

## Conflicts of interest

The authors declare that there are no conflicts of interest.

## References

- [1] Lynch AF, Rorabeck CH, Bourne RB. Extensor mechanism complications following total knee arthroplasty. *J Arthroplasty* 1987;2(2):135.
- [2] Rand JA, Morrey BF, Bryan RS. Patellar tendon rupture after total knee arthroplasty. *Clin Orthop Relat Res* 1989;(244):233.
- [3] Bates MD, Springer BD. Extensor mechanism disruption after total knee arthroplasty. *J Am Acad Orthop Surg* 2015;23(2):95.
- [4] Schoderbek Jr RJ, Brown TE, et al. Extensor mechanism disruption after total knee arthroplasty. *Clin Orthop Relat Res* 2006;(446):176.
- [5] Maffulli N, Spiezia F, La Verde L. The management of extensor mechanism disruption after total knee arthroplasty: a systematic review. *Sports Med Arthrosc Rev* 2017;25(1):41.
- [6] Nam D, Abdel M, Cross M. Management of extensor mechanism complications in total knee arthroplasty: AAOS Exhibit selection. *J Bone Joint Surg Am* 2014;96(6):e47.
- [7] Nazarian DG, Booth Jr RE. Extensor mechanism allografts in total knee arthroplasty. *Clin Orthop Relat Res* 1999;(367):123.
- [8] Cadambi A, Engh GA. Use of a semitendinosus tendon autogenous graft for rupture of the patellar ligament after total knee arthroplasty. A report of seven cases. *J Bone Joint Surg Am* 1992;74(7):974.
- [9] Ecker ML, Lotke PA, Glazer RM. Late reconstruction of the patellar tendon. *J Bone Joint Surg Am* 1979;61(6A):884.
- [10] Rajgopal A, Vasdev A, Dahiya V. Patellar tendon reconstruction in total knee arthroplasty: a new technique. *J Knee Surg* 2015;28(6):483.
- [11] Spoliti M, Gai Via A, Padulo J, Oliva F, Del Buono A, Maffulli N. Surgical repair of chronic patellar tendon rupture in total knee replacement with ipsilateral hamstring tendons. *Knee Surg Sports. Traumatol Arthrosc* 2016;24(10):3183.
- [12] Jaureguito JW, Dubois CM, Smith SR, Gottlieb LJ, Finn HA. Medial gastrocnemius transposition flap for the treatment of disruption of the extensor mechanism after total knee arthroplasty. *J Bone Joint Surg Am* 1997;79(6):866.

- [13] Emerson Jr RH, Head WC, Malinin TI. Extensor mechanism reconstruction with an allograft after total knee arthroplasty. *Clin Orthop Relat Res* 1994;(303):79.
- [14] Barrack RL, Stanley T, Allen Butler R. Treating extensor mechanism disruption after total knee arthroplasty. *Clin Orthop Relat Res* 2003;(416):98.
- [15] Deren ME, Pannu TS, Villa JM, Firtha M, Riesgo AM, Higuera CA. Meta-analysis comparing allograft to synthetic reconstruction for extensor mechanism disruption after total knee arthroplasty. *J Knee Surg* 2021;34(3):338.
- [16] Shau D, Patton R, Patel S, Ward L, Guild G. Synth mesh vs. allograft extensor mechanism reconstruction total knee arthroplasty — A Syst Rev Lit meta-analysis. *Knee* 2018;25(1):2.
- [17] Crossett LS, Sinha RK, Sechriest VF, Rubash HE. Reconstruction of a ruptured patellar tendon with achilles tendon allograft following total knee arthroplasty. *J Bone Joint Surg Am* 2002;84-A(8):1354.
- [18] Ares O, Lozano LM, Medrano-Najera C, et al. New modified achilles tendon allograft for treatment of chronic patellar tendon ruptures following total knee arthroplasty. *Arch Orthop Trauma Surg* 2014;134(5):713.
- [19] Emerson Jr RH, Head WC, Malinin TI. Reconstruction of patellar tendon rupture after total knee arthroplasty with an extensor mechanism allograft. *Clin Orthop Relat Res* 1990;(260):154.
- [20] Leopold SS, Greidanus N, Paprosky WG, Berger RA, Rosenberg AG. High rate of failure of allograft reconstruction of the extensor mechanism after total knee arthroplasty. *J Bone Joint Surg Am* 1999;81(11):1574.
- [21] Burnett RS, Berger RA, Paprosky WG, Della Valle CJ, Jacobs JJ, Rosenberg AG. Extensor mechanism allograft reconstruction after total knee arthroplasty. A comparison of two techniques. *J Bone Joint Surg Am* 2004;86-A(12):2694.