

Case Report

Complicated bulbar urethral stricture successfully treated using augmented anastomotic urethroplasty: A case report

Tadashi Tabei,¹  Akio Horiguchi² and Kazuki Kobayashi¹

¹Department of Urology, Yokosuka Kyosai Hospital, Yokosuka, Kanagawa, and ²Department of Urology, National Defense Medical College, Tokorozawa, Saitama, Japan

Abbreviations & Acronyms

AUA = American Urological Association
EPA = excision and primary anastomosis

Correspondence: Tadashi Tabei M.D., Department of Urology, Yokosuka Kyosai Hospital, 1-16 Yonegahama-Dori, Yokosuka, Kanagawa 238-8558, Japan.
Email: tadashiokclub@yahoo.co.jp

How to cite this article: Tabei T, Horiguchi A, Kobayashi K. Complicated bulbar urethral stricture successfully treated using augmented anastomotic urethroplasty: A case report. *IJU Case Rep.* 2019; 2: 292–5.

This is an open access article under the terms of the Creative Commons Attribution-NonCommercial License, which permits use, distribution and reproduction in any medium, provided the original work is properly cited and is not used for commercial purposes.

Received 17 June 2019;
accepted 16 July 2019.
Online publication 28 July 2019

Introduction: Management of a complicated urethral stricture is a urological challenge. We present a case of a complicated urethral stricture successfully treated using augmented anastomotic urethroplasty.

Case presentation: A 48-year-old man visited our department for the treatment of urethral stricture, for which repeated transurethral procedures had failed. The operative view revealed that the urethral lumen was, in fact, completely obliterated over a 30-mm segment. We proceeded with augmented anastomotic urethroplasty. After the excision of the obliterated lesion, the ventral half of the bulbar urethral ends was anastomosed and their dorsal half was subsequently augmented via buccal mucosa spread and then fixed to the corpus cavernosa. There has been no indication of recurrence, 4 months after the procedure.

Conclusion: Augmented anastomotic urethroplasty is a useful technique for repairing a complicated bulbar stricture. Urologists should understand appropriate indications for each treatment method so as to not make cases more complicated to treat.

Key words: oral mucosa/transplantation, urethral stricture, urologic surgical procedure.

Keynote message

Urethroplasty is more effective than transurethral procedures for treating male urethral stricture. We report on our effective use of augmented anastomotic urethroplasty to treat a patient with a complicated bulbar urethral stricture, for which repeated transurethral procedures had failed. It is important for urologists to understand indications for urethroplasty and transurethral procedures to avoid unnecessary treatment complications.

Introduction

Anterior urethral stricture is a relatively common disease, causing lower urinary tract symptoms, including urinary retention. Urethroplasty is a gold standard to treat male bulbar urethral stricture.¹ However, transurethral dilation and direct visual internal urethrotomy are currently being used in the majority of cases because of their simplicity and ease of repetition. In 2017, the AUA published the guidelines for the management of male urethral stricture, recommending urethroplasty as the initial treatment of choice for the majority of cases, with a transurethral procedure recommended only for less severe strictures.¹

The bulbar urethra is the most common site of anterior urethral stricture.² When the length of the stricture is <20 mm, EPA is the most effective intervention, with a long-term success rate of approximately 90%.³ However, EPA cannot be performed for a >20-mm long stricture as a tension-free anastomosis becomes difficult to perform once the lesion is removed. Substitution urethroplasty using grafts or flaps is recommended for such cases. Several materials have been used for substitution urethroplasty including penile skin,⁴ bladder mucosa,⁵ intestinal mucosa,⁶ and oral mucosa.⁷ In recent practice, oral mucosa has become the most popular substitute as it is robust and easy to harvest.

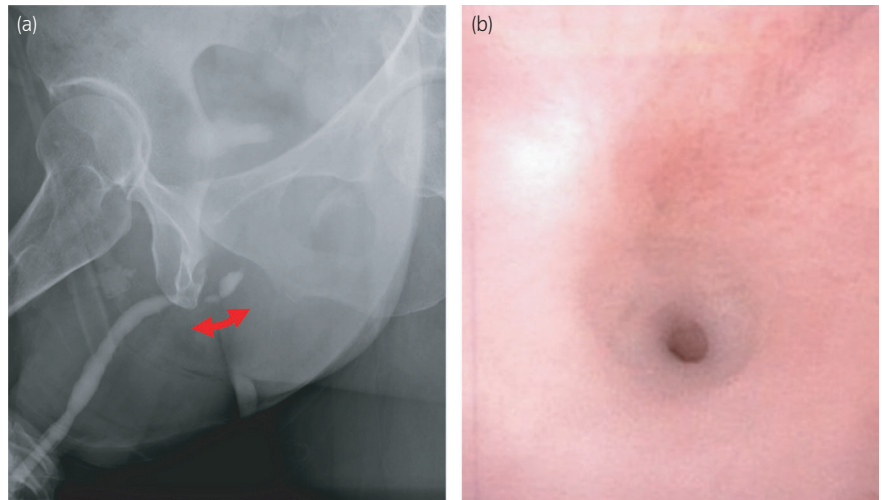


Fig. 1 (a) Pre-operative urethrography showing a 20-mm long stricture with a narrow segment in the bulbar urethra (red arrow). (b) Pre-operative urethroscopy indicating a pin-hole stricture in the bulbar urethra.

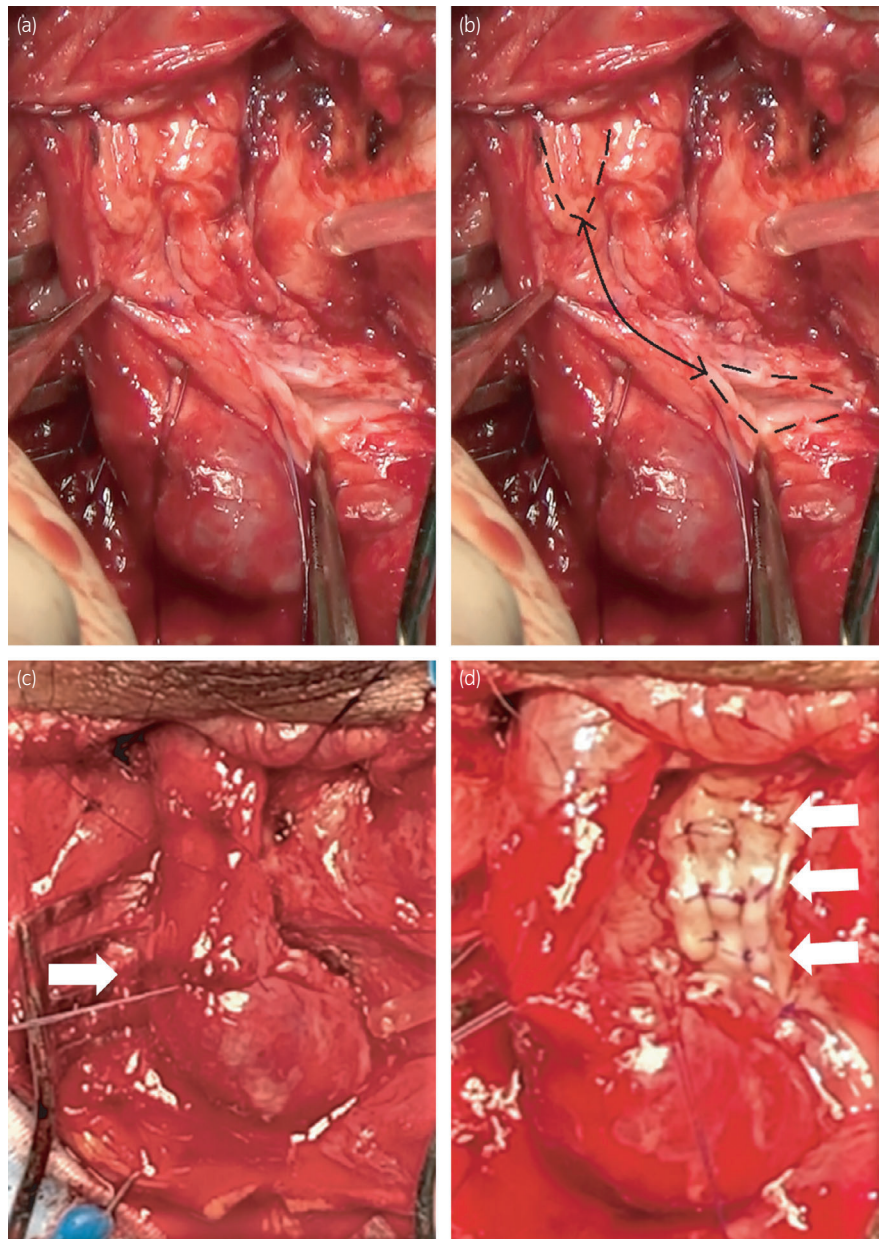


Fig. 2 (a) Intra-operative view confirming a complete, 30-mm obliteration. (b) Proximal and distal edges of the urethral mucosa are traced with the obliterated urethral segment (arrow). (c) A ventral anastomosis performed between the healthy mucosa of the proximal and distal urethra (arrow). (d) An oral mucosa graft harvested from the left inner cheek and spread and fixed to the corpora cavernosa (arrow).

Onlay augmentation is the most common type of substitution urethroplasty, including ventral,⁸ dorsal,⁹ and dorsolateral¹⁰ onlay. However, the procedure requires the graft to be sutured to the urethral plate and, thus, cannot be performed for patients with a completely obliterated bulbar urethra. In this case report, we describe the presentation, assessment, and treatment of a male patient with a bulbar urethral stricture, including a >20-mm segment of complete obliteration, using augmented anastomotic urethroplasty.

Case presentation

A 48-year-old man was referred to our department due to recurrent urethral stricture. His history revealed an initial episode of difficulty in urinating 3 years prior to the presentation. He was diagnosed with bulbar urethral stricture, at another hospital, and was treated by four failed attempts of balloon dilation over this time period. He had been performing self-catheterization since the last balloon dilation to prevent recurrence. He had experienced urethral trauma in his 30s from a bamboo pick in an accident, which was suggestive of a traumatic stricture etiology.

We proceeded with the placement of a suprapubic catheter to eliminate the need for intermittent self-catheterization, with the aim of urethral rest for 3 months. Following this urethral rest period, we proceeded with urethroscopy and retrograde urethrography, which revealed a complicated 20-mm long stricture in the bulbar urethra, which had a particularly narrow segment (Fig. 1a,b). Initially, we planned to use a dorsal onlay procedure to treat this stricture, as per previous recommendations.⁹ This surgery was performed via a midline perineal incision. The bulbar urethra was strongly adherent to the adjacent tissue due to prior procedures. After the mobilization of the bulbar urethra, the stricture site was opened along its dorsal surface, which revealed complete obliteration of the urethral lumen over a distance of >30 mm (Fig. 2a,b). We altered our surgical plan at that point, focusing on the excision of the obliterated segment and reconstruction with augmented anastomotic urethroplasty (Fig. 3). We completed a ventral anastomosis between the healthy mucosa of the proximal and distal urethra using 4-0 PDS interrupted sutures (Fig. 2c). An oral mucosa graft was harvested from the left inner cheek and spread and fixed to the corpora cavernosa (Fig. 2d), with the edge sutured to the opened urethral mucosa.

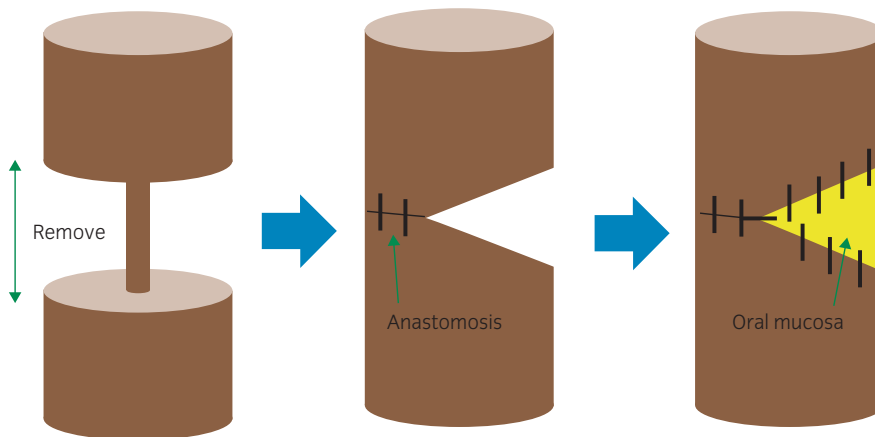


Fig. 3 A schematic representation of the augmented anastomotic urethroplasty.

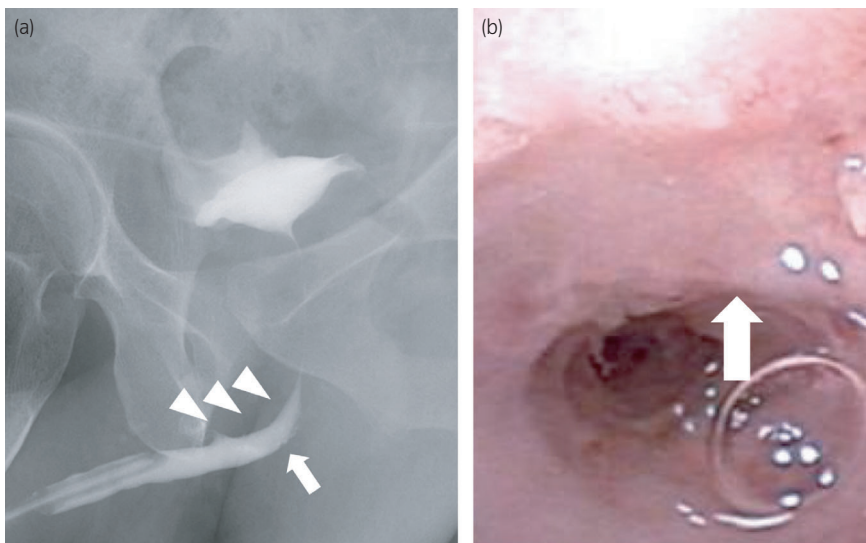


Fig. 4 (a) Retrograde urethrography, performed 3 weeks after surgery, confirming the patency of the urethral lumen, with the arrowhead indicating the site to which the oral mucosa was fixed. (b) Urethroscopy confirming smooth passage through the surgical site. The oral mucosa is shown in the upper half (arrow). Residual knots of absorbable mono-filament used during the procedure are visible.

The postoperative course was uneventful. Retrograde urethrography, performed 3 weeks after the surgery, revealed minor leakage, and the urethral catheter was removed (Fig. 4a). Urethroscopy performed 4 months after surgery confirmed easy passage through the augmented lesion, with no recurrence of stricture (Fig. 4b).

Discussion

Augmented anastomotic urethroplasty uses a combination of EPA and substitution urethroplasty. The obliterated urethra is completely removed, with an anastomosis performed ventrally or dorsally, with closure of the opposite urethral wall with an onlay graft (Fig. 2b). This technique was first introduced by Guralnick and Webster,¹¹ with a stricture-free rate of 93% reported over a mean follow-up period of 28 months.^{12,13}

A strategy using two-sided dorsal plus ventral grafting provides another option to treat bulbar urethral stricture that includes a particularly narrow segment. This technique was first introduced by Palminteri, with a stricture-free rate of 89.8%, reported at a median follow-up of 47 months.¹⁴ This technique is superior to the ventral or dorsal anastomotic technique in terms of preserving sexual function as it does not include transection. However, in terms of curing urethral stricture, augmented anastomotic urethroplasty might be better if a tension-free anastomosis is possible.

In the present case, the stricture was more severe than expected, and complete removal of the scarring tissue was required. We decided to change the procedure to augmented anastomotic urethroplasty from dorsal onlay urethroplasty because ventral anastomosis was possible without tension. Because the distal part of the corpus spongiosum was not thick enough as a graft bed, we attached the oral mucosa dorsally to the corpus cavernosum.

A possible reason that we underestimated the extent of stricture in our pre-operative assessment is that the rest period may have been insufficient. The AUA guidelines propose a rest period of 4–12 weeks to allow the stricture to mature.¹⁵ In the present case, we provided a 3-month urethral rest period, which might have still been too short. Repeated transurethral procedures likely make urethral strictures more complicated.¹⁶ In our country, in particular, the majority of urologists are not very familiar with urethroplasty; therefore, the transurethral procedure has been performed even for cases

in which it may be considered inappropriate. Urologists should understand indications for each treatment method so as to not make cases more complicated to treat, as shown in this presentation. We hope that this case report will encourage urethroplasty procedures to prevail even among urologists who are unfamiliar with reconstructive urology.

Conflict of interest

The authors declare no conflict of interest.

References

- Wessells H, Angermeier KW, Elliott S *et al.* Male urethral stricture: American Urological Association guideline. *J. Urol.* 2017; **197**: 182–90.
- Alwaal A, Blaschko SD, McAninch JW, Breyer BN. Epidemiology of urethral strictures. *Transl. Androl. Urol.* 2014; **3**: 209–13.
- Zimmerman WB, Santucci RA. A simplified and unified approach to anterior urethroplasty. *Nat. Rev. Urol.* 2010; **7**: 386–91.
- Mundy AR, Andrich DE. Urethral strictures. *BJU Int.* 2011; **107**: 6–26.
- Ozgök Y, Ozgür Tan M, Kilciler M, Tahmaz L, Erduran D. Use of bladder mucosal graft for urethral reconstruction. *Int. J. Urol.* 2000; **7**: 355–60.
- Palminteri E, Berdondini E, Fusco F, De Nunzio C, Salonia A. Long-term results of small intestinal submucosa graft in bulbar urethral reconstruction. *Urology* 2012; **79**: 695–701.
- el-Kasaby AW, Fath-Alla M, Noweir AM, el-Halaby MR, Zakaria W, el-Beialy MH. The use of buccal mucosa patch graft in the management of anterior urethral strictures. *J. Urol.* 1993; **149**: 276–8.
- Morey AF, McAninch JW. When and how to use buccal mucosal grafts in adult bulbar urethroplasty. *Urology* 1996; **48**: 194–8.
- Barbagli G, Selli C, Tosto A, Palminteri E. Dorsal free graft urethroplasty. *J. Urol.* 1996; **155**: 123–6.
- Kulkarni S, Barbagli G, Sansalone S, Lazzeri M. One-sided anterior urethroplasty: a new dorsal onlay graft technique. *BJU Int.* 2009; **104**: 1150–5.
- Guralnick ML, Webster GD. The augmented anastomotic urethroplasty: indications and outcome in 29 patients. *J. Urol.* 2001; **165**: 1496–501.
- Abouassaly R, Angermeier KW. Augmented anastomotic urethroplasty. *J. Urol.* 2007; **177**: 2211–5.
- El-Kassaby AW, El-Zayat TM, Azazy S, Osman T. One-stage repair of long bulbar urethral strictures using augmented Russell dorsal strip anastomosis: outcome of 234 cases. *Eur. Urol.* 2008; **53**: 420–4.
- Palminteri E, Lumen N, Berdondini E *et al.* Two-sided dorsal plus ventral oral graft bulbar urethroplasty: long-term results and predictive factors. *Urology* 2015; **85**: 942–7.
- Terlecki RP, Steele MC, Valadez C, Morey AF. Urethral rest: role and rationale in preparation for anterior urethroplasty. *Urology* 2011; **77**: 1477–81.
- Horiguchi A, Shinchi M, Masunaga A, Ito K, Asano T, Azuma R. Do transurethral treatments increase the complexity of urethral strictures? *J. Urol.* 2018; **199**: 508–14.