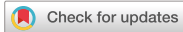

Case Report



OPEN ACCESS

Received: Mar 3, 2020

Revised: Apr 7, 2020

Accepted: Apr 13, 2020

Address for correspondence:

El Kim

Department of Neurosurgery, Dongsan Medical Center, Keimyung University School of Medicine, 1035 Dalgubeol-daero, Dalseo-gu, Daegu 42601, Korea.

E-mail: bach1158@dsmc.or.kr

Copyright © 2020 Korean Neurotraumatology Society

This is an Open Access article distributed under the terms of the Creative Commons Attribution Non-Commercial License (<https://creativecommons.org/licenses/by-nc/4.0/>) which permits unrestricted non-commercial use, distribution, and reproduction in any medium, provided the original work is properly cited.

ORCID iDs

El Kim

<https://orcid.org/0000-0002-7664-6030>

Conflict of Interest

The author has no financial conflicts of interest.

Clip Compression Injury of the Oculomotor Nerve: Its Prevention and Recovery

El Kim

Department of Neurosurgery, Dongsan Medical Center, Keimyung University School of Medicine, Daegu, Korea

ABSTRACT

Clip compression injury of oculomotor nerve (ON) is a preventable complication of aneurysm microsurgery. The author illustrates this condition in which ON was inadvertently occluded by the clip during repairing posterior communicating artery (PcoA) aneurysm. The report indicates that the surgeon should be meticulous in identifying and protecting ON at clipping stage when PcoA aneurysm prematurely bursts.

Keywords: Aneurysm; Microsurgery; Oculomotor nerve palsy

INTRODUCTION

Paralysis of oculomotor nerve (ON) is a well-known symptom in patients with sizable posterior communicating artery (PcoA) aneurysms. Neurosurgeons feel competent to deal with these aneurysms by performing the microsurgery or endovascular interventions.¹⁾ However, clipping for aneurysms might be associated with adverse intracranial and extracranial effects. Among them, brain swelling, premature rupture, incomplete ligation, perforator occlusion, infection, and cerebral contusion were thoroughly discussed in literatures.^{3,8,13,15)} However, a detailed description of clip compression injury to the ON was not found. The author reports one such case complicated during the surgical clipping of hemorrhagic PcoA aneurysm.

CASE REPORT

A 66 years old woman presented with severe headache and drowsiness secondary to subarachnoid hemorrhage (**FIGURE 1A**). Ocular examination was unremarkable. The medical history was negative for diabetes and hypertension. Computed tomography angiography showed an 8 mm-sized aneurysm directed posterolaterally in the left PcoA (**FIGURE 1B**).

Patient underwent a standard pterional trans-sylvian approach. Left internal carotid artery (ICA), and anterior choroidal artery, and PcoA was identified. The aneurysm had a wide and yellowish base. Manipulating the distal neck was complicated by aneurysm rupture. Simple

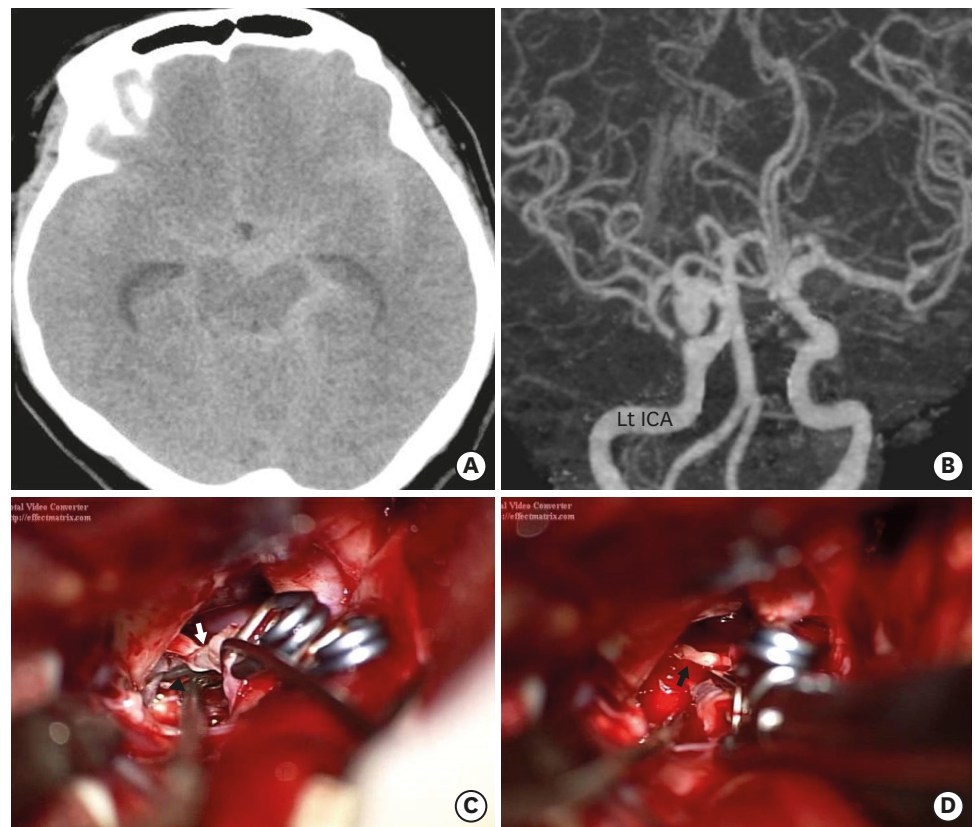


FIGURE 1. (A) CT reveals thick subarachnoid hemorrhage and hydrocephalus. (B) CT angiogram depicts an 8×6 mm size aneurysm in the left posterior communicating artery. (C) The ON (white arrow) is pinched between the tips of clip (black arrow head). (D) Photography demonstrates the ON has its anatomical continuity with focal thinning (black arrow).

CT: computed tomography, ON: oculomotor nerve, Lt ICA: left internal carotid artery.

tamponade did not stop the bleeding, so proximal ICA was trapped. When the temporary clip was advanced, the rupture site became larger. The nervous surgeon was forced to close the leaking point tentatively. Two suckers were introduced, and then an 11 mm Yasargil permanent clip (No. FT760T) was applied. However, the clipping failed to collapse the sac, so a long clip (No. FT780D) was reinforced. Further dissection revealed that the second clip had also occluded the ON (**FIGURE 1C**). The clip was readjusted upward to relieve the compression. Arachnoid was separated from the sac, PcoA, and ON. The neck was obliterated with 2 clips (FT740T and FT710T). The nerve seemed anatomically intact, but it was focally attenuated (**FIGURE 1D**).

Postoperatively, the patient had a ptosis, dilated pupil, and ophthalmoplegia in the left eye. Although steroid was started, the patient discharged with eyelid sagging (**FIGURE 2**). During the subsequent period of 1 year, ocular movement was restored; however she suffered glare and blurring for near objects.

DISCUSSION

In this patient, the surgeon encountered the intraoperative bleeding when he dissected the distal aspect of the aneurysm without precautionary measure. First of all, timely

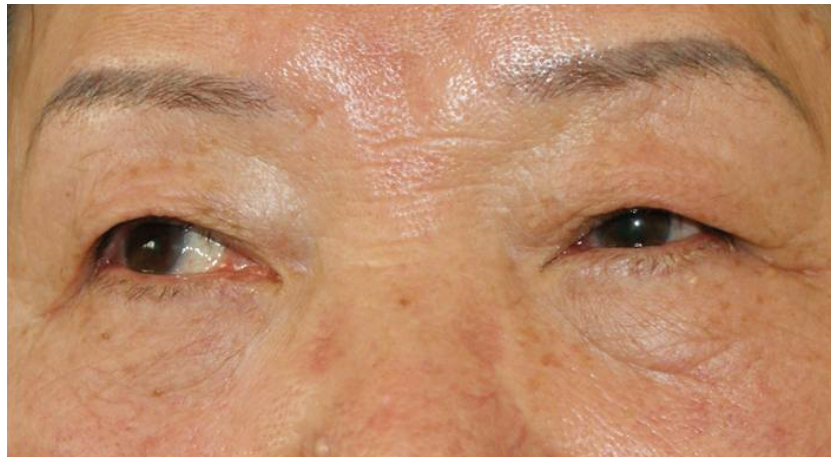

FIGURE 2. At 5 months later after surgery, the patient shows a partial ptosis and mydriasis in the left eye, associated with restricted adduction in the right gaze.

temporary occlusion is a prerequisite for patients of PcoA aneurysms because these lead to profuse hemorrhage due to high-pressured flow in the ICA.¹⁷⁾ When intracranial control of nutrient artery for the sac seems difficult, the ICA is explored in the neck before starting the craniotomy.¹⁵⁾ In this case, because the aneurysm had thick walls, clip application perpendicular to the long axis of ICA resulted in incomplete closure of blades and hemodynamic turbulence within the sac.⁵⁾ Therefore, the operator must employ the proximal and distal ICA traps to facilitate dissection of the aneurysm with arteriosclerotic plaque at the neck portion.⁹⁾ Nevertheless, if the bleeding persists, the temporary clip should be placed simultaneously on the PCoA itself when it large than normal. Lastly, no retracting the temporal lobe is also the principle to prevent premature rupture of PcoA aneurysm if the fundus is pointed laterally.

In many circumstances, the PcoA aneurysms grow laterally against the ON. Herein, the author describes the strategy to lessen the risk of ON palsy attributable to the clipping for these aneurysms. Firstly, the aneurysm should be obliterated with the clip just long enough to span its neck.^{1,13)} An excessively long clip may cause inadvertent injury to the associated vascular and neural structures. Secondly, when aneurysm is attached to the nerve, it is better to leave the dome in place without attempt for additional ON decompression.²¹⁾ Additionally, to avoid contact with ON, the clip tips are to be cushioned against the nerve using a surgical sponge.²⁾ Thirdly, once the neck is closed, the sac is rotated in all directions to inspect that the ON and perforators are excluded from the clips.²³⁾ Fourthly, if ON is obscured from direct view by the aneurysm, the nerve is free by mobilizing the sac after temporary occluding the ICA.¹⁰⁾ Finally, most importantly, the clinician has not to insert the clip blindly without exposing the entire sac, even when the aneurysm got ruptured prematurely as shown in the current case. If the aneurysm is not attached to surrounding structures, a preliminary clipping can be performed across the sac to close the rupture point, while the surgeon prepares the remaining neck.²²⁾

As observed in this patient, recovery of ON function after direct injury has a consistent course. They experience more rapid resolution of ptosis than of ocular movements, while accommodation reflex shows the least degree of restoration.⁶⁾ We managed the patient with a 6-week course of prednisolone, although this optional treatment was rarely reported in the literature.⁷⁾ There was focal softening in ON at the site of compression in the present

illustration. Regarding transient edema and inflammation, the steroid therapy is beneficial for neural degenerative and regenerative reaction within the traumatized part of axon after compressed by the clip blades.^{4,11,20)} In a study on ON paresis with head injured patients, the recovery rates of ptosis, diplopia, and pupil reflex were 90%, 60%, and 40%, respectively.¹⁴⁾ After traumatic ON palsy, follow-up of 12–18 months is usually allowed for spontaneous improvement before the surgical correction for strabismus is planned.^{7,12)} While waiting for natural recovery, temporary treatments, including occlusion of an eye with pads, wearing prism lenses, or injection of botulinum toxin into the ipsilateral lateral rectus muscle, can be performed for the selected cases to overcome ocular misalignment and disabling diplopia.²⁴⁾ Patients showed marked relief of symptoms when the toxin injection was done within 3 months of traumatic ON palsy.¹⁶⁾ For the most patients, the pupils of traumatic ON palsy have the denervation supersensitivity and constrict in response to 0.1% pilocarpine eye drop. This topical therapy counters glare and helps in the establishing of fusion in downward gaze by mediating accommodation.^{18,19)}

CONCLUSION

Intraoperative ON injury is avoidable by the surgeon's right action with adequate visualization of the neck during applying the clip on facing the premature hemorrhage from PcoA aneurysm.

REFERENCES

1. Albuquerque FC. Coiling versus clipping for posterior communicating artery aneurysms associated with oculomotor nerve palsy: only time will tell. *World Neurosurg* 74:250-251, 2010
[PUBMED](#) | [CROSSREF](#)
2. Al-Khayat H, Al-Khayat H, White J, Manner D, Samson D. Upper basilar artery aneurysms: oculomotor outcomes in 163 cases. *J Neurosurg* 102:482-488, 2005
[PUBMED](#) | [CROSSREF](#)
3. Almer ZE, Miller NR. Delayed third cranial nerve palsy after aneurysm wrapping. *J Neuroophthalmol* 28:359, 2008
[PUBMED](#) | [CROSSREF](#)
4. Carlson GD, Minato Y, Okada A, Gorden CD, Warden KE, Barbeau JM, et al. Early time-dependent decompression for spinal cord injury: vascular mechanisms of recovery. *J Neurotrauma* 14:951-962, 1997
[PUBMED](#) | [CROSSREF](#)
5. Chen SF, Kato Y, Kumar A, Tan GW, Oguri D, Oda J, et al. Intraoperative rupture in the surgical treatment of patients with intracranial aneurysms. *J Clin Neurosci* 34:63-69, 2016
[PUBMED](#) | [CROSSREF](#)
6. Dhaliwal A, West AL, Trobe JD, Musch DC. Third, fourth, and sixth cranial nerve palsies following closed head injury. *J Neuroophthalmol* 26:4-10, 2006
[PUBMED](#) | [CROSSREF](#)
7. Flanders M, Hasan J, Al-Mujaini A. Partial third cranial nerve palsy: clinical characteristics and surgical management. *Can J Ophthalmol* 47:321-325, 2012
[PUBMED](#) | [CROSSREF](#)
8. Fukuda H, Hayashi K, Yoshino K, Koyama T, Lo B, Kurosaki Y, et al. Impact of aneurysm projection on intraoperative complications during surgical clipping of ruptured posterior communicating artery aneurysms. *Neurosurgery* 78:381-390, 2016
[PUBMED](#) | [CROSSREF](#)
9. Goertz L, Hamisch C, Telentschak S, Kabbasch C, von Spreckelsen N, Stavrinou P, et al. Impact of aneurysm shape on intraoperative rupture during clipping of ruptured intracranial aneurysms. *World Neurosurg* 118:e806-e812, 2018
[PUBMED](#) | [CROSSREF](#)

10. Güresir E, Schuss P, Seifert V, Vatter H. Oculomotor nerve palsy by posterior communicating artery aneurysms: influence of surgical strategy on recovery. *J Neurosurg* 117:904-910, 2012
[PUBMED](#) | [CROSSREF](#)
11. Jang SY. Traumatic optic neuropathy. *Korean J Neurotrauma* 14:1-5, 2018
[PUBMED](#) | [CROSSREF](#)
12. Kaïdo T, Tanaka Y, Kanemoto Y, Katsuragi Y, Okura H. Traumatic oculomotor nerve palsy. *J Clin Neurosci* 13:852-855, 2006
[PUBMED](#) | [CROSSREF](#)
13. Kashimura H, Ogasawara K, Kubo Y, Ogawa A. Complete neck clipping of internal carotid-posterior communicating artery aneurysms using bayonet-shaped aneurysm clips: technical note. *Neurol Med Chir (Tokyo)* 47:282-284, 2007
[PUBMED](#) | [CROSSREF](#)
14. Kuo LT, Huang AP, Yang CC, Tsai SY, Tu YK, Huang SJ. Clinical outcome of mild head injury with isolated oculomotor nerve palsy. *J Neurotrauma* 27:1959-1964, 2010
[PUBMED](#) | [CROSSREF](#)
15. Leipzig TJ, Morgan J, Horner TG, Payner T, Redelman K, Johnson CS. Analysis of intraoperative rupture in the surgical treatment of 1694 saccular aneurysms. *Neurosurgery* 56:455-468, 2005
[PUBMED](#) | [CROSSREF](#)
16. Levy RL, Geist CE, Miller NR. Isolated oculomotor palsy following minor head trauma. *Neurology* 65:169-170, 2005
[PUBMED](#) | [CROSSREF](#)
17. Madhugiri VS, Ambekar S, Pandey P, Guthikonda B, Bollam P, Brown B, et al. The pterional and suprabrow approaches for aneurysm surgery: a systematic review of intraoperative rupture rates in 9488 aneurysms. *World Neurosurg* 80:836-844, 2013
[PUBMED](#) | [CROSSREF](#)
18. Mariak Z, Mariak Z, Lewko J, Zimnoch L. Pathogenesis of primary internal ophthalmoplegia after head injury. *Eur J Ophthalmol* 5:56-58, 1995
[PUBMED](#) | [CROSSREF](#)
19. Memon MY, Paine KW. Direct injury of the oculomotor nerve in craniocerebral trauma. *J Neurosurg* 35:461-464, 1971
[PUBMED](#) | [CROSSREF](#)
20. Pallini R, Fernandez E, Lauretti L, Draicchio F, Pettorossi VE, Gangitano C, et al. Experimental repair of the oculomotor nerve: the anatomical paradigms of functional regeneration. *J Neurosurg* 77:768-777, 1992
[PUBMED](#) | [CROSSREF](#)
21. Panagiotopoulos V, Ladd SC, Gizewski E, Asgari S, Sandalcioglu EI, Forsting M, et al. Recovery of ophthalmoplegia after endovascular treatment of intracranial aneurysms. *AJNR Am J Neuroradiol* 32:276-282, 2011
[PUBMED](#) | [CROSSREF](#)
22. Patel K, Guilfoyle MR, Bulters DO, Kirolos RW, Antoun NM, Higgins JN, et al. Recovery of oculomotor nerve palsy secondary to posterior communicating artery aneurysms. *Br J Neurosurg* 28:483-487, 2014
[PUBMED](#) | [CROSSREF](#)
23. Schuette AJ, Barrow DL, Cohen-Gadol AA. Strategies to minimize complications during intraoperative aneurysmal hemorrhage: a personal experience. *World Neurosurg* 83:620-626, 2015
[PUBMED](#) | [CROSSREF](#)
24. Talebnejad MR, Sharifi M, Nowroozadeh MH. The role of botulinum toxin in management of acute traumatic third-nerve palsy. *J AAPOS* 12:510-513, 2008
[PUBMED](#) | [CROSSREF](#)