



EDITORIAL COMMENT

Podocytouria: why it may have added value in rare diseases

Maria Dolores Sanchez-Niño¹, Maria Vanessa Perez-Gomez¹,
Lara Valiño-Rivas¹, Roser Torra² and Alberto Ortiz¹

¹IIS-Fundacion Jimenez Diaz, School of Medicine, Universidad Autonoma de Madrid; Fundacion Renal Iñigo Alvarez de Toledo-IRSIN and REDINREN, Madrid, Spain and ²Inherited Renal Disorders, Nephrology Department, Fundació Puigvert, REDINREN, IIB Sant Pau, Universitat Autònoma de Barcelona, Barcelona, Spain

Correspondence and offprint requests to: Alberto Ortiz; E-mail: aortiz@fdj.es

ABSTRACT

Fabry disease is an inherited lysosomal disease in which defects in the *GLA* gene lead to α -galactosidase-A deficiency, and accumulation of glycosphingolipids, including lyso-Gb3, a podocyte stressor. Therapy is available as enzyme replacement therapy and, for some patients, the chaperone migalastat. A key decision is when to start therapy, given its costs and potential impact on some aspects of quality of life. The decision is especially difficult in otherwise asymptomatic patients. A delayed start of therapy may allow kidney injury to progress subclinically up to the development of irreversible lesions. Non-invasive tools to monitor subclinical kidney injury are needed. One such tool may be assessment of podocytouria. In this issue of CKJ, [Trimarchi H, Canzonieri R, Costales-Collaguazo C et al. Early decrease in the podocalyxin to synaptopodin ratio in urinary Fabry podocytes. Clin Kidney J 2019; doi.org/10.1093/ckj/sfy053] report on podocytouria assessment in Fabry nephropathy. Specifically, they report that podocalyxin may be lost from detached urinary podocytes.

Keywords: Fabry, podocalyxin, podocyte, podocytouria, synaptopodin

Fabry disease is a hereditary metabolic disorder characterized by accumulation of glycosphingolipids that leads to chronic kidney disease (CKD), heart disease and stroke, among others [1]. Fabry nephropathy is one of the few nephropathies that has a specific therapy. Currently, both a chaperone, migalastat, and a recombinant enzyme, agalsidase, are approved for the treatment of Fabry disease, in which mutations in the *GLA* gene lead to absent or inactive lysosomal α -galactosidase-A.

Podocytouria is the urinary loss of podocytes. Since podocytes are terminally differentiated cells that do not divide and have limited replacement potential in adults, loss of podocytes in urine is thought to contribute to progressive podocyte depletion and CKD progression. More than a decade ago, the potential of podocytouria to detect early kidney injury, preceding

pathological albuminuria, or to identify active disease versus scar-related proteinuria, was already acknowledged [2]. However, the diverse techniques used to assess podocytouria (microscopy of stained cells, proteomics-based assays or mRNA quantification) have not yet been standardized to the point that they may enter/be used in clinical practice [3–8]. Antibodies against several podocyte proteins have been used to stain for them in urine and different authors have reported increased podocytouria in Fabry disease when assessed by podocalyxin staining [5–8]. Both podocalyxin and synaptopodin are used to identify podocytes in urine. However, few authors have stained for both proteins, and when they have, they did not report whether results differed depending on the marker used [9]. In this issue of CKJ, Trimarchi et al. report that in Fabry

Received: 30.7.2018; Editorial decision: 30.7.2018

© The Author(s) 2018. Published by Oxford University Press on behalf of ERA-EDTA. All rights reserved.

For permissions, please email: journals.permissions@oup.com.

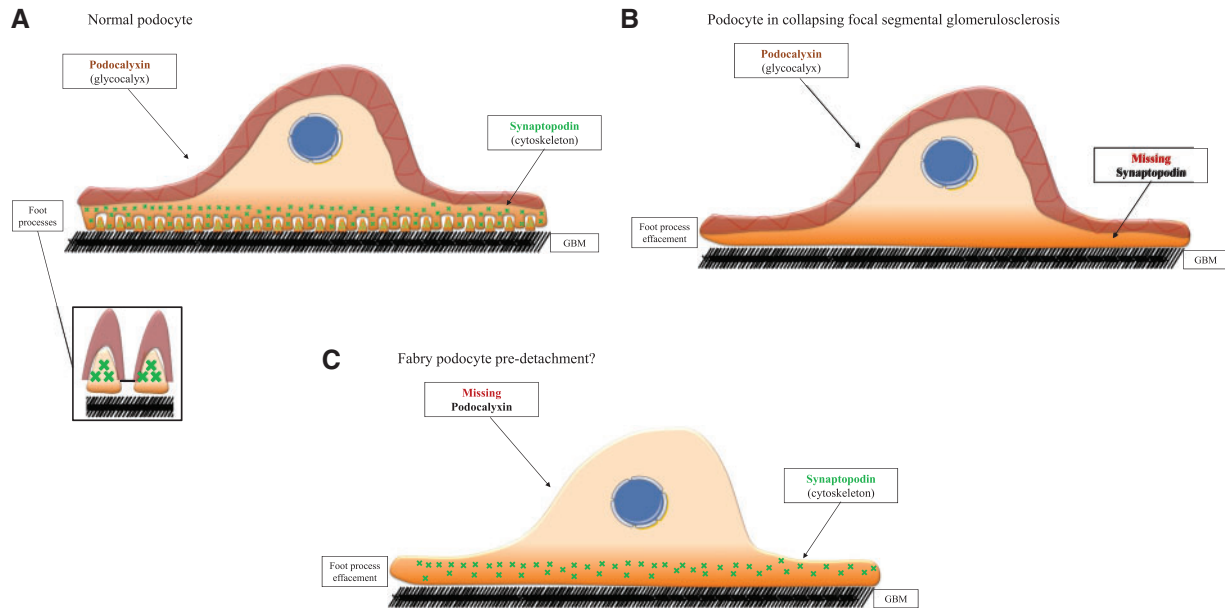


FIGURE 1: Graphic representation of podocalyxin and synaptopodin. (A) Normal healthy podocytes. Note foot processes and podocalyxin presence in the urinary surface, above the slit diaphragm that connects two adjacent foot processes. (B) Artistic rendition of the loss of synaptopodin with preservation of podocalyxin as described for collapsing focal segmental glomerulosclerosis [15]. (C) Potential appearance of a Fabry podocyte pre-detachment. Artistic rendition based on Trimarchi et al. findings in the urine of Fabry patients [10]. Note foot process effacement and loss of podocalyxin-containing glycocalyx.

nephropathy, podocalyxin may be lost from detached urinary podocytes before synaptopodin expression is lost [10]: all control urinary podocytes colocalized synaptopodin and podocalyxin, whereas in Fabry patients, most podocytes only stained for synaptopodin and no podocalyxin-positive/synaptopodin-negative cells were observed. One practical consequence would be that podocalyxin staining may underestimate podocyturia. In this regard, Trimarchi et al. hypothesize that a decrease in podocalyxin may be associated with less adhesiveness of cells to the extracellular matrix, favouring detachment and urinary excretion.

In Fabry disease, observations regarding the relationship of podocyturia with albuminuria or glomerular filtration rate (GFR) were not concordant [5–8]. Given the low number and heterogeneity of studied patients, this is not surprising. In this regard, several dynamic processes may influence the association of podocyturia with analytical evidence of kidney injury or progression. Thus, an increase in podocyturia appears to precede the increase in albuminuria, but progressive loss of podocytes and glomeruli reflected in decreasing GFR may, in turn, decrease podocyturia [11]. Alternatively, as suggested by Trimarchi et al., phenotypic changes may influence urinary podocyte quantification results when antibodies with different specificities are used [10]. Although it was a cross-sectional study, patients in whom urinary podocytes co-localized both proteins had higher podocyturia and lower proteinuria. One potential interpretation is that this represents an earlier stage of the disease, in which the podocyte phenotype has not yet been compromised, which is followed, when disease progresses, by selective podocalyxin depletion [10]. However, alternative explanations are possible. Podocalyxin-negative, synaptopodin-positive cells may represent cells other than podocytes. In this regard, according to the Protein Atlas, some anti-synaptopodin antibodies may faintly stain tubular cells (<https://www.proteinatlas.org/ENSG00000171992-SYNPO/tissue/kidney#img>; accessed 17 July 2018), or the test for synaptopodin staining

may be more sensitive than the test for podocalyxin staining. However, preservation over time of staining in stored urine should not be an issue, since all samples were collected on site.

What needs to be done now? The hypothesis that podocalyxin may be lost earlier than synaptopodin in injured Fabry podocytes should be tested in renal biopsies from Fabry patients.

What might be the mechanisms underlying the early podocalyxin loss? Injured podocytes may lose or decrease the expression of podocyte-specific proteins. Podocalyxin is the major sialoprotein of the glycocalyx of podocyte bodies and foot processes and locates mainly to urinary surfaces, above the level of slit diaphragms [12]. Synaptopodin is a cytoskeletal protein present in the foot processes of podocytes, and its expression is also markedly diminished in the kidneys under proteinuric conditions [13]. Podocalyxin expression commences at the early S-shaped body stage, and is required for the formation and maintenance of podocyte foot processes [14], whereas synaptopodin appears later, coinciding with the formation of foot processes and is restricted to the basal portion of the podocytes, where foot processes form [15] (Figure 1A). Decreased glomerular podocalyxin immunostaining has been reported in primary glomerulonephritides associated with nephrotic syndrome and in diabetic nephropathy, although synaptopodin was not explored [16, 17]. In more detailed studies, podocalyxin and synaptopodin expression was preserved in non-sclerotic glomeruli from minimal change disease and membranous nephropathy. By contrast, in idiopathic or HIV-associated collapsing focal segmental glomerulosclerosis, 16% of the histologically unaffected glomeruli showed marked reduction of synaptopodin expression but not of podocalyxin (Figure 1B) [15]. This is in contrast to the urinary findings of Trimarchi et al. in Fabry disease (Figure 1C). As an extracellular protein, podocalyxin may be targeted by extracellular enzymes. This may change the antigenicity or disrupt the protein and/or function. Indeed, podocyte injury may result in desialylation of podocalyxin [18]. Different antibodies may recognize different podocalyxin forms [19].

What might be the drivers of podocalyxin loss? The urine podocalyxin/synaptopodin ratio was decreased in diabetic nephropathy as compared with other glomerulonephritides [20]. This may mimic the urinary findings of Trimarchi *et al.* in Fabry disease. Indeed, both nephropathies may be considered metabolic proteinuric forms of progressive CKD. A high glucose concentration suppressed podocalyxin expression in cultured podocytes, but synaptopodin was not studied [21]. Lyso-Gb3 is a metabolite accumulated in Fabry disease that induces a podocyte stress response similar to that induced by high glucose concentrations [22, 23]. In addition, lyso-Gb3 increases CD80 expression in podocytes, a marker found both in Fabry kidney biopsies and in the urine of Fabry patients [8]. This supports studying the impact of lyso-Gb3 on podocalyxin expression.

Two characteristics of Fabry disease emphasize the potential importance of podocyuria assessment. First, the natural history is several decades long and the first clinical evidence of kidney injury, which is usually microalbuminuria, may take decades to develop. Secondly, by the time kidney injury becomes clinically evident, irreversible lesions may have developed. In this regard, the timing of therapy initiation is an important consideration, given the high cost of therapy and the burden of intravenous administration in the case of the agalsidase.

Reports that increased podocyuria may precede pathological albuminuria in Fabry disease open the door to a non-invasive assessment of early kidney injury that may eventually be used to initiate therapy when there is no other indication. Only further research will guide the choice of the podocyuria assay that may eventually make it into clinical practice. Although normalization of podocyuria by urinary creatinine is the current standard, and may be useful to compare the same patient over time, urinary creatinine depends mainly on muscle mass and may vary up to 4-fold between individuals, potentially resulting in similar (up to 4-fold) interindividual variations in creatinuria-normalized podocyuria in different patients with similar rates of podocyte loss. The lower muscle mass (and urinary creatinine) in females may lead to higher urinary podocyte:creatinine ratios. Reproducible methods for widespread implementation for podocyuria detection are still lacking, but if podocyuria ever reaches the clinical routine, different threshold levels should be defined for males and females.

FUNDING

The work was supported by ISCIII and FEDER funds PI16/02057, PI18/01366, Sociedad Española de Nefrología, ISCIII-RETIC REDinREN RD016/009, Miguel Servet to M.D.S.-N., Comunidad de Madrid CIFRA2 B2017/BMD-3686.

CONFLICT OF INTEREST STATEMENT

A.O. is a consultant for and has received research support by Genzyme a Sanofi company and has received speaker fees from Shire and Amicus. M.D.S.-N. has received speaker fees from Genzyme a Sanofi company. R.T. is a consultant for and has received speaker fees from Shire, Amicus and Genzyme a Sanofi company.

REFERENCES

- Ortiz A, Germain DP, Desnick RJ *et al.* Fabry disease revisited: management and treatment recommendations for adult patients. *Mol Genet Metab* 2018; 123: 416–442
- Petermann A, Floege J. Podocyte damage resulting in podocyuria: a potential diagnostic marker to assess glomerular disease activity. *Nephron Clin Pract* 2007; 106: c61–c66
- Garovic VD, Craici IM, Wagner SJ *et al.* Mass spectrometry as a novel method for detection of podocyuria in pre-eclampsia. *Nephrol Dial Transplant* 2013; 28: 1555–1561
- Wickman L, Afshinnia F, Wang SQ *et al.* Urine podocyte mRNAs, proteinuria, and progression in human glomerular diseases. *J Am Soc Nephrol* 2013; 24: 2081–2095
- Fall B, Scott CR, Mauer M *et al.* Urinary podocyte loss is increased in patients with Fabry disease and correlates with clinical severity of fabry nephropathy. *PLoS One* 2016; 11: e0168346
- Selvarajah M, Nicholls K, Hewitson TD *et al.* Targeted urine microscopy in Anderson-Fabry disease: a cheap, sensitive and specific diagnostic technique. *Nephrol Dial Transplant* 2011; 26: 3195–3202
- Pereira EM, Silva AS, Labilloy A *et al.* Podocyuria in fabry disease. *J Bras Nefrol* 2016; 38: 49–53
- Trimarchi H, Canzonieri R, Schiel A *et al.* Increased urinary CD80 excretion and podocyuria in Fabry disease. *J Transl Med* 2016; 14: 289
- Petrica L, Vlad M, Vlad A *et al.* Podocyuria parallels proximal tubule dysfunction in type 2 diabetes mellitus patients independently of albuminuria and renal function decline: a cross-sectional study. *J Diabetes Complications* 2017; 31: 1444–1450
- Trimarchi H, Canzonieri R, Costales-Collaguazo C *et al.* Early decrease in the podocalyxin to synaptopodin ratio in urinary Fabry podocytes. *Clin Kidney J* 2019; 12: 53–60
- Trimarchi H, Canzonieri R, Schiel A *et al.* Podocyuria is significantly elevated in untreated vs treated Fabry adult patients. *J Nephrol* 2016; 29: 791–797
- Kerjaschki D, Sharkey DJ, Farquhar MG. Identification and characterization of podocalyxin—the major sialoprotein of the renal glomerular epithelial cell. *J Cell Biol* 1984; 98: 1591–1596
- Srivastava T, Garola RE, Whiting JM *et al.* Synaptopodin expression in idiopathic nephrotic syndrome of childhood. *Kidney Int* 2001; 59: 118–125
- Doyonnas R, Kershaw DB, Duhme C *et al.* Anuria, omphalocele, and perinatal lethality in mice lacking the CD34-related protein podocalyxin. *J Exp Med* 2001; 194: 13–27
- Barisoni L, Kriz W, Mundel P *et al.* The dysregulated podocyte phenotype: a novel concept in the pathogenesis of collapsing idiopathic focal segmental glomerulosclerosis and HIV-associated nephropathy. *J Am Soc Nephrol* 1999; 10: 51–61
- Kavoura E, Gakiopoulou H, Paraskevovou H *et al.* Immunohistochemical evaluation of podocalyxin expression in glomerulopathies associated with nephrotic syndrome. *Hum Pathol* 2011; 42: 227–235
- Koop K, Eikmans M, Baelde HJ *et al.* Expression of podocyte-associated molecules in acquired human kidney diseases. *J Am Soc Nephrol* 2003; 14: 2063–2071
- Pawluczyk IZA, Najafabadi MG, Brown JR *et al.* Sialic acid supplementation ameliorates puromycin aminonucleoside nephrosis in rats. *Lab Invest* 2015; 95: 1019–1028
- Vitureira N, Andrés R, Pérez-Martínez E *et al.* Podocalyxin is a novel polysialylated neural adhesion protein with multiple roles in neural development and synapse formation. *PLoS One* 2010; 5: e12003

20. Kwon SK, Kim SJ, Kim H-Y. Urine synaptopodin excretion is an important marker of glomerular disease progression. *Korean J Intern Med* 2016; 31: 938–943
21. Economou CG, Kitsiou PV, Tzinia AK et al. Enhanced podocalyxin expression alters the structure of podocyte basal surface. *J Cell Sci* 2004; 117: 3281–3294
22. Sanchez-Niño MD, Carpio D, Sanz AB et al. Lyso-Gb3 activates Notch1 in human podocytes. *Hum Mol Genet* 2015; 24: 5720–5732
23. Sanchez-Niño MD, Sanz AB, Carrasco S et al. Globotriaosylsphingosine actions on human glomerular podocytes: implications for Fabry nephropathy. *Nephrol Dial Transplant* 2011; 26: 1797–1802