

Received: 2019.09.21

Accepted: 2020.01.14

Available online: 2020.01.28

Published: 2020.03.12

Postoperative Tetraplegia to a Child after Cerebellar Pilocytic Astrocytoma Excision at Prone Position: Case Report and Literature Review

Authors' Contribution:

Study Design A
Data Collection B
Statistical Analysis C
Data Interpretation D
Manuscript Preparation E
Literature Search F
Funds Collection G

ABCDEF 1 **Dimitrios Panagopoulos**
ABCD 1 **Elias Antoniadis**
BCDF 2 **Ploutarchos Karydakis**
BCDE 3 **Dimitrios Giakoumettis**
ACDEF 1 **Marios Themistocleous**

1 Department of Neurosurgery, Agia Sophia, Pediatric Hospital, Athens, Greece
2 Department of Neurosurgery, 251 Hellenic Air Force General Hospital, Athens, Greece
3 Department of Neurosurgery, University of Athens, Medical School, Evangelismos Hospital, Athens, Greece

Corresponding Author: Dimitrios Panagopoulos, e-mail: dimpanayop@gmail.com

Conflict of interest: None declared

Patient: Female, 5-year-old
Final Diagnosis: Post operative ischemia
Symptoms: Vomitting
Medication: —
Clinical Procedure: Suboccipital craniotomy
Specialty: Neurosurgery

Objective: Unusual clinical course

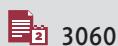Background: Various factors have been implicated in the pathogenesis of infarction after posterior fossa surgery such as venous air embolism, patient's position (seated or prone), hyperflexion of the neck, excessive spinal cord traction, cervical canal stenosis, and systemic arterial hypotension. The main aim of this case report was to elucidate a case in which hydrogen peroxide was implicated in a major and systemic complication after a neurosurgical procedure.

Case Report: We describe the case of a 5-year-old female patient who was admitted to our hospital because of a cerebellar hemispheric astrocytoma associated with obstructive hydrocephalus and accompanied by 2 syringomyelic cavities in the cervicothoracic portion of the spinal cord. Immediately after gross total resection of the lesion, impaired mobility of the upper and lower extremities was observed, a finding that was not consistent with intraoperative neurophysiologic monitoring data. Hydrogen peroxide had been judiciously used to irrigate the resection tumor cavity. In the next few postoperative days, the patient suffered from transient diabetes insipidus and hyperpyrexia, indicative of hypothalamic injury.

Conclusions: Neurological evaluation of the patient, after stabilization of her medical condition, revealed residual spasticity of upper and lower extremities, rendering her able to mobilize via the aid of wheelchair only. The most possible pathophysiologic explanation of her neurological deterioration, including hypothalamic dysfunction, was analyzed. The role of hydrogen peroxide as a source of free radical formation, and its co-responsibility for vascular platelet aggregation and vasoconstriction was considered, upon case review, the main responsible etiologic factor.

MeSH Keywords: Brain Stem Infarctions • Diabetes Insipidus, Neurogenic • Hydrogen Peroxide • Infratentorial Neoplasms

Full-text PDF: <https://www.amjcaserep.com/abstract/index/idArt/920213>



3060



6



23



Background

Several patient positions are currently used during operations of patients who have posterior fossa lesions. Each individual position has its own inherent risks and benefits, with no one position having been proven to be superior regarding safety and efficacy. The most devastating position-related complication reported is cervical cord infarction with subsequent quadriplegia [1].

A relatively underreported devastating complications after brain surgery is associated with the use of hydrogen peroxide (H_2O_2) [2]. It has been well described in the literature that H_2O_2 can cause vasoconstriction, gaseous emboli, and the trigemino-cardiac reflex. In addition, the impact of reactive oxygen species, mainly derived from H_2O_2 , on hypothalamic function and regulation of its homeostasis has been well described in the literature [3,4]. Additionally, hypothalamic circuitry is labile to alterations of blood perfusion.

Another important issue is the accuracy of neurophysiologic monitoring to evaluate nervous function while the patient is under general anesthesia. Although intraoperative monitoring constitutes an important neurophysiological tool to minimize sequelae during surgical procedures that put neurological tissue at risk, intraoperative monitoring is not always valid, especially in children as interpretation of criteria should be differentiated from that used in adults, and comparisons made with adult series may not be valid.

The aim of the current case report was to alert clinicians to the potential disastrous effects of the use of H_2O_2 , even when precautions are implemented. Complications can be localized complications such as an ischemic infarction in the nearby areas, or systemic complications such as those associated with the development of diabetes insipidus.

Case Report

A 5-year-old female patient from Greece was admitted to our department with a history of recent onset morning headaches, persistent dizziness, and vomiting within the last month. Her past medical and surgical history, drug history, and family history were unremarkable. Her Glasgow Coma Scale was 14 out of 15, and her balance was impaired with positive Romberg sign and a tendency to fall leftwards. Fundoscopic examination revealed bilateral papilledema. A magnetic resonance imaging (MRI) of the brain disclosed a posterior fossa space-occupying lesion of the left cerebellar hemisphere with a cystic component. This space-occupying lesion was the causative factor of an associated obstructive hydrocephalus. The relative spatial dimensions of the lesion were 4.9×5.1×3.8 cm (Figure 1). In addition,

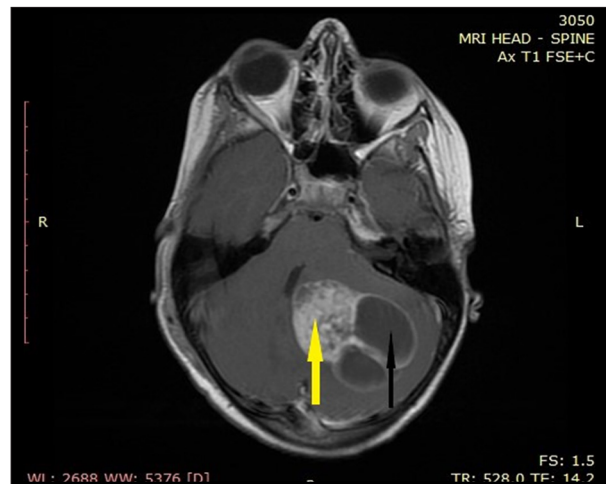


Figure 1. Magnetic resonance imaging (MRI) obtained prior to tumor removal, axial T1 weighted, fast spin echo (FSE) sequence following contrast administration, depicting the solid (yellow arrow) and cystic parts (black arrow) of the posterior fossa lesion.

MRI of the cervical cord revealed 2 syringomyelic cavities in the cervicothoracic portion of the spinal cord (Figures 2, 3). Due to rapid deterioration of the patient's level of consciousness, she underwent an endoscopic third ventriculostomy, followed by a total tumor resection with the patient in the prone position, via a midline suboccipital craniotomy, with her head resting on a horseshoe. After head stabilization with the aid of a Mayfield head holder, we examined the patient's neck position to avoid hyperflexion of the neck. All pressure points, including the eyes, were checked and padded to avoid compression. Additionally, a 2-fingerbreadth distance was established between the chin and the chest to avoid jugular vein compression and restriction of venous outflow. The procedure was executed by a consultant, who had adequate experience. Thus, all necessary precautions were undertaken during patient positioning and execution of the operation. While the prone and sitting positions offer good access to structures in the midline, we preferred the prone position in this case. Several advantages have been attributed to the sitting position: it improves surgical access to the posterior fossa by facilitating gravity assisted drainage of blood and cerebral spinal fluid (CSF) and by decreasing intracranial pressure (ICP). Additionally, it improves surgical orientation and access to the midline structures and decreases the amount of surgical retraction needed to gain access to deeper structures. Nonetheless, the sitting position has been associated with a number of potentially disastrous complications. Patients in the sitting position must be returned to the supine position rapidly for resuscitative measures in case of an acute cardiovascular collapse. Venous air embolism, cardiovascular instability, and pneumocephalus are also well-described complications associated with the sitting position. We concluded that the prone position was the safest option for our patient.

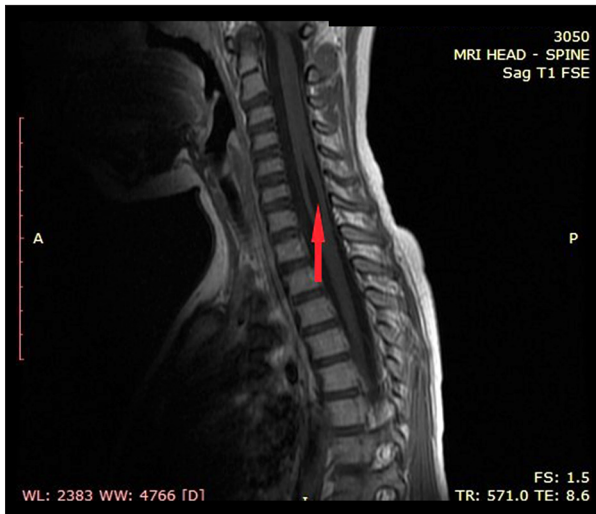

Figure 2. Preoperative sagittal magnetic resonance imaging (MRI), T1 weighted, fast spin echo (FSE) sequence, depicting the upper 1 of the 2 syringomyelic cysts located in the cervicothoracic region (arrow).

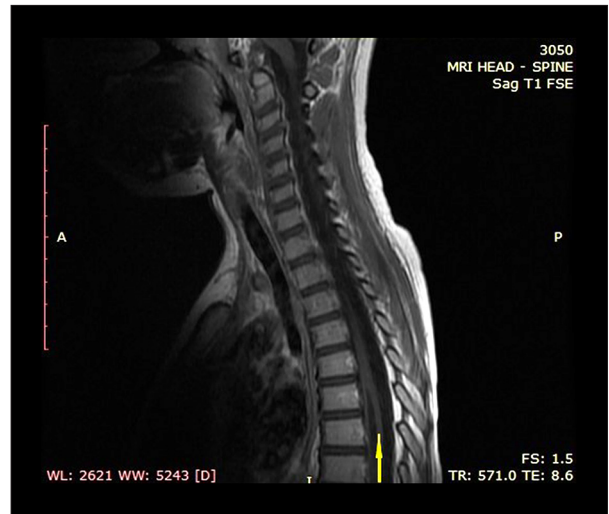

Figure 3. Preoperative sagittal magnetic resonance imaging (MRI), T1 weighted, fast spin echo (FSE) sequence, depicting the lower 1 of 2 syringomyelic cysts located in the cervicothoracic region (arrow).

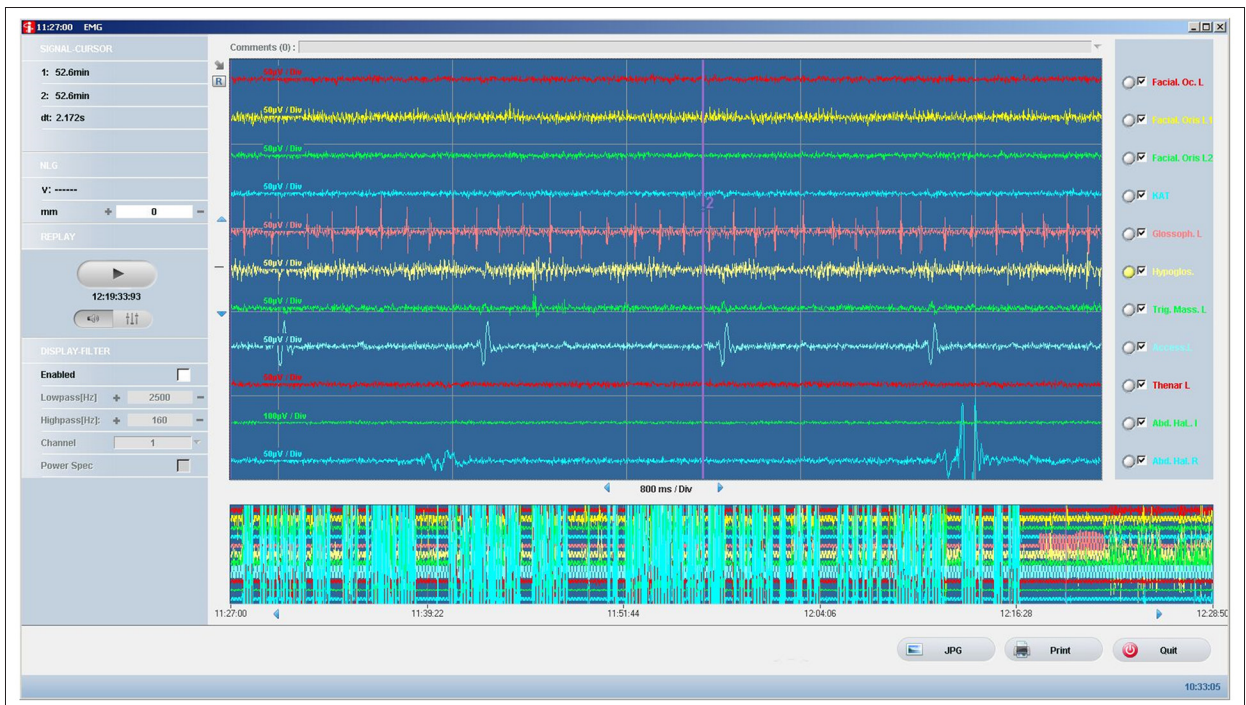


Figure 4. Electromyography recording at the end of the operation, depicting no abnormal findings.

Initially, the cystic part of the lesion was evacuated, followed by the rest of the tumor along with its capsule using CUSA (Cavitron ultrasonic surgical aspirator). Intraoperative neurophysiologic monitoring (IONM) included somatosensory-evoked potentials (SSEPs), muscle evoked potentials (MEPs) using electrical transcranial stimulation and free-running electromyography (EMG). The tumor bed was irrigated just before closure with 30 mL of injection solution: oxygen hyperoxide to water

(7% v/v). The dilution of H₂O₂ that was used was 1: 1, a concentration that is commonly used and considered safe. At that point, a sudden arterial pressure decline from 115/80 mmHg to 80/50 mmHg and bradycardia were recorded, lasting a few seconds; both were self-remitted. The IONM remained uneventful during the operation, which lasted 5 hours (Figure 4).

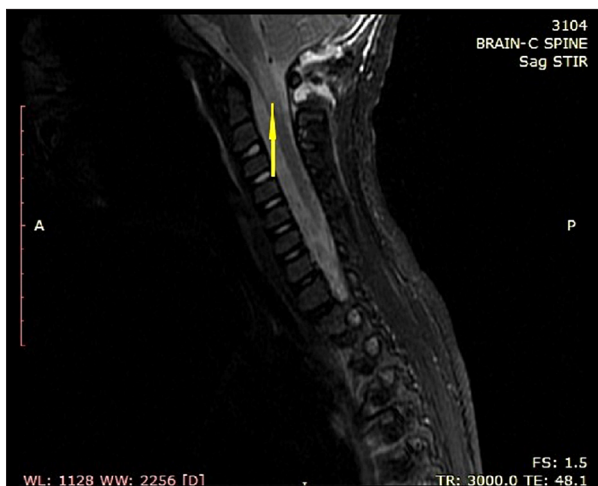

Figure 5. Post-operative magnetic resonance imaging (MRI), sagittal Short tau inversion recovery (STIR) sequence, depicting the infarction in the region of the cervico-medullary junction (yellow arrow).

After the operation, the patient was transferred to our intensive care unit. On awakening, the patient had impaired movement of the upper and lower extremities, which was observed from C5 dermatome and downwards. All muscle groups of arms had grade zero power; she was able to withdraw faintly from painful stimuli. Deep tendon reflexes were absent.

She was immediately taken for a second MRI study including MRI of the cervical spine. The imaging study displayed an ischemic infarct extending from the cervico-medullary junction to the C3 myelotome (Figure 5). The MRI of the brain depicted total tumor resection and relevant postoperative findings (Figure 6). Due to the relevant MRI findings, an MR angiogram (including both carotid and vertebral arteries) was performed at the same session, which did not reveal any abnormal vertebral artery findings (occlusion or vasoconstriction). A therapeutic dose of low molecular heparin was administered. Once the patient was hemodynamically stabilized, she was transferred back to our clinic. In the meantime, her histopathological examination verified the existence of a pilocytic astrocytoma grade I.

From postoperative day 14, the patient began to regain sensations. After 1 month, the SSEPs were eventful, revealing prolonged latency of cortical components of median and tibial nerves bilaterally.

Her clinical status was complicated from postoperative day 6 with transient diabetes insipidus and hyperpyrexia lasting a week. Infection *loci* were excluded with thorax plain radiographs, urine cultures, and blood cultures. C-reactive protein was unremarkable (0.3 mg/dL). Water deprivation investigation regarding diabetes insipidus was not available. Decreased

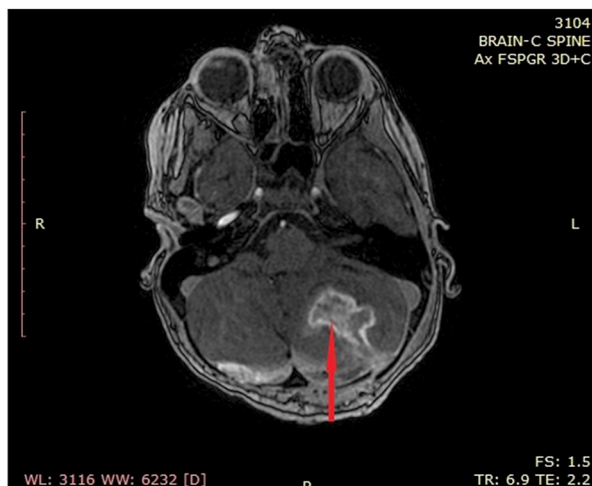

Figure 6. Post-operative magnetic resonance imaging (MRI), axial fast spoiled gradient echo-dual echo (FSPGR) 3D sequence after contrast administration, depicting the resection site of the tumor cavity without any residual remnants (red arrow).

weight with concomitant polyuria led us to the diagnosis. Response to desmopressin, later on, confirmed the diagnosis.

During her hospitalization, the patient was under the care of physiotherapists and became mobile within 2 months, using a wheelchair, with residual spasticity and vegetative dysfunction. Her final muscle power status 2 years after the operation was grade 3 in hip and knee extensors and grade 4 in ankles and toes. In her upper extremities, her forearm extensors' power was grade 3, whereas she was unable to perform shoulder abduction and elevation. During the follow-up period of 2 years, the patient was examined regularly (at 3- to 6-month intervals) and no evidence of tumor recurrence were found.

Discussion

Ischemic infarcts of the spinal cord after posterior fossa tumor resections are well documented in the literature, especially when the procedure is performed with the patient in the classical prone position [1]. Infarct are associated with dysfunctional blood regulation either as an insufficiency of compressed arterial [5] or venous compartments, or to microcirculatory disorders such as hypotension and venous air emboli [6]. Embolic incidences when the procedure is performed with the patient in the prone position have also been described [7].

In addition, the adverse sequelae of H_2O_2 occurring with the patient in the supine position have also been reported [8]. The surgeon should be aware that for every 1 cc of H_2O_2 , 10 cc of O_2 are produced [9]. The rapidly freed oxygen may directly irritate the nuclei of cardiovascular function of the brainstem

or have an indirect effect due to the thermal energy of the dissociation [9]. Additionally, the trigemino-cardiac reflex, which is a well-described clinical reaction, is also attributed to the liberation of abundant O₂ from H₂O₂, capable of exerting a considerable simultaneous chemical irrigation on the dura covering of the brain surface and being innervated by V2 and V3 (trigeminal nerve division 2nd, 3rd) nerve roots [10].

Because in our patient's case, H₂O₂ was used to control diffuse bleeding in the surgical bed, we considered it the main contributor to the infarction that was distributed across the cervico-medullary junction.

The exact mechanism of hemostasis is unknown, but it is thought that it might arise from a combination of its vasoconstrictive and vaso-occlusive effects. It is well known to facilitate platelet aggregation, thrombus formation, and small blood vessel occlusion due to microbubbles [11]. It is capable of modifying vascular tone, which could be the major mechanism that governs the vasoactive properties of H₂O₂ [11].

As our patient was cardiopulmonary stable with no alteration of end-tidal carbon dioxide, we excluded major venous oxygen embolism as a contributing cause. Our case report suggests that H₂O₂ use should be limited to select situations, such as abscesses, and not used for mechanical hemostasis.

Venous infarcts attributed to stasis and congestion leading to decreased perfusion pressure of the spinal cord and ischemia have been reported in the literature [12]. The placement of chest rolls has been considered a cause of increased venous pressure, which, when combined with transient arterial hypotension, can result in ischemia [12]. The distribution of the infarction, as was shown on postoperative imaging in our case, was not compatible with being of venous origin. It was insufficient to explain the later identification of pituitary dysfunction, as no infarction was delineated in the vicinity of that gland.

When transient diabetes insipidus and hypothalamic dysfunction is considered in the context of hypoperfusion of the rather labile ischemia hypothalamus heat stroke [13]. Its clinical manifestation can reliably be attributed to impairment of the inferior hypophyseal artery and portal system of the hypophyseal gland [14]. Regarding delayed clinical manifestation of diabetes insipidus, it could be attributed to the depletion of the storage of anti-diuretic hormone (ADH) of the posterior pituitary gland in the previous days, due to its transient functional impairment, which was replaced after the gland regained normal function.

Another concern arises regarding the inability of intraoperative monitoring to reliably recognize the ongoing neuronal disability, which could alter our anesthetic and surgical strategy.

In our patient's case, intraoperative monitoring including SSEPs, MEPs, and EMG despite the intrinsic limitations of their role in cerebral and spinal cord surgery [15]. They are affected by anesthesia and muscle relaxants, and due to the variability of their amplitude and latency, no robust standard exists regarding warning signals.

Modi et al. [16] reported a similar case with a false-negative MEP result and postoperative paraplegia in a 15-year-old patient who had an operation for kyphoscoliosis. During the procedure there was massive blood loss leading to a cellular lesion, spinal cord infarct, but not related to a direct mechanical injury. That adverse event had similarities to our patient case reported here. In addition, a recent retrospective study assessing 62 038 spine procedures for a variety of pathologies, concluded that false negatives appear at a rate of 0.04% [17].

In general, there is a discrepancy regarding the exact effect of anesthesia parameters. Hence co-evaluation is needed for action potentials of synaptic transmission, increased refractory period of axons, dampening of motor neuron excitability, and lowering the threshold of GABA-ergic inhibitory neurons [18]. Thus, clinicians need to recognize the shortcomings of intraoperative monitoring, especially in children.

Intraoperative monitoring for these entities is considered to be challenging, especially for infratentorial tumor surgery [19], which is even more pronounced when peculiarities regarding children are considered. A child's nervous system is by definition immature, so myelination and synaptogenesis have not yet been completed. Anthropometrical parameters of young children are different from adults and shock artifact is more of an issue, due to the close proximity of stimulation to the recording electrodes. Additionally, the net effect of anesthesia is quite different when depression of evoked potential due to halothane anesthesia is considered, which has been well described as more pronounced in children.

Pediatric low-grade astrocytoma (PLGA) is considered to represent the most common variant of brain neoplasms in the pediatric population, worldwide. This subgroup includes pilocytic astrocytoma (World Health Organization [WHO] grade I), as well as diffuse astrocytoma (WHO grade II). It has a different clinical behavior compared to malignant astrocytoma (WHO grades III and IV) of childhood, which exhibits a rapid and relentless clinical course. PLGAs are characterized by a noticeably and diverse clinical behavior, with ranging from tumors without evidence of growth, to tumors highlighted by relentless progression [20,21]. Additionally, it is well documented that more than half of PLGAs will show signs of evolution after initial chemotherapy [22], which necessitated the use successive chemotherapy regimens and other treatment modalities. Although H₂O₂ has been historically used as a hemostatic

agent, due to its proven vasoconstrictive and vaso-occlusive effects, the liberation of large quantities of very reactive oxygen free radicals during its contact with viable tissues and the resulting exothermic reaction, should be taken into consideration, and H_2O_2 should be used judiciously. Despite all necessary precautions undertaken in our patient's case, a combination of side effects of H_2O_2 were observed. The combination of vasoconstriction and trigemino-cardiac reflex seemed to be responsible for the early onset establishment of ischemia in the region of the cervico-medullary junction and the delayed clinical presentation of diabetes insipidus.

The 2 major factors that could be implicated in the pathogenesis of the infarction at the cervico-medullary junction and the development of diabetes insipidus were injury (dissection, thrombosis) of the vertebral arteries, which could result in occlusion or diminution of flow through the vessels, and local and systemic effects of H_2O_2 .

We argue against the possibility that the prone position was the reason for the underlying pathologic substrate for several reasons. A major consideration was that if vertebral artery injury occurs, the area of infarction is expected to be much more extended than was seen in our patient's case. Although one vertebral artery may be more prevalent than the other, and in such a scenario, occlusion of the non-dominant artery could be clinically undetectable, in our patient's case, this was not verified by the postoperative MR angiography. We did not detect occlusion of the main branch of either of the vertebral arteries. Even if temporary vasospasm was considered, it would have to involve small branches of the vertebral artery that specifically nourish the cervico-medullary junction territory, a scenario that would be difficult to verify. Thus, this could not explain the occurrence of diabetes insipidus, as the vertebral arteries were not responsible for the arterial supply of the posterior lobe of the pituitary gland. Instead, the simultaneous occurrence of ischemic changes at the cerebral regions not nourished by the same arterial branches and that were not in nearby territories, enhanced the scenario that a systemic effect of H_2O_2 was the main culprit of the underlying pathologic entity. This concept could be combined with the aforementioned bradycardia and hypotension that was recorded after the use of H_2O_2 , which could render some brain regions more susceptible to ischemic injury due to diminished blood perfusion.

Quadriplegia is a well described, though rare, disastrous complication associated with procedures for the resection of posterior fossa tumors. Its pathophysiologic substrate is related to prolonged focal pressure on the spinal cord, due to the acute flexion of the head. To the best of our knowledge, the exact prevalence of ischemic infarcts of the spinal cord after posterior fossa tumor resection has not been well described, even when the pediatric population is considered [23].

Even though H_2O_2 was applied locally, the systemic reaction (bradycardia and hypotension) was directly linked to its use. We hypothesized that this systemic adverse effect was able to affect the posterior pituitary/hypothalamus region, even though it is located far from the posterior aspect of pons/medulla. The rationale for this hypothesis is based on the assumption that this circulatory abnormality could preferentially affect watershed vascular areas of the brain, which are nourished by small diameter vascular channels, as the aforementioned brain region. The ischemic infarct of the lower brainstem and upper cervical spine could also be the cause of a local vasoconstrictive effect of H_2O_2 in the posterior circulation. We argue against the possibility of venous injury during surgery as the cause of the ischemic infarct of the brainstem-upper cervical spine, as the postoperative MR angiography did not reveal any relevant findings. A limitation to our hypothesis exists; the gold standard examination to demonstrate a vascular injury (arterial or venous) is digital subtraction angiography, which was not performed, because the MR angiography did not raise any diagnostic concerns. Besides that, the scenario of a local venous injury during the operation does not adequately explain the concurrent occurrence of an infarction in the territory of the posterior pituitary/hypothalamus.

Conclusions

In conclusion, it is well-known that several theories have been proposed to explain the development of cervical cord infarction as a complication of operations performed for infratentorial lesions [1]. One theory refers to the position of the patient (sitting versus prone) during surgery, which results in compromised flow of the anterior spinal artery. Another scenario is excessive flexion of the cervical spine with or without overstretching and compression of the cervical cord, which is capable of exerting prolonged focal pressure on the neural tissue. The resulting overstretching of the cervical cord could similarly act by decreasing the vascular supply of the relevant spinal neural tissue, especially that supplied by the longitudinal arteries. This would have been a logical explanation if the delayed appearance of diabetes insipidus had not occur. Instead, the combined effects of H_2O_2 (local vasoconstriction and cardiac effects) could create the required spectrum of circumstances to explain this devastating clinical situation.

To the best of our knowledge, this is the first documented case of such a side effect attributable to the use of H_2O_2 intraoperatively, even after precautions.

Conflict of interest

None.

Abbreviations

H₂O₂ – hydrogen peroxide; **TCR** – trigemino-cardiac reflex; **O₂** – oxygen; **V₂, V₃** – trigeminal nerve division 2nd, 3rd; **CC** – cubic centimeter; **ADH** – anti-diuretic hormone; **SSEPs** – somatosensory-evoked potentials; **MEPs** – motor evoked potentials; **EMG** – electromyography; **GABA** – gamma-aminobutyric acid; **CT** – computed tomography; **MRI** – magnetic resonance imaging;

CUSA – cavitron ultrasonic surgical aspirator; **IONM** – intraoperative neurophysiologic monitoring; **EMG** – electromyography; **FSE** – fast spin echo (sequence); **STIR** – short tau inversion recovery; **FSPGR** – fast spoiled gradient echo-dual echo (3D); **PLGA** – pediatric low-grade astrocytomas; **WHO** – World Health Organization; **MAPK** – mitogen-activated protein kinase; **PA** – pilocytic astrocytoma.

References:

1. Martínez-Lage JF, Almagro MJ, Izura V et al: Cervical spinal cord infarction after posterior fossa surgery: A case-based update. *Childs Nerv Syst*, 2009; 25(12): 1541–46
2. Mesiwala Ali H, Farrell L, Santiago P et al: The effects of hydrogen peroxide on brain and brain tumors. *Surg Neurol*, 2003; 59: 398–407
3. Drougard A, Fournel A, Valet P, Knauf C: Impact of hypothalamic reactive oxygen species in the regulation of energy metabolism and food intake. *Front Neurosci*, 2015; 9: 56
4. Chena SH, Linc MT, Chang CP: Ischemic and oxidative damage to the hypothalamus may be responsible for heat stroke. *Curr Neuropharmacol*, 2013; 11: 129–40
5. Young ML, Smith DS, Martagh F et al: Comparison of surgical and anesthetic complications in neurosurgical patients experiencing venous air embolism in the sitting position. *Neurosurgery*, 1986; 18(2): 157–61
6. Nakamura K: Central circuits for body temperature regulation and fever. *Am J Physiol Regul Integr Comp Physiol*, 2011; 301: R1207–28
7. Haller G, Faltin-Traub E, Faltin D, Kern C: Oxygen embolism after hydrogen peroxide irrigation of a vulvar abscess. *Br J Anaesth*, 2002; 88: 597–99
8. Prabhakar H, Rath GP, Dash HH: Bradycardia following hydrogen peroxide irrigation during posterior fossa surgery. *Anaesthesia*, 2006; 61(9): 914
9. Prabhakar H, Rath GP: Venous oxygen embolism with use of hydrogen peroxide during craniotomy in the supine position. *J Clin Neurosci*, 2008; 15: 1072
10. Dsouza S, Parakh A, Sarma C et al: Intraoperative oxygen embolus and tension pneumocephalus: Is hydrogen peroxide the culprit? *J Neuroanaesthesiol Crit Care*, 2017; 4: 114–16
11. Thakali K, Davenport L, Fink GD, Watts SW: Pleiotropic effects of hydrogen peroxide in arteries and veins from normotensive and hypertensive rats. *Hypertension*, 2006; 47: 482–87
12. Edgcombe NH, Carter K, Yarrow S: Anaesthesia in the prone position. *Br J Anaesth*, 2008; 100(2): 165–83
13. Curras-Collazo MC, Patel UB, Hussein MO: Reduced susceptibility of magnocellular neuroendocrine nuclei of the rat hypothalamus to transient focal ischemia produced by middle cerebral artery occlusion. *Exp Neurol*, 2002; 178: 268–79
14. Chen SH, Lin MT, Chang CP: Ischemic and oxidative damage to the hypothalamus may be responsible for heat stroke. *Curr Euro Pharmacol*, 2013; 11: 129–40
15. Deletis V, Sala F: Intraoperative neurophysiologic monitoring of the spinal cord and spine surgery: A review focus on the corticospinal tracts. *Clin Neurophysiol*, 2008; 119: 248–64
16. Modi HN, Shank CD, Rozelle CJ, Walters BC: Guidelines for the use of electrophysiological monitoring for surgery of the human spinal column and spinal cord. *Neurosurgery*, 2017; 81: 713–32
17. Tamkus AA, Rice KS, McCaffrey MT: Perils of intraoperative neurophysiological monitoring: Analysis of “false-negative” results in spine surgeries. *Spine J*, 2018; 18: 276–84
18. Lo YL, Tan YE, Raman S et al: Systematic re-evaluation of intraoperative motor-evoked potential suppression in scoliosis surgery. *Scoliosis Spinal Disord*, 2018; 13: 12
19. Keewon K, Charles C, Moon-suk B et al: Intraoperative neurophysiological monitoring: A review of techniques used for brain tumor surgery in children. *J Korean Neurosurg Soc*, 2018; 61(3): 363–75
20. Hawkins C, Erin Walker E, Mohamed N et al: BRAF-KIAA1549 fusion predicts better clinical outcome in pediatric low-grade astrocytoma. *Clin Cancer Res*, 2011; 17(14): 4790–98
21. Nicolin G, Parkin P, Mabbott D et al: Natural history and outcome of optic pathway gliomas in children. *Pediatr Blood Cancer*, 2009; 53: 1231–37
22. Opocher E, Kremer LC, Da Dalt L et al: Prognostic factors for progression of childhood optic pathway glioma: A systematic review. *Eur J Cancer*, 2006; 42: 1807–1.
23. Jagannathan S, Krowvidi H: Anaesthetic considerations for posterior fossa surgery. *Continuing Education in Anaesthesia Critical Care & Pain*, 2014; 14(5): 202–6