




CASE REPORT

Case Report: Orbital metastasis as the presenting feature of lung cancer [version 1; referees: 2 approved, 1 approved with reservations]

Sunil Munakomi , Samrita Chaudhary, Pramod Chaudhary, Jagdish Thingujam, Bijoy Mohan Kumar, Iype Cherian

Department of Neurosurgery, Nobel Teaching Hospital, Biratnagar, Nepal




v1 First published: 05 Apr 2017, 6:430 (doi: [10.12688/f1000research.11247.1](https://doi.org/10.12688/f1000research.11247.1))
 Latest published: 05 Apr 2017, 6:430 (doi: [10.12688/f1000research.11247.1](https://doi.org/10.12688/f1000research.11247.1))

Abstract

Orbital metastasis from lung cancer as an initial presenting symptom is a rare entity, which may paradoxically delay the diagnosis and initiation of correct management, due to the confusion of it being primary orbital pathology. Herein we report a case of a 58 year old woman, who presented with painful orbital swelling along with diminution in her vision. The patient was initially thought to have a primary eye lesion; however chest X-ray was suggestive of a lung mass, which was confirmed by chest computed topography followed by ultrasound guided fine needle aspiration cytology. The patient was then referred to a cancer centre for further management. This case report aims to increase the knowledge about this metastasis as a probable cause of orbital symptoms in certain subsets of patients, so that correct therapeutic decisions may be made in the future.

Open Peer Review

Referee Status:   

	Invited Referees		
	1	2	3
version 1			
published 05 Apr 2017	report	report	report

- Matteo Giaj Levra**, Centre Hospitalier Universitaire de Grenoble France
- Trevor K. Rogers**, Doncaster Royal Infirmary UK
- Luis Rafael Moscote-Salazar**, RED LATINO (Latin American Trauma & Intensive Neurocare Organization) Colombia, **Guru Dutta Satyarthee**, All India Institute of Medical Sciences (AIIMS) India

Discuss this article

Comments (0)

Corresponding author: Sunil Munakomi (sunilmunakomi@gmail.com)

How to cite this article: Munakomi S, Chaudhary S, Chaudhary P *et al.* **Case Report: Orbital metastasis as the presenting feature of lung cancer [version 1; referees: 2 approved, 1 approved with reservations]** *F1000Research* 2017, 6:430 (doi: [10.12688/f1000research.11247.1](https://doi.org/10.12688/f1000research.11247.1))

Copyright: © 2017 Munakomi S *et al.* This is an open access article distributed under the terms of the [Creative Commons Attribution Licence](#), which permits unrestricted use, distribution, and reproduction in any medium, provided the original work is properly cited. Data associated with the article are available under the terms of the [Creative Commons Zero "No rights reserved" data waiver](#) (CC0 1.0 Public domain dedication).

Grant information: The author(s) declared that no grants were involved in supporting this work.

Competing interests: No competing interests were disclosed.

First published: 05 Apr 2017, 6:430 (doi: [10.12688/f1000research.11247.1](https://doi.org/10.12688/f1000research.11247.1))

Introduction

Orbital metastasis as the initial presenting symptom from a metastatic lung lesion is a rare entity, occurring at an incidence of approximately 7%^{1,2}. However, this should be kept as one of the differentials in any patients presenting with orbital symptoms, so as to frame an accurate and effective plan of management. Occasionally such rare presentations would invariably lead to a delay in the correct diagnosis, thereby increasing the risk of loss of vision, which decreases the quality of life of patients³. Poor management also increases the odds of progressing the tumor stage. Herein, we report one such case in a 58 year old woman, who presented with unilateral peri-orbital swelling and diminution of vision. Following detailed examination and investigations, the patient was found to harbor a malignant lung lesion.

Case report

A 58 year old woman from central Nepal presented to our outpatient clinic with a history of painful swelling around her right eye for two months. The patient also complained of diminishing vision in the same eye. The vision in the patient's left eye had been previously lost following an injury during childhood. There was no other relevant family information or any significant past medical or surgical illnesses of the patient. Local examination revealed presence of peri-orbital swelling in the right eye with restricted eye movements (Figure 1). The patient's visual acuity in the same eye was restricted to only perception to light. Funduscopy revealed the presence of papilledema. Remaining physical examinations were normal.

Radio-imaging of the patient's orbits revealed the presence of hyperostotic changes in the right orbit, with presence of enhancing lesions on the right globe with extension to the para-nasal sinuses and also invasion along the dural base in the anterior cranial fossa (Figure 2 and Figure 3). The initial differential diagnosis was an infective pathology. However, the patient was not immuno-compromised.

A chest X-ray was performed as a routine work up, which inadvertently revealed the presence of an elevated right hemi-diaphragm with presence of right para-hilar mass (Figure 4). Further evaluation through chest computed tomography confirmed the finding of a right para-hilar mass (Figure 5).

We discussed with the patient and her relatives the possibility of the eye findings to be related to the lung lesion and recommended approaches to obtain a definitive diagnosis. Ultrasound guided fine needle aspiration cytology (FNAC) from the lung lesion

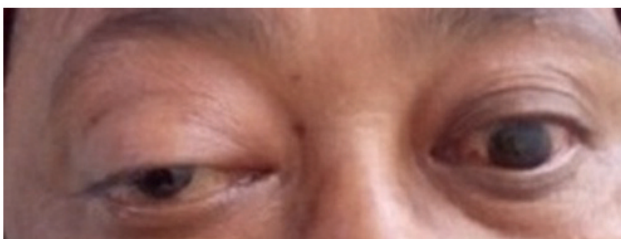

Figure 1. Image showing right sided peri-orbital swelling.

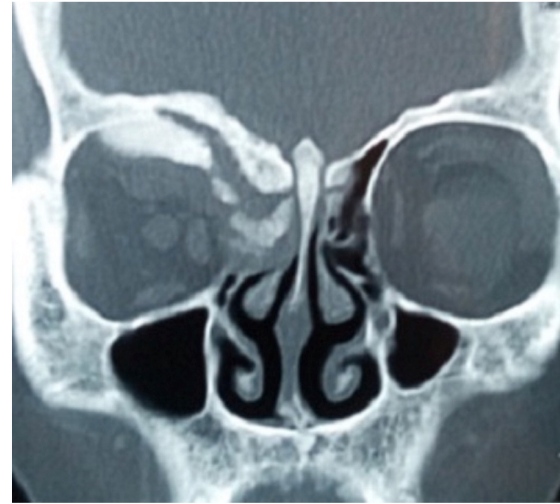

Figure 2. Image showing abnormal hyperostotic changes within the right orbit in the computed tomography scan.

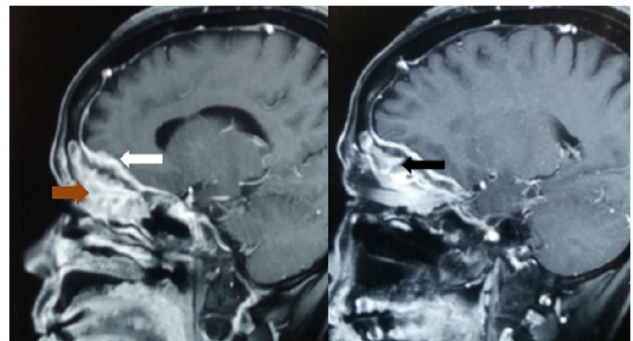


Figure 3. Image showing enhancing lesion in the right globe (black arrow) with extension to para-nasal sinuses (brown arrow) and invasion to the dura of anterior cranial fossa (white arrow).

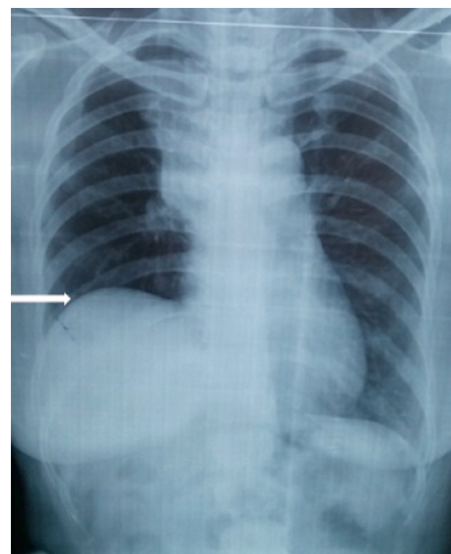


Figure 4. Chest X-ray showing elevated right hemi-diaphragm (white arrow) and right para-hilar mass.

revealed findings suggestive of a malignant lung disease (Figure 6). Diagnostic biopsy from the nasal endoscope confirmed the metastatic nature of the disease from the lung (Figure 7). Therefore, a diagnosis of metastatic lung disease to the orbit was finally confirmed.

The patient was started on a steroid therapy (injection dexamethasone at 8mg stat followed by 4 mg every eight hours), which decreased the swelling on the patient's eye and improved visual acuity to finger counting within a period of 1 week. This further hinted at compressive rather than infiltrative effect on the optic nerve by the lesion. The patient was counseled and then immediately referred to the National Cancer Centre, Kathmandu, Nepal for further management with systemic chemo-radiation therapy after evaluation. Since the patient had a single and minimally functioning eye left, the decision was taken not to surgically decompress the lesion from the orbit. The patients was initially started on chemotherapy with a further plan of management to be tailored as per the clinical response seen in the patient.

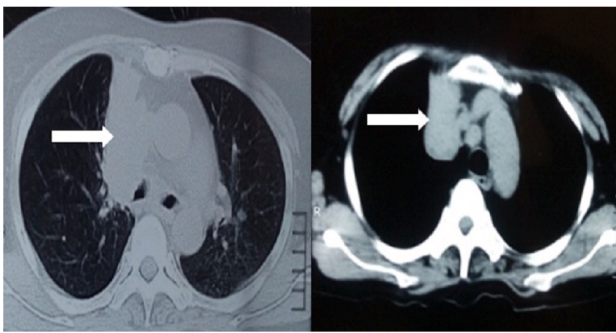


Figure 5. Chest computed tomography revealing presence of right para-hilar lung mass (white arrows).

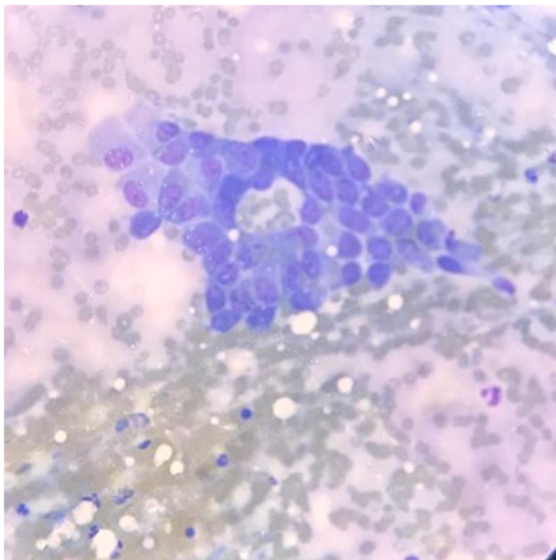


Figure 6. Fine needle aspiration cytology from the lung mass revealing the presence of malignant cells.

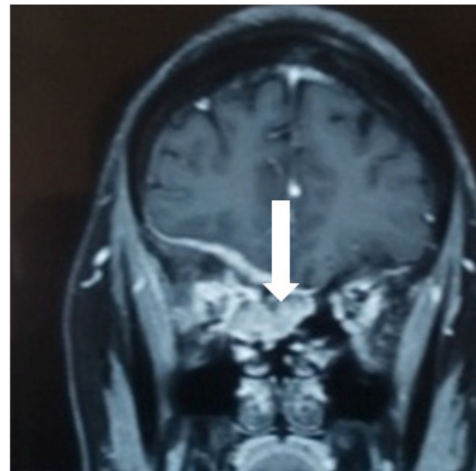


Figure 7. Computed tomography image revealing the presence of invasion of para-nasal sinuses by the lesion.

Initially, metastatic deposits causing eye swelling in the patient was not suspected. It was serendipity that the routine chest X-ray gave a clue to the presence of a lung mass. Even a small delay may have had a disastrous impact on the outcome of the vision in the patient.

Discussion

Metastatic disease to the orbit is a rare epiphenomenon occurring in only 7% of all cancers¹⁻². Of these, symptoms related to orbital metastasis presents earlier to that of the primary lesion in around 20% of patients². Breast, prostate and lung carcinomas are the usual primaries in many cases of metastatic lesions to the orbit⁴⁻⁵. Lid swelling are a common presentation in such metastatic lesions⁵, which can paradoxically delay the actual diagnosis accounting for the benign orbital lesions. Diplopia is the most common presenting symptom in metastatic lesions, while proptosis or visual loss is seen in patients with primary orbital neoplasms⁶. Loss of vision can be due to either direct infiltration to the optic nerve or subsequent to the mass effect. Rarely, is it subsequent to paraneoplastic phenomenon mainly from lung carcinoma. Pain resulting from perineural invasion is typical for metastatic orbital lesions⁶.

Diagnosis can be confirmed with FNAB, which has a diagnostic accuracy of more than 90%⁷. Further investigations need to be carried out to stage the tumor before embarking on the management option; PET scan is a rapid viable model for assessment tumor staging⁸.

Surgical debulking is the cornerstone of management in patients with diminished vision subsequent to optic nerve compression. This was not attempted in our case, since it was the only functioning eye in the patient and that was functionally impaired as well. Surgical removal of the lesion may be locally effective in few patients having symptoms, due to compression on the optic nerve following raised intra-orbital pressure⁶. However, chemo-radiation is usually preferred to surgery because it is non-invasive. Chemotherapy, especially platinum base regimens, is chosen for small cell lung cancer over radiation because of the risk of damage to the eye lens.

For non-small cell cancers, either photon radiation of 30–40 Gy, or newer frontiers, such as tyrosine kinase inhibitors, are the mainstay of treatment. However, overall prognosis, despite systemic therapy, is poor with a median survival of little over 1 year, and only 27% of patients surviving for more than two years^{6,9–13}. Compared to breast cancer, lung cancers metastasize early to the orbit and also have shorter median survival time¹⁴.

Conclusions

It is prudent to provide a strategy for management of cases presenting with eye symptoms, so that rare causes, such as metastatic lesions, are not omitted. Such a strategy would certainly help in providing an early and effective treatment plan in such patients with metastatic orbital lesions. This would increase the chance of improving vision, escalate quality of life and also initiate early cancer therapy following appropriate work up and staging.

Consent

Both written and verbal informed consent for publication of images and clinical data related to this case was sought and obtained from the patient.

Author contributions

SC, PC and JT prepared the manuscript, did the literature review and collected the data. SM, IC and BMK revised, edited and approved the final manuscript.

Competing interests

No competing interests were disclosed.

Grant information

The author(s) declared that no grants were involved in supporting this work.

References

- Shields JA, Shields CL, Brotman HK, *et al.*: **Cancer metastatic to the orbit: the 2000 Robert M. Curts Lecture.** *Ophthal Plast Reconstr Surg.* 2001; **17**(5): 346–354. [PubMed Abstract](#)
- Macedo JE, Machado M, Araújo A, *et al.*: **Orbital metastasis as a rare form of clinical presentation of non-small cell lung cancer.** *J Thorac Oncol.* 2007; **2**(2): 166–167. [PubMed Abstract](#) | [Publisher Full Text](#)
- Holland D, Maune S, Kovács G, *et al.*: **Metastatic tumors of the orbit: a retrospective study.** *Orbit.* 2003; **22**(1): 15–24. [PubMed Abstract](#) | [Publisher Full Text](#)
- Eliassi-Rad B, Albert DM, Green WR: **Frequency of ocular metastases in patients dying of cancer in eye bank populations.** *Br J Ophthalmol.* 1996; **80**(2): 125–128. [PubMed Abstract](#) | [Publisher Full Text](#) | [Free Full Text](#)
- Nelson CC, Hertzberg BS, Klintworth GK: **A histopathologic study of 716 unselected eyes in patients with cancer at the time of death.** *Am J Ophthalmol.* 1983; **95**(6): 788–793. [PubMed Abstract](#) | [Publisher Full Text](#)
- De Potter P: **Ocular manifestations of cancer.** *Curr Opin Ophthalmol.* 1998; **9**(6): 100–4. [PubMed Abstract](#) | [Publisher Full Text](#)
- Tijl JW, Koornneef L: **Fine needle aspiration biopsy in orbital tumours.** *Br J Ophthalmol.* 1991; **75**(8): 491–492. [PubMed Abstract](#) | [Publisher Full Text](#) | [Free Full Text](#)
- Manohar K, Mittal BR, Bhattacharya A, *et al.*: **Orbital Metastases as Presenting Sign of Lung Carcinoma: Detection of Primary Malignancy and Disease Burden by F-18 FDG PET/CT.** *Nucl Med Mol Imaging.* 2012; **46**(1): 73–75. [PubMed Abstract](#) | [Publisher Full Text](#) | [Free Full Text](#)
- Glasburn JR, Klionsky M, Brady LW: **Radiation therapy for metastatic diseases involving the orbit.** *Am J Clin Oncol.* 1984; **7**: 145–148. [Publisher Full Text](#)
- Ferry AP, Font RL: **Carcinoma metastatic to the eye and orbit. I. A clinicopathologic study of 227 cases.** *Arch Ophthalmol.* 1974; **92**(4): 276–286. [PubMed Abstract](#) | [Publisher Full Text](#)
- Sun L, Qi Y, Sun X, *et al.*: **Orbital metastasis as the initial presentation of lung adenocarcinoma: a case report.** *Onco Targets Ther.* 2016; **9**: 2743–2748. [PubMed Abstract](#) | [Publisher Full Text](#) | [Free Full Text](#)
- Koma Y, Goto K, Yoshida C, *et al.*: **Orbital metastasis secondary to pulmonary adenocarcinoma treated with gefitinib: a case report.** *J Med Case Rep.* 2012; **6**: 353. [PubMed Abstract](#) | [Publisher Full Text](#) | [Free Full Text](#)
- Mori H, Maekawa N, Satoda N, *et al.*: **[A case of primary lung cancer with initial symptoms due to orbital metastases].** *Nihon Kokyuki Gakkai Zasshi.* 2003; **41**(1): 19–24. [PubMed Abstract](#)
- Freedman MI, Folk JC: **Metastatic tumors to the eye and orbit. Patient survival and clinical characteristics.** *Arch Ophthalmol.* 1987; **105**(9): 1215–9. [PubMed Abstract](#) | [Publisher Full Text](#)

Open Peer Review

Current Referee Status:



Version 1

Referee Report 17 May 2017

doi:10.5256/f1000research.12134.r22711

✓ **Luis Rafael Moscote-Salazar¹, Guru Dutta Satyarthee²**

¹ Department of Neurosurgery, RED LATINO (Latin American Trauma & Intensive Neurocare Organization), Bogotá, Colombia

² Department of Neurosurgery, Neurosciences Centre, All India Institute of Medical Sciences (AIIMS), New Delhi, Delhi, India

An interesting case of orbital metastasis of lung adenocarcinoma is presented. Lung cancer is one of the leading causes of death globally. Adenocarcinoma occupies the first place in epidemiological frequency (50%) is also one of the most frequent types of tumors in non-smokers. They are classified into 4 histological types: acinar, papillary, bronchioalveolar and the mucin secretory variety.

The adenocarcinoma originates from mucoproduative cells. Adenocarcinoma metastasis to the orbit is infrequent. In the orbits most of the tumors are primary, but they can also reach the orbit by contiguity. At least 50% of patients with orbital metastasis are unaware of the existence of a primary tumor. Metastasis is less frequent than ocular metastasis. Apparently, there is no predilection for any specific orbit and their bilateral appearance is rare. The most frequent orbital metastasis are breast, lung and orbit. They have been described a 5 types of clinical syndromes associated with orbital metastasis. The first type is mass syndromes.

In more than 50% of cases. This syndrome causes displacement of the eyeball. The second type is infiltrative. The third type is an inflammatory type. The fourth type of metastasis is called functional and is frequently located in apex orbital. The last type is silent, does not produce symptomatology. The use of fine needle aspiration biopsy is an excellent option when orbital metastasis is suspected. Finally, the patients with orbital metastasis are not candidates for orbit surgery for extirpation of the tumor mass. The realization of surgery does not offer a cure. In cases of slow-growing tumors, the extirpation of metastasis and the primary tumor may improve the prognosis. Management strategies include radiation therapy. Sometimes the use of radiation therapy results in vision recovery.

Is the background of the case's history and progression described in sufficient detail?

Yes

Are enough details provided of any physical examination and diagnostic tests, treatment given and outcomes?

Yes

Is sufficient discussion included of the importance of the findings and their relevance to future understanding of disease processes, diagnosis or treatment?

Yes

Is the case presented with sufficient detail to be useful for other practitioners?

Yes

Competing Interests: No competing interests were disclosed.

We have read this submission. We believe that we have an appropriate level of expertise to confirm that it is of an acceptable scientific standard.

Referee Report 04 May 2017

doi:10.5256/f1000research.12134.r22208



Trevor K. Rogers

Chest Clinic, Doncaster Royal Infirmary, Doncaster, UK

A major deficiency of the report is the lack of characterization of the tumour. Whilst the CT imaging is convincing for a lung primary it should at the very least be commented whether the tumour was non-small cell (and ideally whether adeno-, squamous or neuroendocrine) or small cell -the H&E slide is suspicious of the latter, although I am not a pathologist. Ideally it would have been established if it were TTF1 positive supporting a lung origin.

I am surprised that the smoking status of the patient is not reported.

The sentence: "Orbital metastasis as the initial presenting symptom from a metastatic lung lesion is a rare entity, occurring at an incidence of approximately 7%" - the denominator 7% of what? - I suspect orbital tumours. Metastasis spelt incorrectly

The sentence: "Poor management also increases the odds of progressing the tumor stage." is incorrect: the disease stage is already IV. What I think they mean is that patients may become too unwell for anticancer treatments and the visual impairment worse and harder to palliate.

Funduscopy should be funduscopy

"PET scan is a rapid viable model for assessment tumor staging" PET scanning would only be considered if simpler imaging modalities failed to identify a primary site, as in a lung cancer, staging is already M1b

I remain troubled by the 7% figure which is repeated in the discussion. If orbital metastasis really occurred in 7% of all cancers it would not be regarded as that rare. Reference 2 does not give any evidence for the 7% figure quoted, does not give the denominator (either) and I can't see any evidence for the 7% figure quoted in reference 1.

The outcome for the patient is not described with sufficient detail, including length of survival.

Is the background of the case's history and progression described in sufficient detail?

No

Are enough details provided of any physical examination and diagnostic tests, treatment given and outcomes?

No

Is sufficient discussion included of the importance of the findings and their relevance to future understanding of disease processes, diagnosis or treatment?

Yes

Is the case presented with sufficient detail to be useful for other practitioners?

No

Competing Interests: No competing interests were disclosed.

I have read this submission. I believe that I have an appropriate level of expertise to confirm that it is of an acceptable scientific standard, however I have significant reservations, as outlined above.

Referee Report 02 May 2017

doi:[10.5256/f1000research.12134.r22210](https://doi.org/10.5256/f1000research.12134.r22210)



Matteo Giaj Levra

Thoracic Oncology Unit, Centre Hospitalier Universitaire de Grenoble, Grenoble, France

This is an interesting case report, about an unusual site of metastasis in lung cancer patient. There are details about the symptoms, diagnosis and symptomatic treatment of the orbital metastasis.

I would only add if there was a history of tobacco exposure (not cited in the text).

Is the background of the case's history and progression described in sufficient detail?

Yes

Are enough details provided of any physical examination and diagnostic tests, treatment given and outcomes?

Yes

Is sufficient discussion included of the importance of the findings and their relevance to future understanding of disease processes, diagnosis or treatment?

Yes

Is the case presented with sufficient detail to be useful for other practitioners?

Yes

Competing Interests: No competing interests were disclosed.

I have read this submission. I believe that I have an appropriate level of expertise to confirm that it is of an acceptable scientific standard.
