



Since January 2020 Elsevier has created a COVID-19 resource centre with free information in English and Mandarin on the novel coronavirus COVID-19. The COVID-19 resource centre is hosted on Elsevier Connect, the company's public news and information website.

Elsevier hereby grants permission to make all its COVID-19-related research that is available on the COVID-19 resource centre - including this research content - immediately available in PubMed Central and other publicly funded repositories, such as the WHO COVID database with rights for unrestricted research re-use and analyses in any form or by any means with acknowledgement of the original source. These permissions are granted for free by Elsevier for as long as the COVID-19 resource centre remains active.

6. Kluytmans M, Buiting A, Pas S, Bentvelsen R, van den Bijllaardt W, van Oudheusden A, et al. SARS-CoV-2 infection in 86 health-care workers in two Dutch hospitals in March 2020. *medRxiv*. 2020. doi:10.1101/2020.03.23.20041913.
7. Spinato G, Fabbris C, Polessel J, Gazzador D, Borsetto D, Hopkins C, et al. Alterations in smell or taste in mildly symptomatic outpatients with SARS-CoV-2 infection. *JAMA*. 2020;323:2089–90. doi:10.1001/jama.2020.6771.
8. Zhan M, Qin Y, Xue X, Zhu S. Death from Covid-19 of 23 Health Care Workers in China. *N Engl J Med*. 2020;382:2267–8. doi:10.1056/NEJMc2005696.
9. Hunter E, Price DA, Murphy E, van der Loeff I, Baker KF, Lendremet D, et al. First experience of COVID-19 screening of health-care workers in England. *Lancet*. 2020;395:e77–78. doi:10.1016/S0140-6736(20)30970-3.
10. Zhou F, Yu T, Du R, Fan G, Liu Y, Liu Z, et al. Clinical course and risk factors for mortality of adult inpatients with COVID-19 in Wuhan, China: a retrospective cohort study. *Lancet*. 2020;395:1054–62. doi:10.1016/S0140-6736(20)30566-3.
11. European Centre for Disease Prevention and Control. Guidance for discharge and ending isolation in the context of widespread community transmission of COVID-19, 8 April 2020. Stockholm: ECDC; 2020.
12. Estudio ENE-COVID19: primera ronda. Estudio nacional de seroepidemiología de la infección por SARS-CoV-2 en España. Informe preliminar 13 de mayo de 2020.



Necrotizing tracheobronchitis with endotracheal tube obstruction in COVID-19 patients[☆]

Traqueobronquitis necrosante con obstrucción del tubo endotraqueal en pacientes COVID-19

Dear Director,

COVID-19 is an infection caused by the SARS-CoV-2 virus that can cause severe or fatal complications in high-risk patients. Though rare, we have observed several cases of necrotizing tracheobronchitis, which causes airway obstruction, with necrotic and hemorrhagic debris that obstruct the trachea and bronchi.

This problem has already been described in infections caused by the H1N1 flu virus, bacterial infections, and diseases such as rheumatoid arthritis or ulcerative colitis. It is associated with the formation of bronchial blood clots, bronchial hypersecretion, and presence of bacte-

13. Shields AM, Faustini SE, Perez-Toledo M, Jossi S, Aldera EI, Allen JD, et al. SARS-CoV-2 seroconversion in health care workers. *medRxiv*. 2020. doi:10.1101/2020.05.18.20105197.
14. Hains DS, Schwaderer AL, Carroll AE, Starr MC, Wilson AC, Amanat F, et al. Asymptomatic Seroconversion of Immunoglobulins to SARS-CoV-2 in a Pediatric Dialysis Unit. *JAMA*. 2020;323:2424–5. doi:10.1001/jama.2020.8438.

J.C. Trullàs^{a,b,*}, I. Vilardell^c, M. Blasco^d, J. Heredia^e

^a *Servicio de Medicina Interna, Hospital de Olot i comarca de la Garrotxa, Olot, Girona, Spain*

^b *Laboratori de Reparació i Regeneració Tissular (TR2Lab), Facultat de Medicina, Universitat de Vic – Universitat*

^c *Salud Laboral, Hospital de Olot i comarca de la*

^d *Garrotxa, Olot, Girona, Spain*

^e *Seguridad del paciente, Hospital de Olot i comarca de la Garrotxa, Olot, Girona, Spain*

^e *Dirección médica, Hospital de Olot i comarca de la Garrotxa, Olot, Girona, Spain*

Corresponding author.

E-mail address: jctv5153@comg.cat (J.C. Trullàs).

2254-8874/ © 2020 Elsevier España, S.L.U. and Sociedad Española de Medicina Interna (SEMI). All rights reserved.

rial lung infection.^{1,2} Said clots provoke severe obstruction of the bronchial lumen, leading to an increase in airway pressure and making ventilation impossible. In many cases, it is necessary to exchange the endotracheal tube urgently.

This complication, which we believe may influence a patient's prognosis, entails an increase in risk of contagion by healthcare personnel; it is one of the procedures classified as of greatest risk for viral transmission from patients to healthcare personnel, along with bronchoscopy, aerosol therapy, nebulization, and aspiration of secretions. The aim of our study is to analyze the prognosis of patients with COVID-19 who have undergone an episode of endotracheal tube obstruction that made exchanging it necessary.

During the period from February to April 2020, 26 patients were hospitalized in our ICU: 22 (84.7%) required invasive mechanical ventilation (Table 1). Of those, 16 (72.7%) presented with at least one episode of endotracheal tube obstruction that required an exchange. What's more, none of these incidents occurred before the seventh day mechanical ventilation, with a mean day of onset of 10.5 days. Some patients even required a tube exchange on more than one occasion. The mean number of exchanges was 1.46.

If we compare patients who had endotracheal tube obstruction and tube exchange (which we will group

[☆] Please cite this article as: Pérez Acosta G, Santana-Cabrera L. Traqueobronquitis necrosante con obstrucción del tubo endotraqueal en pacientes COVID-19. *Rev Clin Esp*. 2020;220:531–533.

Table 1 Differences between patients with COVID-19 according to whether they presented with endotracheal tube obstruction due to necrotizing tracheobronchitis.

	Total N=22	Endotracheal obstruction N=16 (72.7%)	No endotracheal obstruction N=6 (27.2%)
Mean age (years)	65.2	63.9	68.7
Males (%)	13 (59.1%)	9 (56.2%)	4 (66.7%)
Duration of mechanical ventilation (days)	20.5	21.6	17.5
Tracheotomy	16 (72.7%)	13 (81.2%)	3 (18.8%)
Mean number of days on which endotracheal tube obstruction occurred		10.5 days	
Mean number of occasions in which endotracheal tube exchange was required		1.5 times	
Development of respiratory superinfections	11(50%)	8 (72.7%)	3 (17.3%)
Use of azithromycin	15 (68.2%)	9 (60%)	6(40%)
Stay in the ICU (days)	22.5	23.8	19
Death	5 (22.72%)	3 (60%)	2(40%)

ICU: intensive care unit.

together in the first group) with those who did not need it (the second group), we can observe that there are significant differences in the days they required mechanical ventilation (21.6 vs. 17.5 days). Therefore, a greater number of patients in the first group required a tracheotomy before proceeding to be weaned off of mechanical ventilation (81.2% vs. 18.7%).

Eleven patients developed respiratory superinfection as a complication during hospitalization, eight of which (72.7%) were among those who presented with endotracheal tube obstruction.

In regard to treatment received, it should be noted that 100% of patients who did not present with obstruction received treatment with azithromycin, in contrast to the first group, in which only 56.2% did.

Lastly, five patients died: Three (60%) in the first group, a greater proportion than in the second group, which did not have obstruction.

Our experience with patients diagnosed with pneumonia due to COVID-19 is that they present with an elevated frequency of necrotizing tracheobronchitis after the first week of mechanical ventilation, causing a sudden obstruction of the endotracheal tube that requires its immediate exchange due to hypoxemia and the inability to ventilate the patients.

In this disease, an increase in the immune response is described, with a generalized migration of proinflammatory cytokines and an increase in fibrin deposits observed in the pulmonary area due to deregulation between the coagulation and fibrinolytic systems.³ This entails a problem that can affect biosecurity when it comes to management by healthcare personnel, as it requires immediate intervention. In other infections, upon histopathological examination of the trachea and bronchial samples, mononuclear cell infil-

tration has been seen in the mucosa and submucosa with desquamation of the bronchial epithelium accompanied by congestion, hemorrhage, and necrosis in the tracheo-bronchial area.^{4,5}

It is necessary to study the protective association of the use of azithromycin in this problem associated with COVID-19—a drug has also been used in other clinical entities—due to its anti-inflammatory and immunomodulating effect.^{6,7}

References

1. Chang J, Kim TO, Yoon JY, Kho BG, Shin HJ, Kwon YS, et al. Necrotizing tracheobronchitis causing airway obstruction complicated by pandemic 2009 H1N1 influenza: a case report. *Medicine (Baltimore)*. 2020;99:e18647.
2. Okada Y, Okada A, Narumiya H, Iiduka R, Katsura K. Bloody bronchial cast formation due to alveolar hemorrhage associated with H1N1 influenza infection. *Intern Med*. 2017;56:2747–51.
3. Whyte CS, Morrow GB, Mitchell JL, Chowdary P, Mutch NJ. Fibrinolytic abnormalities in acute respiratory distress syndrome (ARDS) and versatility of thrombolytic drugs to treat COVID-19. *J Thromb Haemost*. 2020, doi:10.1111/jth.14872.
4. Manna SS, Shaw J, Tibby SM, Durward A. Treatment of plastic bronchitis in acute chest syndrome of sickle cell disease with intratracheal rhDNase. *Arch Dis Child*. 2003;88:626–7.
5. Takahashi S, Nakamura M. Necrotizing tracheobronchitis caused by influenza and *Staphylococcus aureus* co-infection. *Infection*. 2018;46:737–9.
6. Krempaska K, Barnowski S, Gavini J, Hobi N, Ebener S, Simillion C, et al. Azithromycin has enhanced effects on lung fibroblasts from idiopathic pulmonary fibrosis (IPF) patients compared to controls [corrected]. *Respir Res*. 2020;21:25 [Erratum in: *Respir Res*. 2020;21:29].
7. Schultz KD, Oermann CM. Treatment of cast bronchitis with low-dose oral azithromycin. *Pediatr Pulmonol*. 2003;35:139–43.

G. Pérez Acosta, L. Santana-Cabrera*

Servicio de Medicina Intensiva, Complejo Hospitalario Universitario Insular-Materno Infantil, Las Palmas de Gran Canaria, Las Palmas, Spain

*Corresponding author.

E-mail address: lsancabx@gobiernodecanarias.org
(L. Santana-Cabrera).

2254-8874/ © 2020 Elsevier España, S.L.U. and Sociedad Española de Medicina Interna (SEMI). All rights reserved.

Pregnancy and perinatal outcome of a woman with COVID-19 infection[☆]



Pronóstico perinatal y de la paciente embarazada con infección por COVID-19

Dear Director,

The COVID-19 coronavirus infection, first identified in December 2019 in Wuhan (China), is an emerging disease that has seen a rapid increase in the number of infected patients worldwide. Not much data are available on how it affects pregnancy. However, there is information on infection by other highly pathogenic coronaviruses, such as severe acute respiratory syndrome (SARS) or Middle East respiratory syndrome (MERS), during pregnancy.¹ Thus, it is known that the mortality rate of SARS infection was 10% in the general population and up to 25% in pregnant women, with no intrauterine transmission demonstrated.²

Our 44-year-old patient was 29+2 weeks pregnant, did not have any pathological medical history of interest, and had had no recent travel or contact with known infected patients. She came to the center for symptoms that had been ongoing for 12 days that consisted of odynophagia, dry cough, and, in recent days, fever of 39.5 °C.

The obstetric examination was normal. A COVID-19 PCR was performed, which was positive. On the blood test, of note were leukocytes 20,900 (98% PMN), lymphopenia with lymphocytes 200, D-dimer 578 ng/ml, CRP 28 mg/dl, LDH 223 U/l, and procalcitonin 5.33 ng/ml. From a respiratory point of view, with oxygen via nasal cannula at 3 L, she had a PO₂ of 140 mmHg. On the chest X-ray, multilobar bilateral pulmonary infiltrates with an interstitial-alveolar pattern were observed, with alveolar consolidation in the left upper lobe, blunting of the costophrenic angles, and right fissural thickening due to a small amount of pleural effusion (Fig. 1).

Treatment was started with lopinavir/ritonavir, chloroquine, ceftriaxone, and azithromycin. At 48 h, the patient was more tachypneic and, in a few hours, her mechanics of breathing worsened with respiratory acidosis and severe hypoxemia. She required orotracheal intubation and connection to mechanical ventilation.

In light of the clinical deterioration, the gynecology department was contacted, which decided to start fetal lung maturation by means of two 12-mg doses of betamethasone

separated by 12 h. At 24 h, a cesarean section was performed in the ICU box without complications for the mother or the child. COVID-19 infection was ruled out in the child. In the following days, there was a progressive improvement in oxygenation and the weaning process was begun.

This patient had satisfactory progress, which is also corroborated by various studies on COVID-19 published during this pandemic. A study of 38 pregnant women infected with the virus demonstrated that maternal prognosis was much better than in previous coronaviruses; none died nor were there any cases of intrauterine transmission to the fetus.³ In another study on nine pregnant patients with pneumonia due to COVID-19, the authors described the clinical similarity to cases reported in nonpregnant adult patients. No cases of vertical transmission were found.⁴

In another study on 15 patients, it was observed that pregnancy and birth did not worsen the course of symptoms, which was mild with a satisfactory recovery in all cases.⁵ Lastly, another study on 16 pregnant women recommended that if there is an indication for obstetric surgery or if there is critical COVID-19 disease, the voluntary interruption of the pregnancy will not increase the newborn's risk of premature birth or anoxia and is beneficial for the treatment of the mother's pneumonia. Like the above authors, they found no cases of COVID-19 among the neonates.⁶

Therefore, to date, there is no evidence that this coronavirus behaves differently in pregnant women than in the general population nor is there evidence of maternal-fetal transmission. With all of these studies, on February 5, 2020, a meeting of Chinese and North American experts was held in which they drafted a series of specific recommendations for the management of pregnant women and neonates born to mothers with suspected or confirmed coronavirus (COVID-19)

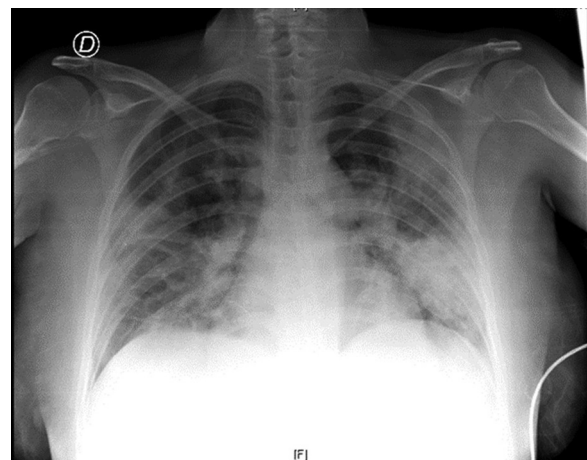


Figure 1 Chest X-ray upon hospital admission.

[☆] Please cite this article as: González Romero D, Ocampo Pérez J, González Bautista L, Santana-Cabrera L. Pronóstico perinatal y de la paciente embarazada con infección por COVID-19. Rev Clin Esp. 2020;220:533–534.