

# Three-Dimensional Diagnosis in Orbital Reconstructive Surgery

Chingiz R. Rahimov, Sirajaddin G. Ahmadov, Masuma Ch. Rahimli<sup>1</sup>, Ismayil M. Farzaliyev

Department of Oral and Maxillofacial Surgery, Azerbaijan Medical University, Baku, Azerbaijan, <sup>1</sup>Medical Faculty, Yeditepe University, Istanbul, Turkey

## Abstract

**Introduction:** Orbital floor fractures are common among mid-face fractures. The general aim of treatment is to restore orbital volume and anatomy with grafts or reconstructive materials. Malpositioning of the implants and inadequate volume restorations are common complications of these procedures. The aim of our study is to present the surgical outcomes of orbital reconstruction aided by our algorithm of patient-specific virtual planning. **Materials and Methods:** The current study was performed on 77 patients with orbital wall fractures who were categorized into two groups: Group A – 42 patients (virtual planning) and Group B – 35 patients (traditional approach). Criteria of analysis included the presence of diplopia postoperatively and duration of surgical procedures. **Results:** Diplopia was recorded right after surgery in 16 cases (38.1%) of Group A and in 12 cases (34.3%) of Group B. However, 6 months postreconstruction, residual diplopia was recorded in 4 cases (9.5%) of Group A and in 12 cases (34.3%) of Group B. Mean operation time in Group A for the patients with isolated zygoma fracture was 2.23 h; for isolated orbital wall fracture was 1.98 h; and for combined zygoma, orbital wall, and facial bone fracture was 3.07 h. In Group B, these indexes were 3.47, 2.05, and 3.31 h, respectively. **Conclusions:** Application of virtual planning could significantly improve postoperative outcomes in orbital reconstruction. However, application of this technology could be limited by complicated defects of the orbital walls, which would require complex shape of the implant that might be difficult to be prevented virtually.

**Keywords:** Orbital floor fractures, orbital reconstruction, virtual planning

## INTRODUCTION

Orbital blow-out fractures are the most common type of fractures among mid-face and typically are the result of blunt trauma.<sup>[1-7]</sup> Generally, the forces required to break the superior and lateral walls are greater than one required for thin medial and inferior walls. Disruption of any of these structures may lead to expansion of orbital volume and may result in enophthalmos, diplopia, and impaired ocular mobility.<sup>[7]</sup> The gold standard of orbital wall fracture treatment is surgical reconstruction, with fracture site exposure, freeing tissue prolapsed into the fracture site, and re-approximating of the orbital wall support, usually with an orbital implant.<sup>[1]</sup> It is usually achieved by transconjunctival, subciliary, and coronal approaches and implementation of graft and reconstructive materials, including bones, cartilage, titanium, and resorbable mesh.<sup>[8,9]</sup>

One of the most important issues related to surgical reconstruction of the orbit is its precise preoperative planning.

Conventionally, it was done by means of clinical evaluation, function test, and conventional radiology, including computed tomography (CT) scan. Nevertheless, CT data could be represented as three-dimensional (3D) imaging, which is hard to apply in orbital reconstruction cases.

Recent advances in computer technology allows the operator to manipulate CT scan data and produce patient-specific virtual planning as well as plastic models and customized implant materials.<sup>[9]</sup>

**Address for correspondence:** Prof. Chingiz R. Rahimov, Bakichanov Street 23, AZ 1022, Baku, Azerbaijan. E-mail: chinrahim@hotmail.com

**Received:** 09-08-2019

**Revised:** 23-10-2019

**Accepted:** 02-12-2019

**Published:** 08-06-2020

This is an open access journal, and articles are distributed under the terms of the Creative Commons Attribution-NonCommercial-ShareAlike 4.0 License, which allows others to remix, tweak, and build upon the work non-commercially, as long as appropriate credit is given and the new creations are licensed under the identical terms.

**For reprints contact:** WKHLRPMedknow\_reprints@wolterskluwer.com

**How to cite this article:** Rahimov CR, Ahmadov SG, Rahimli MC, Farzaliyev IM. Three-Dimensional diagnosis in orbital reconstructive surgery. *Ann Maxillofac Surg* 2020;10:3-9.

### Access this article online

Quick Response Code:



**Website:**  
www.amsjournal.com

**DOI:**  
10.4103/ams.ams\_183\_19

Aim of the current study is to represent surgical outcomes of orbital reconstruction aided by algorithm of virtual preoperative planning.

**MATERIALS AND METHODS**

The current study was performed within 2007–2018 in the Department of Oral and Maxillofacial Surgery of a medical university on 77 patients with orbital wall fractures. All patients were categorized into two groups: Group A–42 patients (operated in 2015–2018 by implementation of virtual planning protocol) and Group B – 35 patients (retrospective analysis of patients operated by implementation of traditional approach in 2007–2017) [Table 1]. From all cases in 41 patients the cause of trauma was home injury, in 24 – traffic accident, 7 - industrial accident, in 5 – sport injury [Figure 1]

Isolated blow-out fracture was recorded in 32 cases, orbital walls fracture was associated with fracture of malar bone and other bones of facial skeleton in 22 cases, isolated malar bone fracture in 15 cases, orbital wall fracture associated with fracture of other bones of facial skeleton in 4 cases, and malar bone fracture associated with fracture of other bones of facial skeleton in 4 cases [Figure 2].

The method of virtual planning composed from several steps represented on the following layout:

CT scan data acquired for each patient was uploaded to virtual planning software (Materialise NV, Leuven, Belgium) and patient-specific preplanning was done. Virtual workflow was executed on Intel® Core™ i7-6700K CPU at 4.00 GHz 16.0 GB RAM, 10 GB Video RAM GeForce GTX 760 hardware [Figure 3].

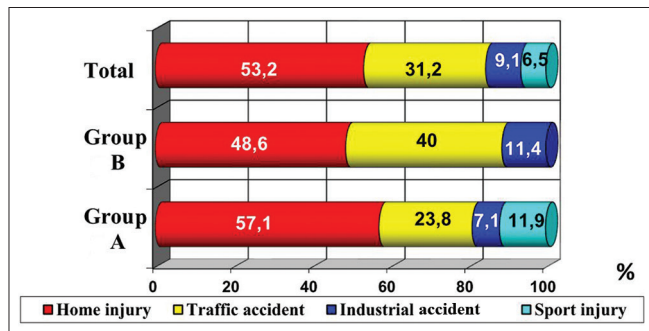


Figure 1: Distribution of the cause of injury

**RESULTS**

Statistical analysis was performed by the means of Microsoft Excel 2013 and MedCalc Software, Seoul, Republic of Korea. The main indicator of success of surgical procedure was considered as the presence or absence of diplopia, as the indicator of function restoration. Within the current study, one analyzed the fact of diplopia directly after surgical reconstruction [Table 2] and 6 months after the procedure [Table 3].

The presence of diplopia directly after surgical procedure was noted in 16 cases (38.1%) of Group A, and in 12 cases (34.3%) of Group B, it could be considered as equivalent of these parameters. However, these parameters were different in 6-month postreconstruction period; thus, residual diplopia was found in 4 cases (9.5%) of Group A and in 12 cases (34.3%) of Group B [Figure 4]. The main causes of diplopia in Group A were postoperative edema and temporary paresis of oculomotor muscles, which disappeared over time.

Another parameter was the time of admission to hospital and timing of surgical reconstruction and the influence of residual diplopia. Thus, the majority of patients were admitted to hospital immediately after injury (57.1%), some of patients a month after injury (31% Group A and 22.9% Group B), and some more than 1 month after injury (11.9% Group A and 20% Group B) [Table 4].

There was no significant difference detected between groups, thus concluding that timing of surgical reconstruction has no influence on the results of the current study.

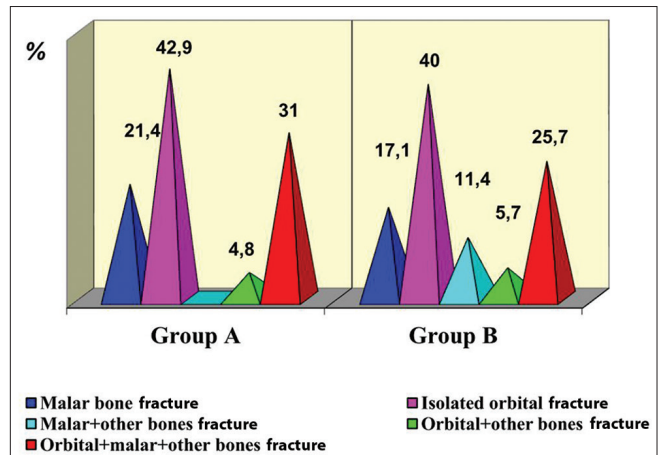


Figure 2: Distribution of the site of injury

Groups	Number of patients					
	Male		Female		Total	
	n (%)	Age	n (%)	Age	n (%)	Age
Group A	35 (45.4)	31.1±1.86 (9-57)	7 (9.1)	29.7±2.76 (15-36)	42 (54.5)	30.8±1.60 (9-57)
Group B	26 (33.8)	31.2±1.85 (17-55)	9 (11.7)	39.8±3.79 (26-62)	35 (45.5)	33.4±1.78 (17-62)
Total	61 (79.2)	31.1±1.32 (15-60)	16 (20.8)	35.4±2.70 (15-62)	77 (100)	32.0±1.19 (9-62)

The last parameter, which was included in analysis was duration of surgical procedure and hospitalization time within groups according to the clinical diagnosis [Table 5].

The mean operation time in Group A for patients with isolated malar bone fracture was 2.23 h; for patients with isolated orbital walls fracture was 1.98 h; and for patients with combined fracture of malar bone, orbital walls, and different bones of facial skeleton was 3.07 h. In Group B, these indexes were 3.47, 2.05, and 3.31 h, respectively. It was also determined that hospitalization time in Group A for patients with isolated malar bone fracture was 6.9 days; for patients with isolated orbital walls fracture was 7.5 days; and for patients with combined fracture of malar bone, orbital walls, and different bones of facial skeleton was 10.1 days. In Group B, these indices were 14.2, 8.7, and 16.5 days, respectively [Figure 5].

**Table 2: The features of diplopia within investigation groups directly after surgical reconstruction**

Features of diplopia	Indexes within groups		P
	Absolute (%)		
	A group, n=42	B group, n=35	
Diplopia is absent	26 (61.9)	23 (65.7)	>0.05
Diplopia present in quadrant	16 (38.1)	12 (34.3)	
Upper	8 (19.0)	9 (25.7)	>0.05
Upper, central	6 (14.3)	-	>0.05
Upper, lower	1 (2.4)	-	>0.05
Upper, medial	1 (2.4)	-	>0.05
Upper, lateral	-	2 (5.7)	>0.05
Upper, lateral, central	-	1 (2.9)	>0.05
Upper, lateral, inferior	-	-	-
Upper, inferior, central	-	-	-
Lateral, inferior	-	-	-

As a conclusion, the application of virtual preoperative planning could significantly reduce operation and hospitalization time due to less trauma and more predictable surgical outcomes.

**Case presentation 1**

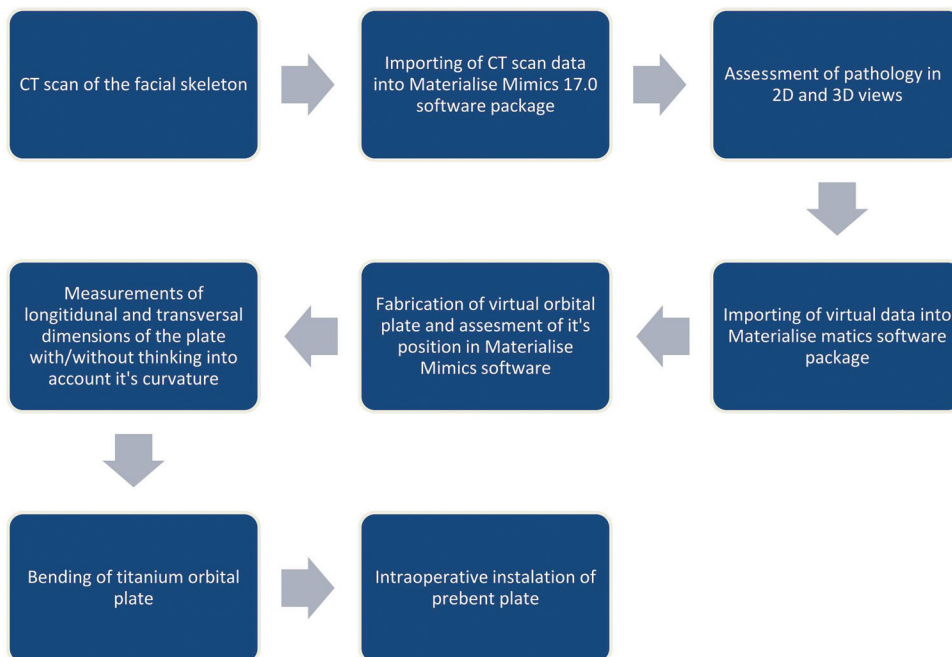
A 28-year-old male presented to the department with diplopia while looking up. On anamnesis, he had blunt trauma over the right orbit 7 days ago. Clinical evaluation revealed slight enophthalmos on the right side with limitations of the movement of right eyeball in the upper quadrant [Figure 6]. CT scan showed isolated blow-out fracture associated with protrusion of right rectal muscle toward orbital wall defect [Figure 7].

According to the suggested protocol of preoperative planning, patient’s CT scan data was used for preplanning and virtual fabrication of orbital plate [Figure 8].

Surgical procedure was done under general anesthesia; transconjunctival approach was used. After visualization of inferior orbital margin, dissection of orbital floor was performed. Prolapsed periorbital tissues were extracted from the defect region and titanium orbital plate was placed on the defect area without any additional corrections. No significant postoperative complications were recorded. Complete reduction of enophthalmos and diplopia after 1 month of surgery was recorded. The eyeball movements were adequate [Figure 9]. Postoperative CT scan showed adequate positioning of orbital plate both in 2D and 3D views [Figure 10].

**Case presentation 2**

A 52-year-old male was presented with symptoms of severe diplopia, significant enophthalmos on the right side, as well as deformity in the region of right orbito-zygomatic complex



**Figure 3:** Layout 1 – Algorithm of preoperative virtual planning

[Figure 11 and 12]. On anamnesis, he had traumatic injury a month ago and underwent open reduction and internal fixation in a different hospital.

CT scan showed significant posttraumatic deformity and dislocation of right malar bone associated with defect of right orbital floor and prolapse of orbital content toward the defect region [Figure 13].

The decision of reconstruction of right zygoma-orbital complex was made. It was preplanned to perform osteotomy of fractured segments, their repositioning with subsequent fixation, as well as reconstruction of the right orbital floor by the means of titanium orbital implant. All preoperative planning was done according to the suggested algorithm [Figure 14].

Surgical reconstruction was done under general anesthesia through subciliary and suprabrow approaches. First step was to achieve the access to orbital floor and old hardware, which was removed. On the next step, tetrapod osteotomy of malar bone was done. After complete mobilization of malar bone, it was fixed on its new position according to preoperative virtual planning measurements. Once malar bone was fixed, all prolapsed soft tissues were extracted from defect region

and the pre-bent orbital implant was installed according to the preoperative virtual planning data [Figure 15].

No significant complications occurred in the postoperative period. A month after surgical reconstruction, the symptoms of enophthalmos and diplopia had disappeared. Eyeball movements as well as facial esthetics were accepted as reasonable [Figures 16 and 17].

Postoperative CT scan showed positioning of right malar bone and orbital implant to be adequate [Figure 18].

### DISCUSSION

Isolated orbital fractures are encountered in 4%–16% of all facial fractures, and orbital fractures compose 30%–55% of

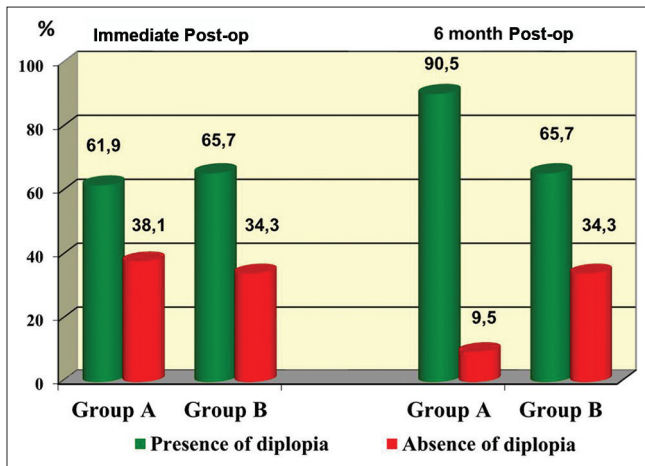


Figure 4: Comparison of diplopia indexes within groups directly and 6 months after surgical reconstruction

Table 3: The features of diplopia within investigation groups 6 months after surgical reconstruction

Features of diplopia	Indexes within groups		P
	Absolute (%)		
	A group, n=42	B group, n=35	
Diplopia is absent	38 (90.5)	23 (65.7)	<0.05
Diplopia present in quadrant	4 (9.5)	12 (34.3)	
Upper	3 (7.1)	9 (25.7)	<0.05
Upper, central	-	-	-
Upper, lower	-	-	-
Upper, medial	1 (2.4)	-	>0.05
Upper, lateral	-	2 (5.7)	>0.05
Upper, lateral, central	-	1 (2.9)	>0.05
Upper, lateral, inferior	-	-	-
Upper, inferior, central	-	-	-
Lateral, inferior	-	-	-

Table 4: Timing of surgical reconstruction within groups

Administration to hospital	Indexes within groups, absolute (%)			
	A group, n=42		B group, n=35	
	A group, n=42		B group, n=35	
Same day	24 (57.1)	20 (57.1)		
1 month after injury	13 (31.0)	8 (22.9)		
More than 1 month after injury	5 (11.9)	7 (20.0)		

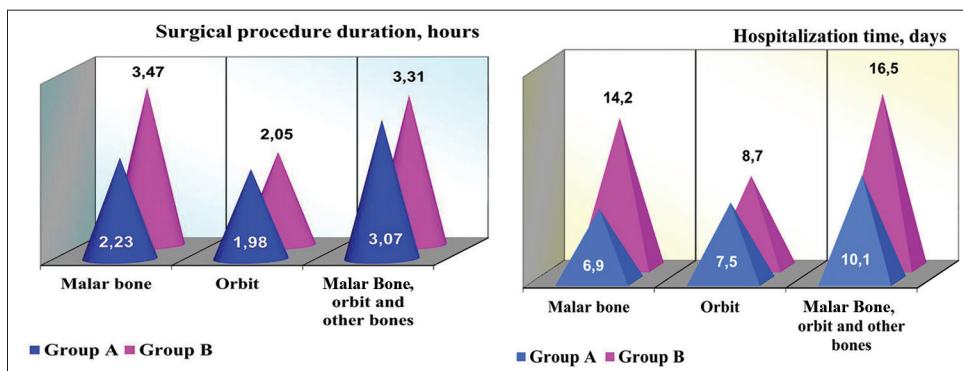
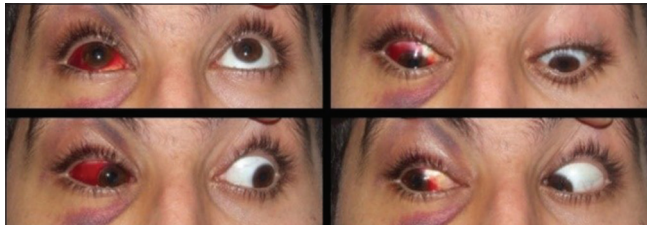

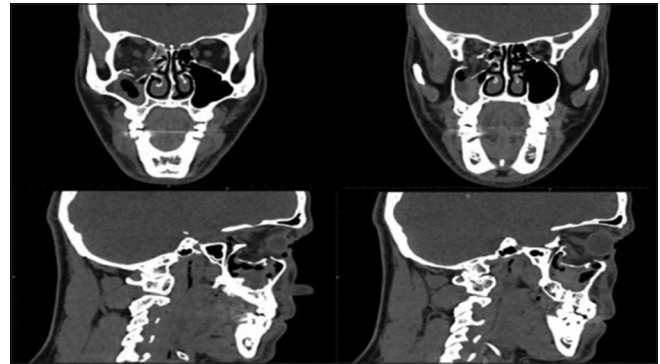
Figure 5: The indexes of surgical procedure duration within groups according to diagnosis

**Table 5: The indexes of surgical procedure duration and hospitalization time within groups according to clinical diagnosis**

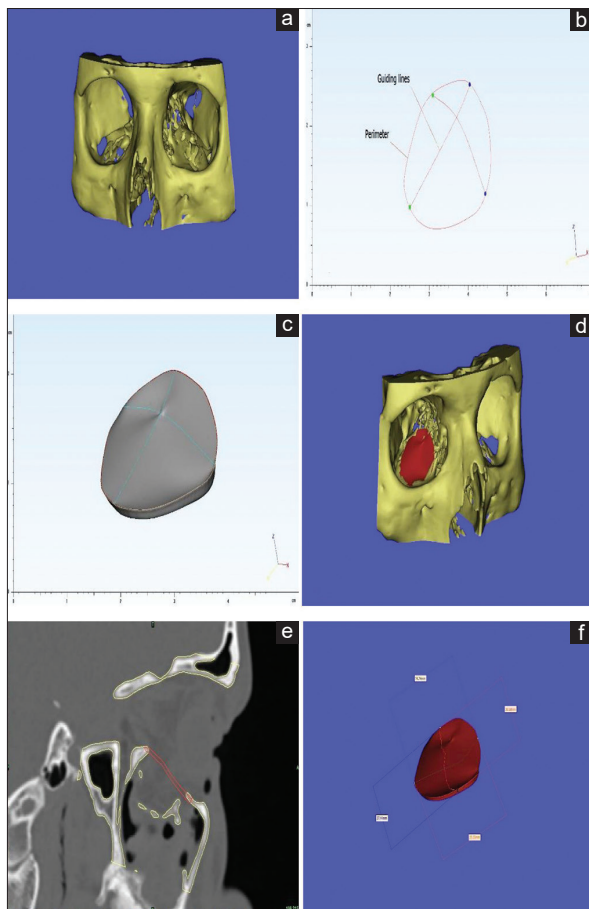
Clinical diagnosis	Indexes within groups			
	A group, n=42		B group, n=35	
	Duration of procedure, h	Hospitalization time, days	Duration of procedure, h	Hospitalization time, days
Malar bone	2.23±0.17 (1.5-3.33)	6.9±1.63 (2-16)	3.47±0.69 (2-6), $P_1>0.05$	14.2±3.17 (1-23), $P_1<0.05$
Orbit	1.98±0.05 (1.66-2.66)	7.5±1.17 (1-17)	2.05±0.17 (1.5-4), $P_1>0.05$	8.7±1.54 (2-21), $P_1>0.05$
Malar, orbit and other bones	3.07±0.25 (2.16-5.66)	10.1±2.58 (2-40)	3.31±0.44 (2-7), $P_1>0.05$	16.5±1.87 (8-30), $P_1<0.01$



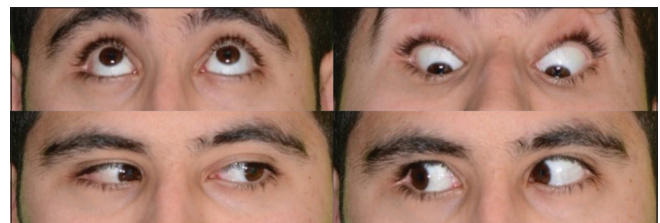**Figure 6:** Clinical evaluation of the patient revealed limitation of the movements of the right eyeball in the upper quadrant



**Figure 7:** Computed tomography scan of the patient: Inferior orbital wall fracture and protrusion of orbital components toward defect



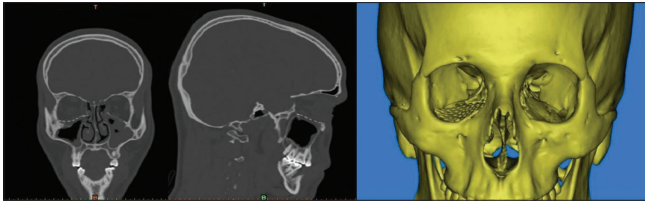
**Figure 8:** The algorithm of virtual planning: (a) Importing of computed tomography scan data to Materialise Mimics 17.0 software and cropping of the region of interest; (b) acquiring of perimeter and reference lines; (c) fabrication of virtual template based on this lines; (d) assessment of positioning of virtual template related to facial skeleton in three-dimensional; (e) assessment of positioning of virtual template related to facial skeleton in two-dimensional; (f) measurement of longitudinal and transversal dimensions of template with taking into account its curvature



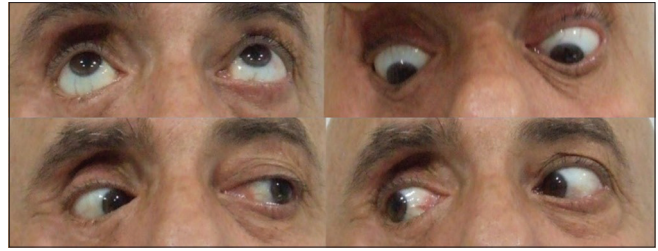**Figure 9:** Eyeball movements a month after surgery

zygomatic complex and naso-orbital-ethmoid fractures.<sup>[2,3]</sup> The gold standard in the treatment of orbital walls fractures includes restoration of anatomical volume and shape of the orbital cavity with simultaneous resuspension of prolapsed orbital content and liberation of entrapped orbital musculature. This prevents posttraumatic enophthalmos, eye motility restriction, and consequent diplopia.<sup>[10,11]</sup> Surgical approaches to orbital walls typically include transcutaneous, transconjunctival, and endoscopic approaches.<sup>[12]</sup>

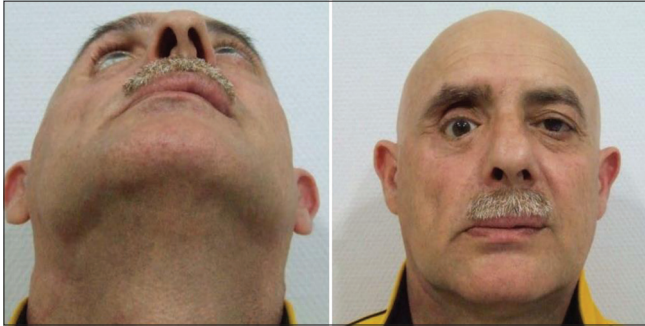
Generally, the aim of orbital reconstruction is to restore orbital volume and support orbital content by means of different implants. These implants usually include bone, cartilage, titanium, and resorbable mesh.<sup>[9]</sup> The surgical outcomes depend on two basic factors: (1) identity of the shape of orbital implant to anatomy of orbit that should be reconstructed and (2) accuracy of positioning of orbital implant related to adjacent anatomical structures. First factor can be achieved by implementation of different technologies, such as preformed orbital plates (MatrixORBITAL™ MatrixMIDFACE, DePuySynthes), rapid prototyping (RP) and fabrication of patient-specific plastic models of the skull, and customized



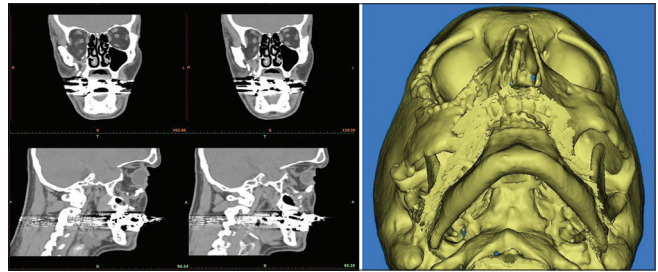
**Figure 10:** Position of orbital implant in two- and three-dimensional views



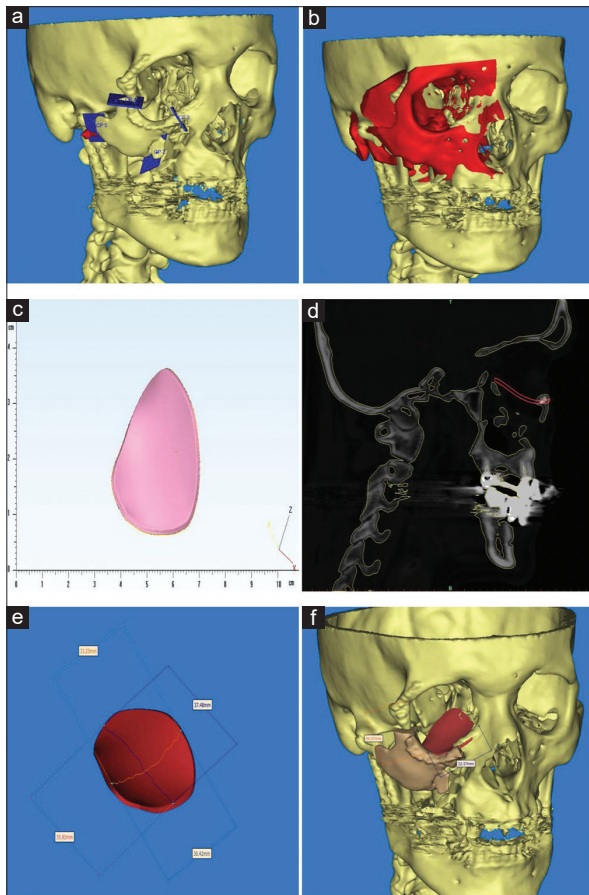
**Figure 11:** Clinical evaluation of the patient: Limitation of the movements of the right eyeball in upper and lateral quadrant



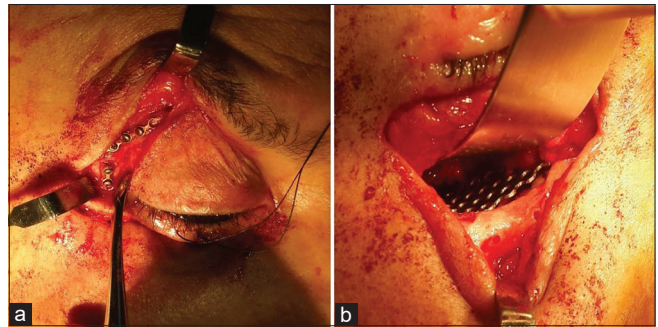
**Figure 12:** Clinical evaluation of the patient: Significant deformity of right zygoma-orbital complex and significant R-side enophthalmos



**Figure 13:** Computed tomography scan of the patient: Inferior orbital wall fracture and protrusion of orbital components toward defect; dislocation of the right malar bone



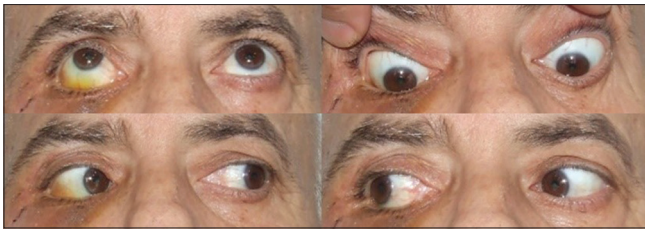
**Figure 14:** The algorithm of virtual planning: (a) virtual osteotomy of right malar bone; (b) mirroring of opposite site; (c) virtual fabrication of orbital implant; (d) positioning of virtual implant; (e) measurement of longitudinal and transversal dimensions of template with taking into account its curvature; (f) virtual repositioning of osteotomized malar bone and registration of anatomical landmarks



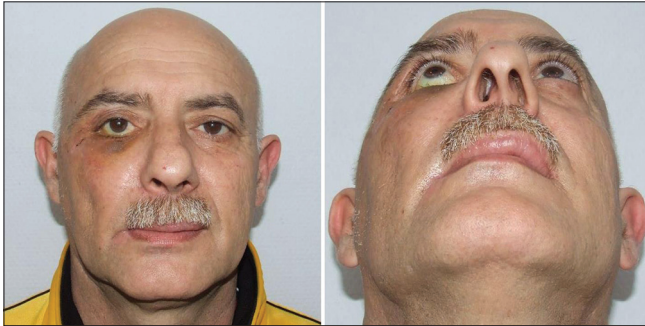
**Figure 15:** Surgical reconstruction: (a) detection and removal of old hardware; (b) installation of orbital implant

orbital implant fabrication as well.<sup>[13-18]</sup> However, these methods have some technical limitations. Thus, application of standard prebent orbital plates could be associated with some degree of inaccuracy; implementation RP technology is time-consuming but important in cases of acute trauma; and usage of patient-specific implants usually is costly and requires time for fabrication. As opposed to listed technologies, suggested virtual computer simulation and virtual bending of orbital plates require less time and could be used for prebending of standard implants. Thus, the usage of standard orbital plates in Group B lead led to residual diplopia in 12 cases (34.3%) as compared to 4 cases (9.5%) in Group A. On the other hand, time that is required for RP model fabrication and implant adaptation on the average is 3 days as compared to few hours that is required for virtual simulation and virtual implant bending.

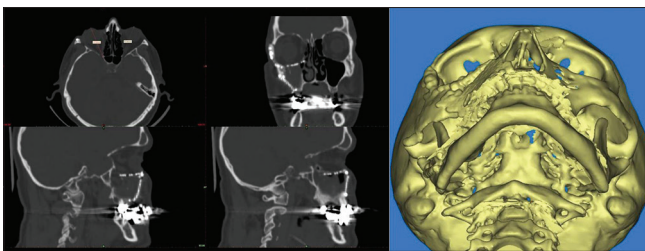
Accuracy of implant positioning could be achieved by implementation of intraoperative navigation systems. Nevertheless, usage of intraoperative navigation could be



**Figure 16:** Eyeball movements after surgical reconstruction



**Figure 17:** Facial appearance after surgical reconstruction



**Figure 18:** Postoperative computed tomography scan: Adequate position of malar bone and orbital implant

associated with technical difficulties; the surgeon should switch his attention from operating field to 2D monitor of navigation system.<sup>[19]</sup> Moreover, navigation systems are costly and thus could be equipped in relatively limited clinics. Suggested virtual measurements of anatomical landmarks of the orbit and relation of the plate to these landmarks could be reasonable alternative to such navigation systems. Moreover, this approach could reduce time of procedure. Thus, operation time for the patients with isolated orbital walls fracture in Group A was 1.98 h while the same parameter in Group B was 2.05 that is relatively more.

## CONCLUSIONS

Application of virtual planning could significantly improve postoperative outcomes in orbital reconstruction. However, application of this technology could be limited by complicated defects of the orbital walls, which requires complex shape of the implant, which might be difficult to prevent virtually.

## Declaration of patient consent

The authors certify that they have obtained all appropriate patient consent forms. In the form the patient(s) has/have given his/her/their consent for his/her/their images and other

clinical information to be reported in the journal. The patients understand that their names and initials will not be published and due efforts will be made to conceal their identity, but anonymity cannot be guaranteed.

## Financial support and sponsorship

Nil.

## Conflicts of interest

There are no conflicts of interest.

## REFERENCES

- Grob S, Yonkers M, Tao J. Orbital fracture repair. *Semin Plast Surg* 2017;31:31-9.
- Nakamura T, Gross CW. Facial fractures. Analysis of five years of experience. *Arch Otolaryngol* 1973;97:288-90.
- Gwyn PP, Carraway JH, Horton CE, Adamson JE, Mladick RA. Facial fractures-associated injuries and complications. *Plast Reconstr Surg* 1971;47:225-30.
- Park SW, Choi JW, Koh KS, Oh TS. Mirror-imaged rapid prototype skull model and pre-molded synthetic scaffold to achieve optimal orbital cavity reconstruction. *J Oral Maxillofac Surg* 2015;73:1540-53.
- Kozakiewicz M, Elgalal M, Loba P, Komuński P, Arkuszewski P, Broniarczyk-Loba A, et al. Clinical application of 3D pre-bent titanium implants for orbital floor fractures. *J Craniomaxillofac Surg* 2009;37:229-34.
- Gür Y. Additive manufacturing of anatomical models from computed tomography scan data. *Mol Cell Biomech* 2014;11:249-58.
- Choi JW, Kim N. Clinical application of three-dimensional printing technology in craniofacial plastic surgery. *Arch Plast Surg* 2015;42:267-77.
- Gart MS, Gosain AK. Evidence-based medicine: Orbital floor fractures. *Plast Reconstr Surg* 2014;134:1345-55.
- Cha JH, Lee YH, Ruy WC, Roe Y, Moon MH, Jung SG. Application of rapid prototyping technique and intraoperative navigation system for the repair and reconstruction of orbital wall fractures. *Arch Craniofac Surg* 2016;17:146-53.
- He Y, Zhang Y, An JG. Correlation of types of orbital fracture and occurrence of enophthalmos. *J Craniofac Surg* 2012;23:1050-3.
- Kim YK, Park CS, Kim HK, Lew DH, Tark KC. Correlation between changes of medial rectus muscle section and enophthalmos in patients with medial orbital wall fracture. *J Plast Reconstr Aesthet Surg* 2009;62:1379-83.
- Shen YD, Paskowitz D, Merbs SL, Grant MP. Retrocaruncular approach for the repair of medial orbital wall fractures: an anatomical and clinical study. *Craniomaxillofac Trauma Reconstr* 2015;8:100-4.
- Bittermann G, Metzger MC, Schlager S, Lagrèze WA, Gross N, Cornelius CP, et al. Orbital reconstruction: Prefabricated implants, data transfer, and revision surgery. *Facial Plast Surg* 2014;30:554-60.
- Hoffmann J, Cornelius CP, Groten M, Pröbster L, Pfannenbergs C, Schwenzer N. Orbital reconstruction with individually copy-milled ceramic implants. *Plast Reconstr Surg* 1998;101:604-12.
- Schipper J, Ridder GJ, Spetzger U, Teszler CB, Fradis M, Maier W. Individual prefabricated titanium implants and titanium mesh in skull base reconstructive surgery. A report of cases. *Eur Arch Otorhinolaryngol* 2004;261:282-90.
- Hoffmann J, Cornelius CP, Groten M, Pröbster L, Schwenzer N. Using individually designed ceramic implants for secondary reconstruction of the bony orbit. *Mund Kiefer Gesichtschir* 1998;2 Suppl 1:S98-101.
- Holck DE, Boyd EM Jr, Ng J, Mauffray RO. Benefits of stereolithography in orbital reconstruction. *Ophthalmology* 1999;106:1214-8.
- Metzger MC, Schön R, Zizelmann C, Weyer N, Gutwald R, Schmelzeisen R. Semiautomatic procedure for individual preforming of titanium meshes for orbital fractures. *Plast Reconstr Surg* 2007;119:969-76.
- Lee KM, Park JU, Kwon ST, Kim SW, Jeong EC. Three-dimensional pre-bent titanium implant for concomitant orbital floor and medial wall fractures in an East Asian population. *Arch Plast Surg* 2014;41:480-5.