















Renomedullary Interstitial Cell Tumor Mimicking Renal Cell Carcinoma: A Case Report

신세포암으로 오인한 신수질 간질세포 종양: 증례 보고

Hyunji Oh, MD¹ , Sung Bin Park, MD^{1*} , Tae-Jin Lee, MD² ,
Byung Hoon Chi, MD³ , Hyun Jeong Park, MD¹ , Eun Sun Lee, MD¹ 

Departments of ¹Radiology, ²Pathology, and ³Urology, Chung-Ang University Hospital, Chung-Ang University College of Medicine, Seoul, Korea

ORCID iDs

Hyunji Oh  <https://orcid.org/0000-0001-6894-5236>
Sung Bin Park  <https://orcid.org/0000-0002-4155-9260>
Tae-Jin Lee  <https://orcid.org/0000-0002-0026-5936>
Byung Hoon Chi  <https://orcid.org/0000-0002-4184-7780>
Hyun Jeong Park  <https://orcid.org/0000-0003-1701-0478>
Eun Sun Lee  <https://orcid.org/0000-0003-0780-7985>

Received April 5, 2022
Revised June 4, 2022
Accepted July 8, 2022

*Corresponding author

Sung Bin Park, MD
Department of Radiology,
Chung-Ang University Hospital,
Chung-Ang University
College of Medicine,
102 Heukseok-ro, Dongjak-gu,
Seoul 06973, Korea.

Tel 82-2-6299-3196
Fax 82-2-6263-1557
E-mail pksungbin@paran.com

This is an Open Access article distributed under the terms of the Creative Commons Attribution Non-Commercial License (<https://creativecommons.org/licenses/by-nc/4.0>) which permits unrestricted non-commercial use, distribution, and reproduction in any medium, provided the original work is properly cited.

Renomedullary interstitial cell tumors are often incidentally identified either upon autopsy or kidney resection for other reasons. However, rare renomedullary interstitial cell tumor cases resulting in a clinical symptomatic mass have been reported. We present a case of renomedullary interstitial cell tumor that was manifested as an incidentally detected renal mass and mimicked renal cell carcinoma on the imaging features.

Index terms Kidney; Kidney Neoplasms; Multidetector Computed Tomography; Magnetic Resonance Imaging

INTRODUCTION

Renomedullary interstitial cell tumors (RMICTs) are almost always incidentally identified either at autopsy or upon resection of the kidney for other renal lesions or diseases (1-4). Consequently, the radiologic findings of RMICT have rarely been described (1-3, 5, 6) because of the lack of microscopic confirmation. With the widespread use of imaging modalities, there are more opportunities to find RMICT incidentally, like other benign tumors (1). Hence, we believe that in many cases RMICT may need to be distinguished from other renal malignancies, such as renal cell or transitional cell carcinoma.

In this report, we present the imaging and microscopic features of a case of RMICT mimicking renal cell carcinoma (RCC) on imaging features.

CASE REPORT

A healthy 66-year-old male was referred to our hospital because of a gallbladder mass on abdominal US examination for routine health check-up, and benign lymphoplasmacytic cholecystitis was later microscopically confirmed. The patient had no symptoms, including hematuria or flank pain. He had no specific family or medical history. The patient had normal blood pressure. The results of laboratory tests, including a complete blood count, urine analysis, measurement of electrolyte levels, and liver function tests, were all within normal range.

He underwent dynamic contrast-enhanced abdominopelvic CT using a 64-channel scanner (Brilliance 64; Philips Medical Systems, Cleveland, OH, USA) for further evaluation of the gallbladder mass. However, a 2.7 cm heterogeneously progressive enhancing mass was observed at the interpolar area of the right kidney (Fig. 1A) along with the gallbladder mass. The mean density of the region of interest was 32 Hounsfield unit (HU) in precontrast, 48 HU in the arterial, and 78 HU in the portal phase, respectively. There was no evidence of renal vein or venacaval extension and no obvious lymphadenopathy.

Subsequently, gadolinium-enhanced MRI using a 3T scanner (Skyra; Siemens Medical Solutions, Erlangen, Germany) was performed. The mass showed isointensity on T1-weighted image (T1WI) and slight hyperintensity on T2-weighted image (T2WI) compared with the renal cortex. On diffusion-weighted imaging, there was no definite diffusion restriction. On dynamic contrast-enhanced images, the mass showed heterogeneously progressive enhancement (Fig. 1B). In addition, there was no microscopic fat content on the chemical shift in- and out-of-phased images.

Based on the clinical and imaging features, the primary diagnosis was clear cell RCC. Therefore, the patient underwent radical nephrectomy of the right kidney.

The gross specimen revealed that the tumor was well-circumscribed, unencapsulated, and endophytic with a homogeneous gray-white cut surface in the renal medulla (Fig. 1C). The tumor measured 2.2 cm × 2.2 cm × 2.0 cm. Microscopically, the tumor was well-circumscribed, and tumor cells were small, stellate, or spindle cells embedded in a basophilic stroma. At the periphery, some distorted renal medullary tubules were entrapped in the matrix. The tumor nuclei had open chromatin and showed minimal atypia or hyperchromasia (Fig. 1D). Mitotic activity was rare and absent. The final microscopic diagnosis was RMICT.

The patient tolerated the procedure well and had an unremarkable postoperative recovery course. At the time of writing, 24 months after surgery, there have been no signs of recurrence or symptoms.

The study protocol conformed to the ethical guidelines of the 1975 Declaration of Helsinki. Informed consent was obtained from the patient.

DISCUSSION

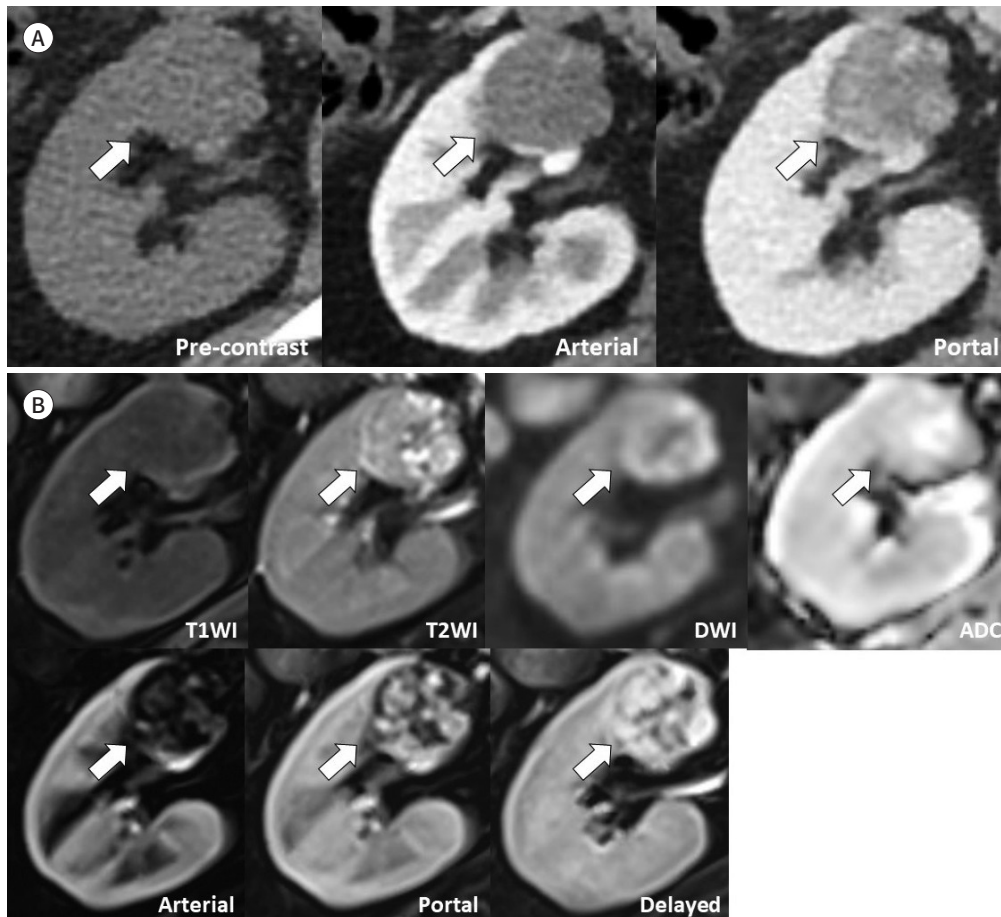
RMICT, formerly known as medullary fibroma, is a benign mesenchymal tumor of the kidney that arises from interstitial cells of the medulla exerting an antihypertensive action but is not associated with blood pressure abnormalities (4). Ultrastructural studies revealed that

Fig. 1. Renomedullary interstitial cell tumor in a 66-year-old male.

A. CT images show a well-defined renal medullary mass (arrows) with progressive heterogeneous enhancement in the right kidney interpolar region. Mean density of the mass is 32 HU, 48 HU, and 78 HU in precontrast, arterial, and portal phase, respectively.

B. MR images show an isointense tumor (arrow) and slightly hyperintense tumor (arrow) on T1WI and T2WI, respectively. There is no definite diffusion restriction (arrow) on the high b-value (1000 s/mm²) image and ADC map. The tumor (arrow) shows heterogeneous and progressive enhancement on the gadolinium-enhanced images (arterial phase image at 30 seconds, portal phase image at 70 seconds, and delayed phase image at 3 minutes).

ADC = apparent diffusion coefficient, DWI = diffusion-weighted image, HU = Hounsfield unit, T1WI = T1-weighted image, T2WI = T2-weighted image



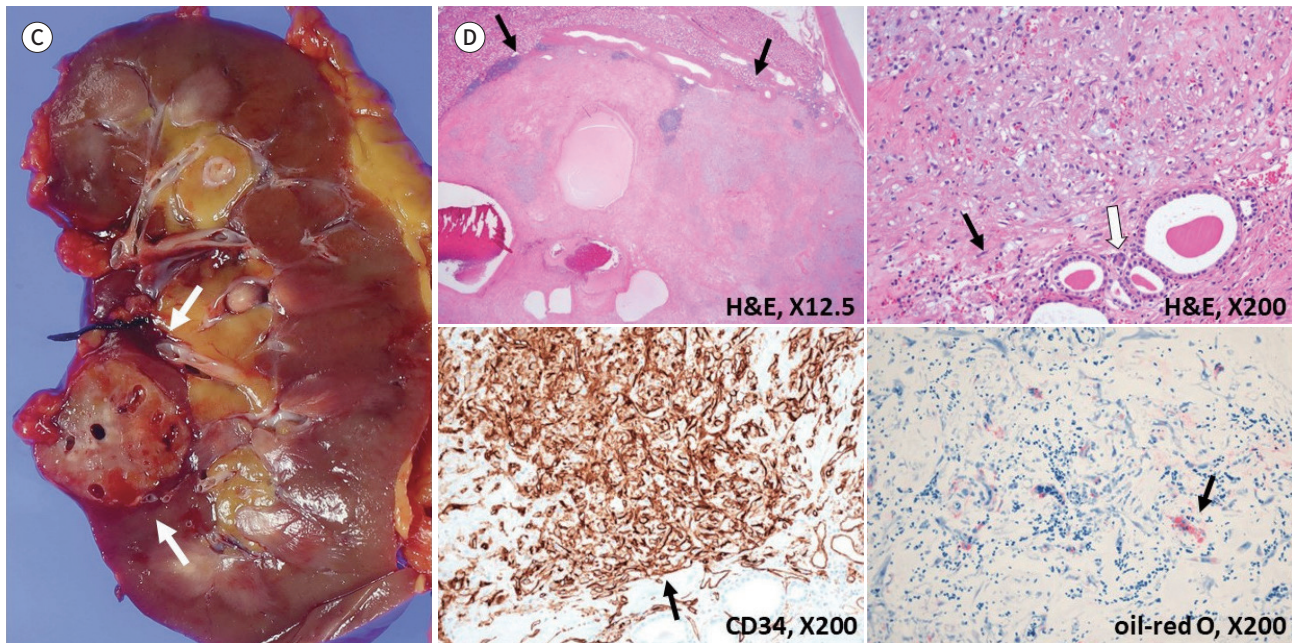
the spindle cells throughout the stroma have the features of medullary interstitial cells and lack features of fibroblasts (2, 4). RMICT is commonly detected as an incidental finding and has been reported in up to 50% of autopsy cases (1, 2, 4, 6). The tumor is usually solitary, but sometimes there may be multiple tumors or the tumor may be bilateral. The incidence of the tumor increases with age. Patients are usually asymptomatic, but it can cause symptoms such as flank pain or hematuria (7) and become clinically evident with an increase in size (3). Most of the tumor reported were small and measured less than 0.5 cm in diameter (3, 6); thus, it could be clinically overlooked and difficult to detect radiologically. As the lesion size increased, it could be radiologically detected, as in the present case, and should be differentiated from other renal malignancies to plan surgery. In other words, the RMICT rarely causes

Fig. 1. Renomedullary interstitial cell tumor in a 66-year-old male.

C. Gross specimen demonstrates a well circumscribed, homogeneous, gray-white nodular mass (arrows) detected in the renal medulla.

D. Histopathologic features show a well circumscribed tumor (upper left black arrows). The tumor cells are composed of small stellate and spindle renomedullary interstitial cells (black arrow) in the basophilic stroma background. Peripherally, some distorted renal medullary tubules (white arrow) are entrapped in the matrix (upper right). The tumor is strongly positive for CD34 (lower left arrow) and oil-red O staining (lower right arrow).

H&E = hematoxylin and eosin



clinical symptoms or masses that require surgical excision. However, this remains challenging because of its nonspecific radiologic findings.

In the previous report study, RMICT on CT may appear as a nonenhancing and hypoattenuating solid lesion of the renal medulla, as seen in soft-tissue tumors (3, 5, 6). The calcification is rare (3, 6). However, in the present case, the tumor heterogeneously enhanced and mimicked RCC. Furthermore, the tumor was endophytic, mainly located at the renal medulla, and extended into the renal pelvis when the size of the tumor increased (6). Thus, we would expect to differentiate RMICT from other solid lesions including malignancy with location, because RMICT originated from the interstitial cells of the medulla.

MRI may be helpful in differentiating benign lesions from other malignancies. RMICT is hypointense on both T1WI and T2WI because it is collagen rich with decreased cellularity (5). However, the MRI findings in the present case were different from those previously noted. The tumor was well-circumscribed and showed isointensity on T1WI and slight hyperintensity on T2WI with progressively heterogeneous enhancement. The MRI findings of clear cell RCC are similar: isointense on T1WI and usually hyperintense on T2WI, but heterogeneous signal intensity can be present with necrosis and hemorrhage (8, 9). As in the present case, clear cell RCC shows heterogeneous enhancement because clear cell RCC is a hypervascular tumor (10).

Our case is interesting for two reasons. First, the imaging findings of our case are somewhat different from those of previously reported cases. Since our case was misdiagnosed as the malignancy, we would like to emphasize to consider the RMICT as one of the differential

diagnoses. Second, to the best of our knowledge, there have been only a few case reports of RMICT characterized by both CT and MRI because of the difficulty in radiological detection and lack of microscopic confirmation. Only a few studies have reported the MRI findings of RMICT (5), and none of the previous studies depicted the MRI features using sequences with dynamic contrast enhancement and diffusion-weighted imaging.

In conclusion, we have reported a case of RMICT with particular focus on imaging features. To the best of our knowledge, the differential diagnosis of RMICT remains challenging. Thus, radiologists should carefully review the imaging data regarding the renal mass and need to be aware of and differentiate this entity from other renal lesions. We suggest that RMICT be included in the differential diagnosis of a well-defined solid mass in the renal medulla.

Author Contributions

Conceptualization, P.S.B.; project administration, P.S.B.; validation, P.S.B.; writing—original draft, P.S.B., O.H.; and writing—review & editing, all authors.

Conflicts of Interest

The authors have no potential conflicts of interest to disclose.

Funding

None

Acknowledgments

We would like to thank Editage (www.editage.co.kr) for English language editing.

REFERENCES

1. Bazzi WM, Huang H, Al-Ahmadie H, Russo P. Clinicopathologic features of renomedullary interstitial cell tumor presenting as the main solid renal mass. *Urology* 2014;83:1104-1106
2. Bircan S, Orhan D, Tulunay O, Safak M. Renomedullary interstitial cell tumor. *Urol Int* 2000;65:163-166
3. Kumar S, Choudhary GR, Nanjappa B, Bal A. Benign medullary fibroma of the kidney: a rare diagnostic dilemma. *J Clin Imaging Sci* 2013;3:43
4. Lerman RJ, Pitcock JA, Stephenson P, Muirhead EE. Renomedullary interstitial cell tumor (formerly fibroma of renal medulla). *Hum Pathol* 1972;3:559-568
5. Katabathina VS, Vikram R, Nagar AM, Tamboli P, Menias CO, Prasad SR. Mesenchymal neoplasms of the kidney in adults: imaging spectrum with radiologic-pathologic correlation. *Radiographics* 2010;30:1525-1540
6. Prasad SR, Surabhi VR, Menias CO, Raut AA, Chintapalli KN. Benign renal neoplasms in adults: cross-sectional imaging findings. *AJR Am J Roentgenol* 2008;190:158-164
7. Glover SD, Buck AC. Renal medullary fibroma: a case report. *J Urol* 1982;127:758-760
8. Oliva MR, Glickman JN, Zou KH, Teo SY, Mortel  KJ, Rocha MS, et al. Renal cell carcinoma: T1 and T2 signal intensity characteristics of papillary and clear cell types correlated with pathology. *AJR Am J Roentgenol* 2009;192:1524-1530
9. Prasad SR, Humphrey PA, Catena JR, Narra VR, Srigley JR, Cortez AD, et al. Common and uncommon histologic subtypes of renal cell carcinoma: imaging spectrum with pathologic correlation. *Radiographics* 2006;26:1795-1806
10. Sun MR, Ngo L, Genega EM, Atkins MB, Finn ME, Rofsky NM, et al. Renal cell carcinoma: dynamic contrast-enhanced MR imaging for differentiation of tumor subtypes--correlation with pathologic findings. *Radiology* 2009;250:793-802

신세포암으로 오인한 신수질 간질세포 종양: 증례 보고

오현지¹ · 박성빈^{1*} · 이태진² · 지병훈³ · 박현정¹ · 이은선¹

신수질 간질세포 종양은 거의 대부분의 경우에서 부검 혹은 다른 원인에 의해 신장을 절제했을 때 우연히 발견된다. 하지만, 드물게 임상적인 증상을 보이는 신수질간질세포 종양의 경우도 보고되었다. 우연히 발견된 신장 종양으로 나타난 신수질 간질세포 종양이 영상 검사상 신세포종양을 모방하였던 증례를 보고한다.

중앙대학교 의과대학 중앙대학교병원 ¹영상의학과, ²병리과, ³비뇨의학과