


# Tofacitinib for Pityriasis Rubra Pilaris: A Case Report

Hongyan Tan, Bin Zhang, Xiawei Kang, Lv Yao Wang, Xiao Qiu , Xiangyu Hu

Department of Dermatology, Chongqing Hospital of Traditional Chinese Medicine, Chongqing, 400011, People's Republic of China

Correspondence: Xiangyu Hu, Email 369930758@qq.com

**Purpose:** At present, we have entered the era of using biological agents and small molecule targeted drugs to treat diseases. Although there have been many reports of biological agents treating pityriasis rubra pilaris recently, the clinical application of the JAK inhibitors in the treatment of pityriasis rubra pilaris has been rarely reported, and there is a lack of evidence on the safety and efficacy of these drugs. We explore the use of the JAK inhibitor tofacitinib in the treatment of pityriasis rubra pilaris with significant efficacy and no significant side effects, providing new ideas for the clinical treatment of pityriasis rubra pilaris.

**Methods:** We cover a case of pityriasis rubra pilaris treated with the JAK inhibitor tofacitinib, which showed significant efficacy without any adverse effects.

**Results:** This case report showed that the JAK inhibitor tofacitinib had significant clinical efficacy in the treatment of pityriasis rubra pilaris. We speculated that the treatment of pityriasis rubra pilaris with the JAK inhibitors may be related to blocking the activation of the JAK/STAT pathway, thereby blocking the high expression of cytokines IL-17, IL-12/IL-23, IL-23, TNF- $\alpha$ .

**Conclusion:** The JAK inhibitor tofacitinib can become a new option for treating pityriasis rubra pilaris.

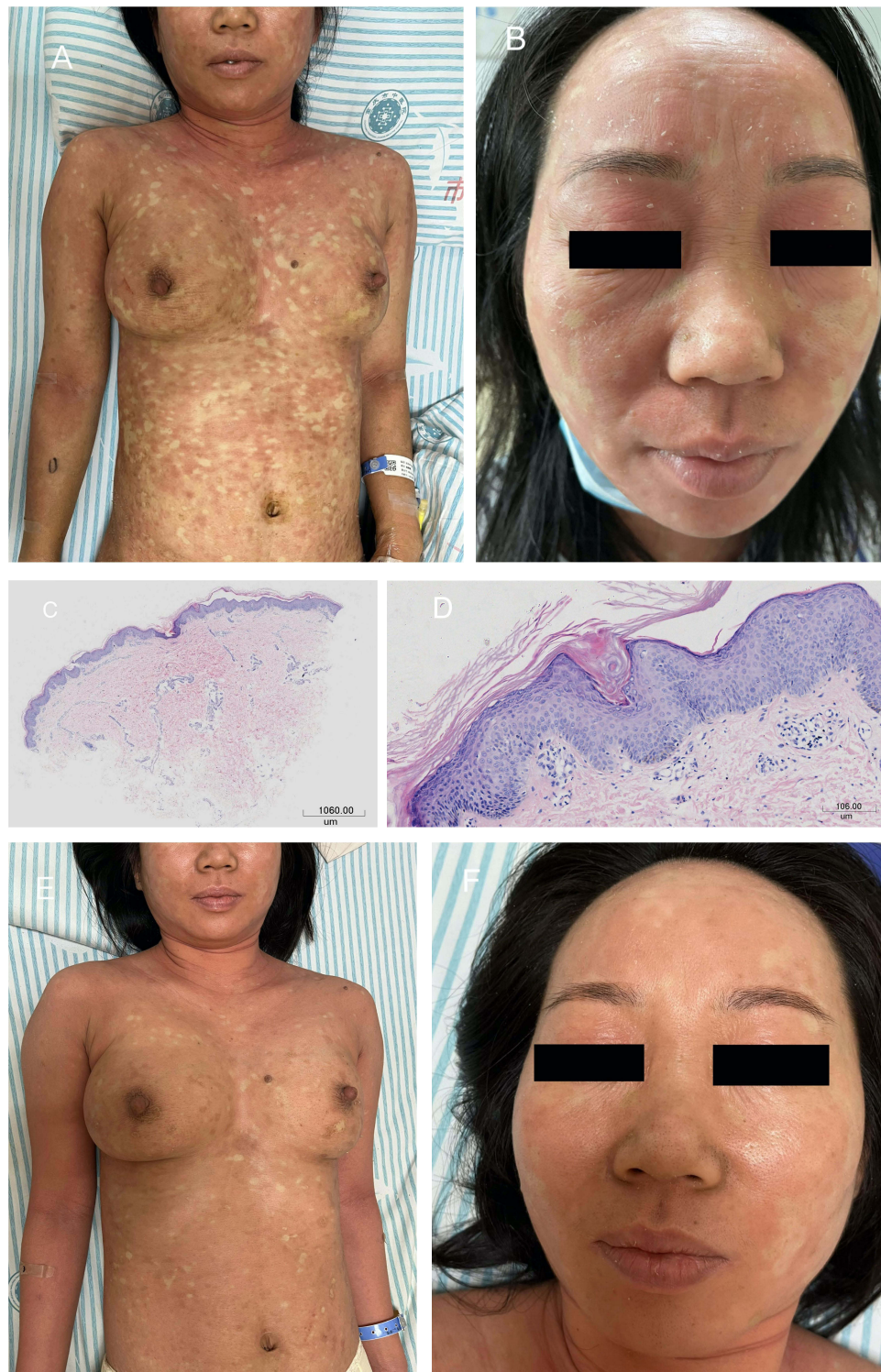**Keywords:** pityriasis rubra pilaris, JAK inhibitors, tofacitinib, secukinumab, ustekinumab

## Introduction

Pityriasis rubra pilaris (PRP) is a rare chronic inflammatory erythematous and squamous keratotic pruritic dermatosis characterised by erythematous desquamative and hyperkeratotic follicular papules of unknown aetiology.<sup>1,2</sup> There are no international guidelines for the treatment of this disease. It shares many similarities with psoriasis in terms of pathogenesis, histopathology, and clinical manifestations. Based on the currently reported clinical cases, treatment is also challenging and unsatisfactory.<sup>3</sup> Recently, Janus kinase (JAK) inhibitors upadacitinib and tofacitinib have been successfully used for the treatment of PRP.<sup>4,5</sup> Here, we report a case of PRP patient who did not respond well to conventional treatment but achieved significant efficacy through treatment with the JAK inhibitor tofacitinib.

## Case Presentation

A 39 years old female patient was admitted because of “recurrent systemic erythema, papules, and itching for more than 20 days” (Figure 1A and B). Her laboratory examinations were basically normal (Including hepatitis B, AIDS, syphilis, liver and kidney function, blood test, etc). Over the past more than 20 days, She was diagnosed with chronic urticaria and treated, but there was no improvement. After admission, we arranged skin pathological examination for the patient and confirmed the diagnosis as PRP. Skin pathological examination: Excessive keratinization accompanied by focal incomplete keratinization, alternating tessellated changes in some areas, thinning of the granular layer, hypertrophy of the stratum spinosum, elongation and widening of the epidermal prominence, and visible hair follicle angle tethers. The superficial dermal capillaries were markedly dilated with scattered or small perivascular lymphocytic infiltration. As shown in figure (Figure 1C and D). The patient was treated with topical corticosteroids (halometasone cream) and systemic therapies (acitretin and olopatadine). Nevertheless, itching and rash did not show significant improvement.



**Figure 1** (A) and (B) Changes in skin before tofacitinib treatment. (C) and (D). Skin histopathology images. (E) and (F). Image of skin lesions after 2 weeks of tofacitinib treatment.

According to some case reports, secukinumab and ustekinumab have shown significant efficacy in treating PRP.<sup>6-9</sup> We were prepared to administer secukinumab or ustekinumab monoclonal antibody to patients.

However, due to the high cost, the patient refused this medication. Recently, the JAK inhibitors have been approved for use in psoriasis and have shown significant therapeutic effects. Considering that PRP shares many similarities with

psoriasis in terms of pathogenesis, pathology, and clinical manifestations. Therefore, we attempted to treat patients with the JAK inhibitor tofacitinib. Therefore, we attempted to treat the patient with the JAK inhibitor tofacitinib at an oral dose of 5 mg bid. After one week, the rash significantly decreased and itching significantly improved, indicating effective treatment; The patient used tofacitinib for a total of 2 months, 5 mg bid for 1 month, and 5 mg qd for 1 month. Skin photos were taken before and 2 week after treatment with tofacitinib (Figure 1E and F). We closely observed the patient and observed good therapeutic effects with no adverse reactions during the 2-month period of tofacitinib administration. The patient was followed up for 2 months after discontinuation of medication and no recurrence was observed.

## Discussion

PRP is a rare and difficult to treat autoimmune disease, and the clinical use of traditional drugs has poor therapeutic effects. Research has shown that abnormal secretion of cytokines such as IL-17, IL-12/IL-23, IL-23, TNF- $\alpha$  are involved in the pathogenesis of PRP.<sup>10</sup> However, the inflammatory response mediated by these cytokines is mainly related to the activation of the JAK-STAT pathway.<sup>11</sup> The JAK signaling pathway and transcription activator STAT pathway are the most common intracellular signaling pathways, and their activation can affect cell proliferation and apoptosis. JAK is a highly active intracellular enzyme composed of JAK1, JAK2, JAK3, and TYK2, which mediates cytokine signaling on the cell membrane and causes inflammation. Tofacitinib is a non-selective JAK inhibitor that can directly inhibit the activation of the JAK-STAT pathway. We speculate that it can block the transcription of cytokines such as IL-17, IL-12/IL-23, IL-23, TNF  $\alpha$ , etc, thereby inhibiting the immune inflammatory response. Before using tofacitinib, we screened the patient's liver and kidney function, coagulation function, hepatitis B, and pulmonary tuberculosis, and did not find any significant abnormalities. After 2 months of medication treatment, there were no side effects such as herpes zoster, upper respiratory tract infection, or thrombosis. We believe that tofacitinib can become a new option for treating PRP. At the same time. The case report of PRP treated with tofacitinib achieved good therapeutic effects after failure to use acitretin and ixekizumab.<sup>5</sup>

## Conclusion

Therefore, the JAK inhibitor tofacitinib is a promising option for treating PRP. In future, larger sample sizes and clinical studies are required to provide more evidence.

## Ethics Statement

Obtain the patient's signed consent in order to publish detailed case information and accompanying images. The disclosure of case details did not require institutional approval.

## Consent Statement

Written informed consent was provided by the patient for publishing images and information.

## Disclosure

Xiangyu Hu is the corresponding author of this study. The authors report no conflicts of interest in this work.

## References

1. Yaldo MM, Olds H, Hengy M, et al. Delayed Presentation of Pityriasis Rubra Pilaris in a Patient on Treatment With Ponatinib. *Cureus*. 2024;16(1):e52155. doi:10.7759/cureus.52155
2. Camela E, Miano C, Di Caterino P, et al. Erythrodermic pityriasis rubra pilaris treatment: two case reports and literature review. *Dermatol Ther*. 2020;33(6):e14223. doi:10.1111/dth.14223
3. DeBiasio C, Cyr J, Ayroud Y, et al. A case of classic adult pityriasis rubra pilaris successfully treated with a combination of Acitretin and ustekinumab: a case report. *SAGE Open Med Case Rep*. 2022;10:2050313X221093453. doi:10.1177/2050313X221093453
4. Saad M, Spurr A, Lipson J. Pityriasis rubra pilaris partially responsive to treatment with upadacitinib: a case report. *SAGE Open Med Case Rep*. 2023;11:2050313X231160927. doi:10.1177/2050313X231160927
5. Ying Y, Yu-Hua L, Xiao-Yan W, et al. A case of pityriasis rubra pilaris treated with tofacitinib after failure with Acitretin and ixekizumab. *Australas J Dermatol*. 2023;64(3):445–447. doi:10.1111/ajd.14076

6. Xu YH, Dong DD, Lin YF, et al. Successful treatment of severe pityriasis rubra pilaris with secukinumab in a 3-year-old boy. *Clin Exp Dermatol*. 2022;47(11):2043–2045. doi:10.1111/ced.15353
7. Albela H, Lee WQ, Nordin SN, et al. Juvenile Pityriasis Rubra Pilaris in a 4-year-old Child Treated Successfully with Secukinumab. *Indian J Dermatol*. 2022;67(5):601–603. doi:10.4103/ijd.ijd\_1079\_21
8. Boudreaux BW, Pincelli TP, Bhullar PK, et al. Secukinumab for the treatment of adult-onset pityriasis rubra pilaris: a single-arm clinical trial with transcriptomic analysis. *Br J Dermatol*. 2022;187(5):650–658. doi:10.1111/bjd.21708
9. Katharina M, Sylvia S, Matthias B, et al. Successful treatment of a child's pityriasis rubra pilaris (PRP) with ustekinumab and Acitretin. *Pediatr Dermatol*. 2022;39(4):659–661. doi:10.1111/pde.14994
10. Napolitano M, Abeni D, Didona B. Biologics for pityriasis rubra pilaris treatment: a review of the literature. *J Am Acad Dermatol*. 2018;79(2):353–359. doi:10.1016/j.jaad.2018.03.036
11. Loo WJ, Turchin I, Prajapati VH, et al. Clinical Implications of Targeting the JAK-STAT Pathway in Psoriatic Disease: emphasis on the TYK2 Pathway. *J Cutan Med Surg*. 2023;27(1\_suppl):3S–24S. doi:10.1177/12034754221141680

Clinical, Cosmetic and Investigational Dermatology

Dovepress

**Publish your work in this journal**

Clinical, Cosmetic and Investigational Dermatology is an international, peer-reviewed, open access, online journal that focuses on the latest clinical and experimental research in all aspects of skin disease and cosmetic interventions. This journal is indexed on CAS. The manuscript management system is completely online and includes a very quick and fair peer-review system, which is all easy to use. Visit <http://www.dovepress.com/testimonials.php> to read real quotes from published authors.

Submit your manuscript here: <https://www.dovepress.com/clinical-cosmetic-and-investigational-dermatology-journal>