

Delayed Presentation of Endovenous Heat-Induced Thrombosis Treated by Thrombolysis and Subsequent Open Thrombectomy

Jung Hak Kwak, Sang Il Min, Song-Yi Kim, Ahram Han, Chanjoong Choi, Sanghyun Ahn, Jongwon Ha, and Seung-Keo Min

Department of Surgery, Seoul National University College of Medicine, Seoul, Korea

Although endovenous heat-induced thrombosis (EHIT) is frequently reported after endovenous laser ablation (EVLA), the incidence and timing of occurrence of EHIT are not fully understood. We present a case of EHIT successfully treated with a combination of surgical and endovascular treatments. A 57-year-old woman, two months post bilateral EVLA, presented with a swollen leg. Deep vein thrombosis was diagnosed by Doppler ultrasonography and computerized tomographic venography. We treated the patient with catheter-directed thrombolysis with urokinase after insertion of an inferior vena cava filter. After thrombolytic treatment, we performed surgical venous thrombectomy, due to the presence of a large thrombus in the femoral vein. During the operation, we found organized old thrombus at the great saphenous vein which connected to the deep femoral vein. From these findings, we confirmed the presence of EHIT despite a long time having passed after EVLA. The patient was placed on anticoagulation therapy with oral rivaroxaban for three months.

Key Words: Venous thrombosis, Laser therapy, Catheter ablation

Received February 17, 2016

Revised March 4, 2016

Accepted March 16, 2016

Corresponding author: Sang Il Min

Division of Vascular Surgery, Department of Surgery, Seoul National University Hospital, 101 Daehak-ro, Jongno-gu, Seoul 03080, Korea

Tel: 82-2-2072-2330

Fax: 82-2-766-3975

E-mail: surgeonmsi@gmail.com

Conflict of interest: None.

Copyright © 2016, The Korean Society for Vascular Surgery

This is an Open Access article distributed under the terms of the Creative Commons Attribution Non-Commercial License (<http://creativecommons.org/licenses/by-nc/4.0>) which permits unrestricted non-commercial use, distribution, and reproduction in any medium, provided the original work is properly cited.

Vasc Spec Int 2016;32(2):72-76 • <http://dx.doi.org/10.5758/vsi.2016.32.2.72>

INTRODUCTION

Superficial venous insufficiency (SVI) of the lower extremity is a common venous disease that occurs in approximately 25% of women and 15% of men [1]. There are several treatment options, including: traditional surgical stripping, sclerotherapy, and endovenous therapy for patients with SVI. Currently, endovenous therapy such as endovenous laser ablation (EVLA) or radiofrequency ablation (RFA) is the treatment of choice for SVI, because it has a faster recovery time, a lower complication rate compared to conventional surgical techniques, and provides improved quality of life of the patient—while it has similar closure rates compared to surgical stripping

[2]. However, EVLA has complications—such as deep vein thrombosis (DVT), pulmonary thromboembolism (PTE), skin burn, thrombophlebitis, and paresthesias. Endovenous heat-induced thrombosis (EHIT) is one of the complications of EVLA, that is, thrombosis of the deep venous system after EVLA [3]. Because their etiology and natural history differ from that of DVT, these thrombi are classified separately [4]. The incidence, risk factors, effectiveness of perioperative Doppler ultrasonography, and treatment related to EHIT are not well established. Here we describe a 57-year-old woman diagnosed with EHIT and successfully treated with a combination of surgical and endovascular interventions.

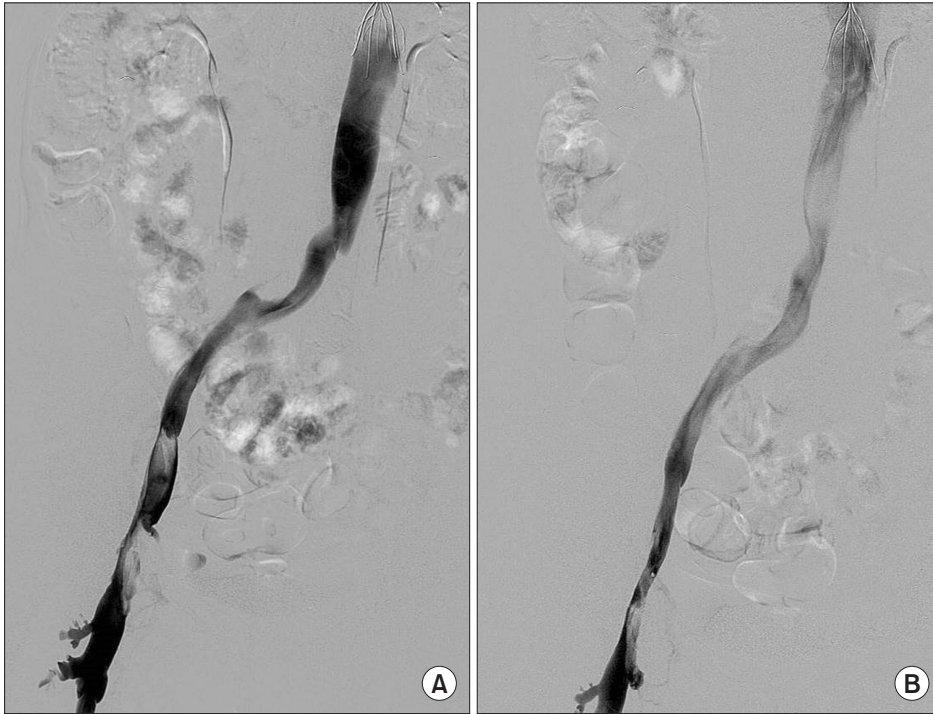


Fig. 1. (A) Initial venography shows femoral and iliac vein filling defect caused by thrombotic occlusion. (B) Follow up venography after aspiration thrombectomy and catheter-directed thrombolysis.

CASE

A 57-year-old woman presented to the emergency department because of progressively worsening pain and edema in her left leg that began over one day ago. There was no family history of thrombophilia and she had no other significant medical history, but received bilateral EVLA for treatment of varicose veins two months ago at other hospital.

On physical examination, her left leg circumferences were significantly increased compared with her right leg circumferences (left thigh 44 cm and left calf 35 cm vs. right thigh 41 cm and right calf 32 cm). Despite this finding, her motor function, sensory function, and pulses were all normal. Laboratory findings related to hypercoagulability were almost within normal range, except for elevated D-dimer (4.15 $\mu\text{g}/\text{mL}$). Computerized tomographic (CT) venography images indicated DVT from the left common iliac vein to the left deep femoral vein.

We performed inferior vena cava (IVC) filter insertion through a right internal jugular vein approach to prevent pulmonary embolism, and proceeded with angiography (Fig. 1A) and aspiration thrombectomy followed by catheter-directed thrombolysis for 12 hours with urokinase 80,000 IU/hr and heparin 500 IU/hr through a left popliteal vein access. After the first session of thrombolysis, we found improved blood flow, but still noted filling defects and flow disturbances that indicated a remaining chronic thrombus (Fig. 1B). Thus, we continued an additional seven

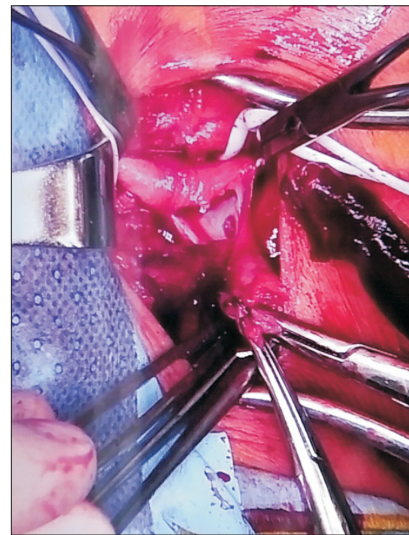


Fig. 2. Surgical findings. Open thrombectomy of the left sapheno-femoral junction was performed. The image shows a thrombus (that nearly obliterated the vein) removed via a small longitudinal venotomy. The thrombus extended from the great saphenous vein which was obliterated by the previous endovenous laser ablation.

hours of thrombolytic therapy, but there was no significant improvement.

Because the remaining thrombus was located at the left sapheno-femoral junction (SFJ), a location that is readily accessible, we performed a surgical thrombectomy of the left SFJ, removing the thrombus through a small

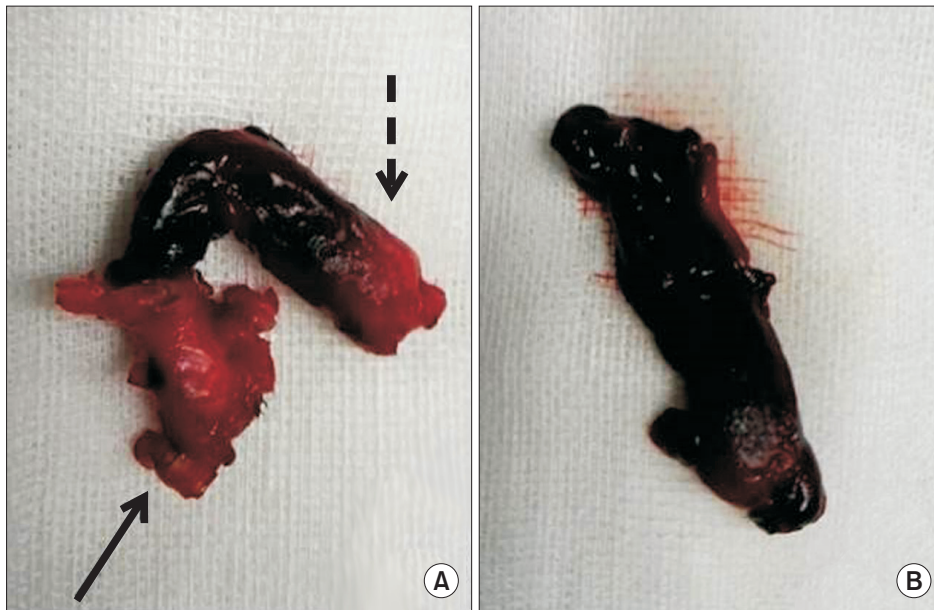


Fig. 3. The original thrombus was separated in two pieces after extraction. These appeared to be white and red in color and measured approximately (A) 2.0 cm and (B) 1.5 cm sized. (A) shows sapheno-femoral junction old thrombus originating from the great saphenous vein portion (straight arrow) and deep femoral vein portion (dotted arrow), (B) shows external iliac vein thrombus.

inguinal incision (Fig. 2). Inflammatory change was noted around the SFJ. After proximal and distal control, a 3 cm longitudinal venotomy was made over the SFJ. The thrombus nearly obliterated the lumen of the SFJ. During surgical thrombectomy, we found organized old thrombus which was located at the SFJ and extending to the deep femoral vein. From this finding, we concluded that the patient's DVT was originated from the previous EVLA and confirmed as EHIT.

The thrombus was extracted in two pieces during thrombectomy, and noted to be white and red in color and measuring approximately 2.0 cm and 1.5 cm (Fig. 3).

The greater saphenous vein (GSV) was ligated and resected. After surgical removal, the vein was primarily repaired with 6-0 polypropylene suture, and good blood flow was restored. The pathology report indicated a 4.0×0.6 cm vascular wall and thrombi with organization. Five days after surgery, a follow-up CT demonstrated well-maintained blood flow of the left common femoral vein (CFV). The patient's leg circumferences also decreased after treatment (left thigh: from 44 cm to 42 cm and left calf: from 35 cm to 33 cm). The patient was injected with subcutaneous low molecular weight heparin (LMWH) (Clexane; Sanofi SA, Gentilly, France) 1 mg/kg twice a day, for five days after surgery, and was switched to oral rivaroxaban (Xarelto; Bayer HealthCare AG, Leverkusen, Germany) 15 mg twice a day. She was discharged 10 days after surgery without any acute postoperative complications. The IVC filter was removed before discharge. Follow-up Doppler ultrasonography was performed five months later, and showed a small chronic DVT with wall-attached thrombus at the left CFV, but blood flow was still well maintained.

Therefore, we discontinued rivaroxaban and started daily 100 mg aspirin.

DISCUSSION

In the past, high ligation, stripping, or multiple phlebectomies had been the standard treatments for SVI [5]. But more recently, several studies reported that EVLA is less invasive and more cost-effective compared to conventional surgery, so EVLA is now considered the treatment of choice for SVI [5,6]. DVT after surgical treatment for lower extremity SVI has been rarely reported. EHIT is rare, but can happen after EVLA. The mechanism for EHIT is thrombus extension to the deep venous system after endovenous therapy, so most techniques recommend leaving at least the upper 2 cm of the SFJ, to prevent occlusion of the collaterals and to maintain intact blood vessel patency [7,8]. EHIT was introduced by Kabnick and Berland [3] in 2011 and defined as the extension of a thrombus to the deep venous system after EVLA therapy. The reported incidences of EHIT range from 0% to 16% [3,4]. However, the incidence of EHIT differs in each study. For the early detection of EHIT after EVLA or RFA, duplex ultrasonography is required in an appropriate time period after the procedure; however, there is no definite consensus in the literature regarding the timing of the study. Some articles recommend venous duplex ultrasonography within one week after the procedure [3,8] because there is the possibility that EHIT may develop after 24-72 hours [9].

In venous duplex ultrasonography, acute thrombus may appear as a hypoechoic lesion, But EHIT may demonstrate early echogenicity and regress into the GSV usually within

days. So when follow up ultrasonography is delayed, it is possible that the diagnosis of thrombus extension can be missed or delayed in asymptomatic patients [10].

However, in this case we presented, there was no immediate imaging study after EVLA. A notable finding was that it was difficult to diagnose EHIT in this patient initially, because she had DVT and her history of EVLA was long time ago (two months). Based on DVT treatment, thrombolysis and surgical thrombectomy was done. Through an operation, we found remaining old thrombus at the GSV that extended to the deep femoral vein. Finally we could diagnose this patient as EHIT.

Currently, many investigators have noted significant findings related to EHIT [4,7]. However, there are no definitive guidelines for management of EHIT [11]. Recent studies have identified several risk factors for EHIT—for example, age, gender, pre-existing thrombophilic disorders, Clinical-Etiological-Anatomical-Pathophysiological class, shorter ablation distance from the SFJ, incorrect positioning of the laser or radiofrequency fiber, higher laser wavelengths, and use of general anesthesia (precluding immediate ambulation)—but all these are still controversial [11]. According to the Vascular and Endovascular Issues Techniques and Horizons symposium, EHIT was categorized into four classes, with management and treatment recommendations given for each class [3].

Class I: venous thrombosis to the superficial-deep junction (for example, SFJ or sapheno-popliteal junction, but not extending into the deep system).

Class II: non-occlusive venous thrombosis, with an extension into the deep system of a cross sectional area of less than 50%.

Class III: non-occlusive venous thrombosis into the deep venous system, with an extension into the deep system of a cross sectional area of more than 50%.

Class IV: occlusive DVT of the CFV.

Kabnick and Berland [3] (2011) has recommended duplex ultrasound observation for Class I. For Class II, the recommendation is LMWH therapy until reclassified to class I. Lastly, for Class III and Class IV, it was strongly recommended to treat these entities according to the suggested guidelines for DVT [3]. However, in this case, combined treatment of deep venous thrombosis for complete restoration of blood flow should be noted, which includes angiographic-intervention and surgical thrombectomy, because other reported EHIT cases had been treated with surgical or interventional treatment alone. This case demonstrates that EHIT cases can be treated with thrombolytic therapy combined with surgical intervention.

A pathophysiological understanding of EHIT and special attention to its treatment are essential when performing EVLA. Yet, there are no definitive guidelines pertaining to time of occurrence, actual incidence, risk factors, appropriate treatment, and follow-up timing of EHIT, despite the risk for life-threatening complications, such as PTE. Furthermore, to date, a large randomized trial to suggest guidelines for EHIT management has yet to be conducted. Specifically, we need more attention placed on the clinical significance of EHIT, and it requires further study. With a better understanding of EHIT, clinicians would be able to closely follow-up on their patients, recognize features of EHIT, identify related risk factors, and prevent adverse events after EVLA.

REFERENCES

- 1) Kundu S, Lurie F, Millward SF, Padberg F Jr, Vedantham S, Elias S, et al. Recommended reporting standards for endovenous ablation for the treatment of venous insufficiency: joint statement of The American Venous Forum and The Society of Interventional Radiology. *J Vasc Surg* 2007;46:582-589.
- 2) Siribumrungwong B, Noorit P, Wilasrusmee C, Attia J, Thakkinstian A. A systematic review and meta-analysis of randomised controlled trials comparing endovenous ablation and surgical intervention in patients with varicose vein. *Eur J Vasc Endovasc Surg* 2012;44:214-223.
- 3) Kabnick L, Berland T. Endothermal heat-induced thrombosis (EHIT). Paper presented at: 38th Annual Vascular and Endovascular Issues, Techniques and Horizons (VEITH symposium); 2011 Nov 16-20; New York, USA. p. 1-8.
- 4) Lin JC, Peterson EL, Rivera ML, Smith JJ, Weaver MR. Vein mapping prior to endovenous catheter ablation of the great saphenous vein predicts risk of endovenous heat-induced thrombosis. *Vasc Endovascular Surg* 2012;46:378-383.
- 5) Nwaejike N, Srodon PD, Kyriakides C. 5-years of endovenous laser ablation (EVLA) for the treatment of varicose veins—a prospective study. *Int J Surg* 2009;7:347-349.
- 6) Rasmussen LH, Lawaetz M, Bjoern L, Vennits B, Blemings A, Eklof B. Randomized clinical trial comparing endovenous laser ablation, radiofrequency ablation, foam sclerotherapy and surgical stripping for great

saphenous varicose veins. *Br J Surg* 2011;98:1079-1087.

- 7) Mozes G, Kalra M, Carmo M, Swenson L, Gloviczki P. Extension of saphenous thrombus into the femoral vein: a potential complication of new endovenous ablation techniques. *J Vasc Surg* 2005;41:130-135.
- 8) Marsh P, Price BA, Holdstock J, Harrison C, Whiteley MS. Deep vein thrombosis (DVT) after venous thermoablation techniques: rates of endovenous heat-induced thrombosis (EHIT) and

classical DVT after radiofrequency and endovenous laser ablation in a single centre. *Eur J Vasc Endovasc Surg* 2010;40:521-527.

- 9) Harlander-Locke M, Jimenez JC, Lawrence PF, Derubertis BG, Rigberg DA, Gelabert HA, et al. Management of endovenous heat-induced thrombus using a classification system and treatment algorithm following segmental thermal ablation of the small saphenous vein. *J Vasc Surg* 2013;58:427-431.

- 10) Rhee SJ, Cantelmo NL, Conrad MF, Stoughton J. Factors influencing the incidence of endovenous heat-induced thrombosis (EHIT). *Vasc Endovascular Surg* 2013;47:207-212.

- 11) Kane K, Fisher T, Bennett M, Shutze W Jr, Hicks T, Grimsley B, et al. The incidence and outcome of endothermal heat-induced thrombosis after endovenous laser ablation. *Ann Vasc Surg* 2014;28:1744-1750.