

Case Report

Carotid–carotid crossover bypass after mechanical thrombectomy for internal carotid artery occlusion due to plaque from stenosed innominate artery

Tomoaki Murakami, Shingo Toyota, Takuya Suematsu, Yuki Wada, Takeshi Shimizu, Takuyu Taki

Department of Neurosurgery, Kansai Rosai Hospital, Amagasaki, Hyogo, Japan.

E-mail: Tomoaki Murakami - mmtmtomoaki@gmail.com; *Shingo Toyota - stshto@aol.com; Takuya Suematsu - tkysemt@gmail.com; Yuki Wada - yukiwada0728@gmail.com; Takeshi Shimizu - takeshi.shimizu32@gmail.com; Takuyu Taki - taki-takuyu@kansaih.johas.go.jp



*Corresponding author:

Shingo Toyota,
Department of Neurosurgery,
Kansai Rosai Hospital,
Amagasaki, Hyogo, Japan.

stshto@aol.com

Received : 30 July 2021
Accepted : 14 September 2021
Published : 30 September 2021

DOI
[10.25259/SNI_749_2021](https://doi.org/10.25259/SNI_749_2021)

Quick Response Code:



ABSTRACT

Background: The treatment for internal carotid artery occlusion (ICAO) due to innominate artery stenosis is not well established. We herein describe a case of carotid–carotid crossover bypass and common carotid artery (CCA) ligation after mechanical thrombectomy for ICAO due to a plaque from the stenosed innominate artery.

Case Description: A 70-year-old man was transferred to our hospital because of left-sided hemiparesis. Head magnetic resonance imaging/angiography showed a cerebral infarction in the right middle cerebral artery area and the right ICAO due to a plaque from the stenosed innominate artery. Immediately, we performed mechanical thrombectomy and successfully attained partial revascularization (Thrombolysis in Cerebral Infarction Grade 2B). After a conference with cardiovascular group, we performed carotid–carotid crossover bypass and the right CCA ligation. The treatment was successful, and no complications occurred.

Conclusion: Carotid–carotid crossover bypass and CCA ligation may be a better option for innominate artery stenosis in selected patients.

Keywords: Carotid–carotid crossover bypass, Cerebral infarction, Innominate artery stenosis, Tandem, Thrombectomy

INTRODUCTION

Atherosclerotic stenosis of the innominate artery (IA) is reportedly rare, accounting for 0.5–2.5% of all vascular lesions.^[17] Although the natural history of IA stenosis (IAS) is unknown,^[14] a few reports have indicated that this lesion can cause cerebral infarction by hemodynamic flow reduction and distal embolization.^[12,15] In general, asymptomatic IAS should be treated conservatively. However, revascularization is usually recommended for symptomatic IAS.^[14] The treatment options for IAS consist of open surgery, including bypass surgery, transposition, and endarterectomy; endovascular surgery, including percutaneous transluminal angioplasty with or without stenting; and hybrid surgery.^[14,17] However, which treatment is better for plaque lesions that affect the IA and ipsilateral internal carotid artery (ICA) remains unclear.^[14]

We herein describe carotid–carotid crossover bypass and common carotid artery (CCA) ligation in a patient with symptomatic IAS after mechanical thrombectomy for ICA occlusion (ICAO)

This is an open-access article distributed under the terms of the Creative Commons Attribution-Non Commercial-Share Alike 4.0 License, which allows others to remix, tweak, and build upon the work non-commercially, as long as the author is credited and the new creations are licensed under the identical terms.

©2021 Published by Scientific Scholar on behalf of Surgical Neurology International

due to a plaque from the stenosed IA. To the best of our knowledge, no such case has been reported to date.

CASE DESCRIPTION

A 70-year-old man was admitted to our hospital with left hemiparesis and a National Institutes of Health Stroke Scale score of 8. He had been diagnosed with subtle right cerebral infarction [Figure 1a] and right IA-subclavian artery (SA)-proximal CCA stenosis 9 months previously [Figure 1b], and he had been treated conservatively with administration of aspirin and clopidogrel in our institute. Diffusion-weighted magnetic resonance imaging (DWI) and magnetic resonance angiography (MRA) showed occlusion of the right ICA with an acute cerebral infarction in the right middle cerebral artery area (DWI-Alberta Stroke Program Early Computed Tomography Score of 9) [Figure 1c and d]. Atrial fibrillation was not detected by Holter electrocardiography.

Mechanical thrombectomy

Because the duration since symptom onset exceeded 4.5 h, the patient was not a candidate for intravenous injection of tissue plasminogen activator. The endovascular procedure was started through a 9-Fr femoral sheath under local anesthesia. A 9-Fr balloon guiding catheter (Optimo;

Tokai Medical Products, Aichi, Japan) was placed in the IA. Angiography showed severe stenosis from the IA to the proximal CCA and occlusion of the right SA [Figure 2a]. As the balloon guiding catheter was carefully passed over the IA lesion, CCA angiography revealed occlusion of the ICA [Figure 2b]. We initiated the thrombectomy for the right ICAO, giving precedence to cerebral reperfusion. A CAT 6 catheter (Stryker Neurovascular, Kalamazoo, MI, USA), Trevo Trak 21 microcatheter (Stryker Neurovascular), and CHIKAI 0.014-inch microguidewire (ASAHI INTECC, Nagoya, Japan) were advanced as a coaxial system. The microguidewire and microcatheter traversed the ICA thrombus. A Trevo NXT 4- × 41-mm stent (Stryker Neurovascular) was placed across the occluded lesion. The Trevo stent, Trevo Trak 21, and CAT 6 catheter were pulled back together through the inflated balloon under continuous suction, and a red clot was retrieved. After a second pass using the same system, ICA angiography showed partial recanalization of the inferior trunk of the middle cerebral artery (Thrombolysis in Cerebral Infarction Grade 2B) [Figure 2c]. MRA and DWI on postoperative day 1 showed successful recanalization and localized ischemic change [Figure 3a and b]. We also identified severe IAS

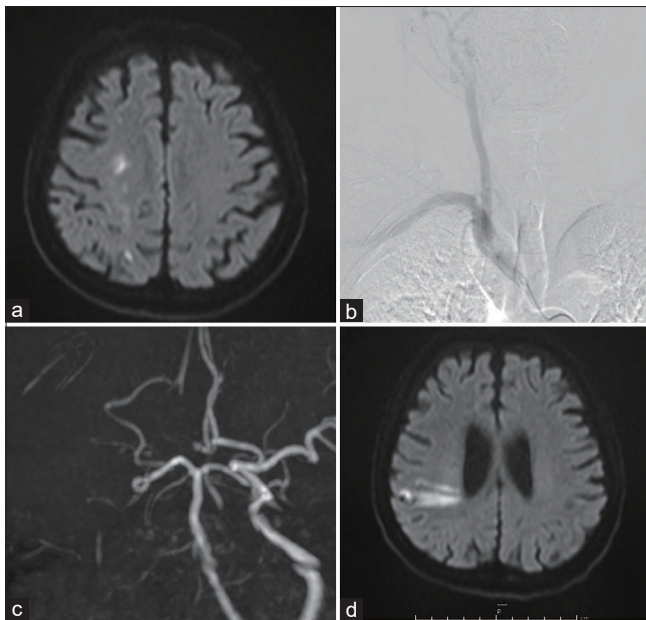


Figure 1: Pretreatment imaging (a and b) 9 months before presentation and (c, d) on admission before thrombectomy. (a) DWI revealed subtle right cerebral infarction indicating artery to artery embolism. (b) IA angiogram showed right IA-SA-proximal CCA stenosis. (c) Right ICA was occluded on MRA. (d) DWI showed acute cerebral infarction in the right middle cerebral artery area (DWI-Alberta Stroke Program Early Computed Tomography Score of 9).

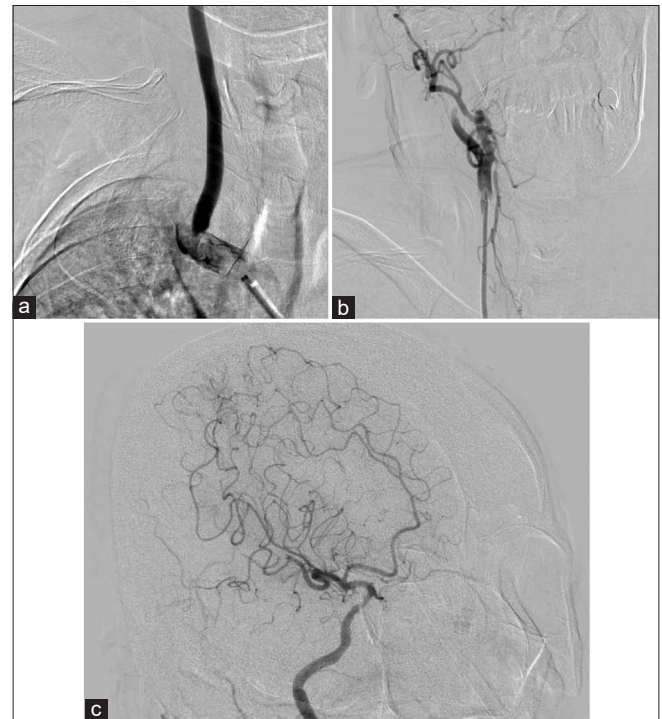


Figure 2: Diagnostic angiogram and mechanical thrombectomy. (a) Frontal view of IA angiogram showed severe stenosis from the IA to proximal CCA and occlusion of the right SA. (b) Frontal view of right CCA angiogram revealed occlusion of the right ICA. (c) Oblique view of right ICA angiogram showed partial recanalization (Thrombolysis in Cerebral Infarction grade 2b) without several branches.

by postoperative computed tomography angiography [Figure 3c and d]. We started postprocedural therapy using an anticoagulant (edoxaban) and dual antiplatelet therapy (clopidogrel and cilostazol) to stabilize the plaque. Because the cause of the repeated cerebral infarction was distal embolization from the stenosed IA, we initiated treatment of this lesion to prevent recurrent stroke. After a conference with cardiac surgeons and cardiologists, we selected carotid-carotid crossover bypass and CCA ligation. The cilostazol was stopped 3 days before the operation and the edoxaban was stopped 1 day before the operation to decrease the risk of perioperative bleeding.

Carotid-carotid crossover bypass and CCA ligation

On the 35th hospital day, we performed carotid-carotid crossover bypass and CCA ligation to prevent recurrent embolization from the stenosed IA. The surgery was performed in a hybrid operating room. Endotracheal intubation anesthesia was provided, and the patient's neck was stretched in the supine position. Monitoring was performed using near infrared spectroscopy (INVOS system; Medtronic, Minneapolis, MN, USA). Linear skin incisions of 6 cm were made bilaterally along the anterior edges of the sternocleidomastoid. The bilateral CCA, ICA, and external carotid artery were exposed; the retropharyngeal space

was explored with the fingers; and a 6-mm heparin-bound polytetrafluoroethylene (PTFE) vascular graft (Propaten; W. L. Gore and Associates, Inc. Newark, DE, USA) was crossed through the space. The graft was trimmed according to the bypass requirements. Before clamping the CCA for the anastomosis, 4000 U of systemic heparin was administered, and the patient's systolic blood pressure increased by 20% over the basal value. First, end-to-side anastomosis between the graft and left CCA was performed with continuous suturing using CV-6 Gore-Tex (W. L. Gore and Associates, Inc.). The same procedure was then performed for the right CCA [Figure 4a]. After the systolic blood pressure had decreased to the basal level, the right CCA was ligated using 2-0 silk. Heparin was neutralized and intraoperative

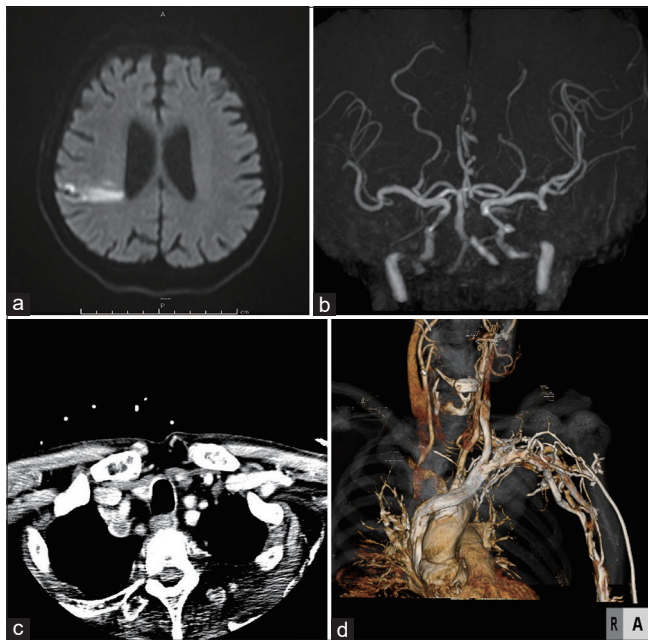


Figure 3: Post thrombectomy head DWI and neck CTA. (a) DWI showed localized ischemic change in the territory of the right MCA that was almost identical to the preoperative DWI. (b) MRA showed recanalization of the right ICA and MCA without several distal branches. (c) The axial view of neck CTA indicated a massive plaque occupying the IA and right SA (d) CTA showed severe stenosis of the IA and proximal CCA as well as occlusion of the right SA.

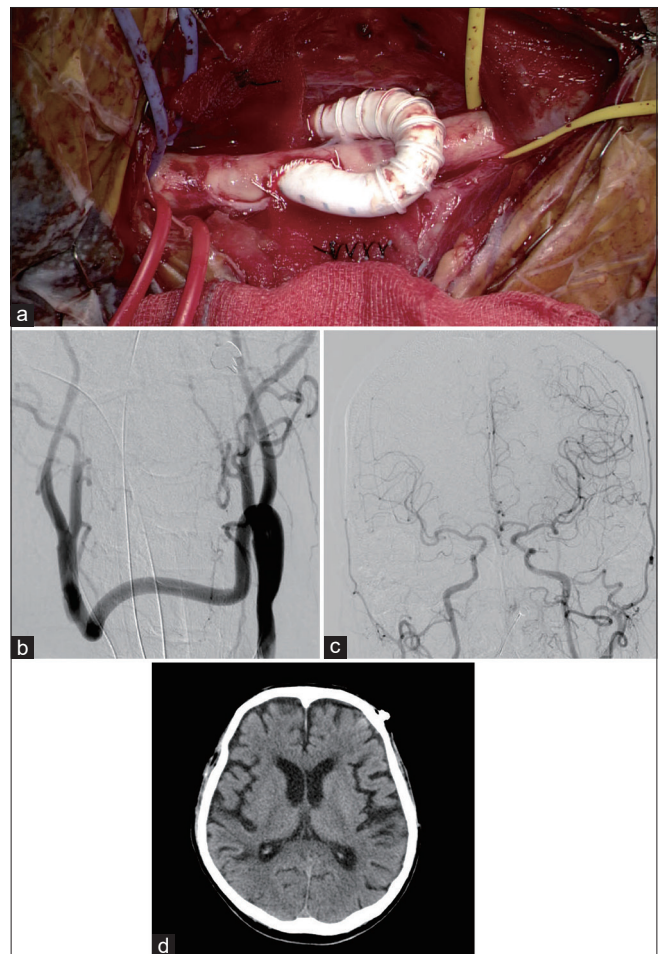


Figure 4: (a) Microsurgical view and (b-d) postoperative imaging. (a) End-to-side anastomosis between the PTFE vascular graft through the retropharyngeal tunnel and the right CCA was performed. (b) Frontal view of left CCA angiogram revealed patency of the bypass and complete ligation of the right CCA. (c) Frontal view of left CCA angiogram revealed anterograde flow of the bilateral intracranial ICAs. (d) Postoperative computed tomography showed no remarkable change compared with preoperative computed tomography.

digital subtraction angiography was performed to assess the patency of the bypass and ligation of the right CCA. Finally, the bilateral incisions were closed. One day after the surgery, the patency of the bypass, ligation of the right CCA, and antegrade flow of the bilateral intracranial ICAs were assessed by angiography [Figure 4b and c]. Postoperative computed tomography showed no remarkable change compared to preoperative computed tomography [Figure 4d].

Postoperative therapy was performed in accordance with the usual postoperative management of carotid endarterectomy. We started antiplatelet therapy (clopidogrel 75 mg/day) for lifetime. And the cervical collar was used to protect the bleeding from surgical wound for three days.

The patient was discharged to home with no procedural complications (modified Rankin scale score of 1) on day 56.

DISCUSSION

To the best of our knowledge, this is the first report of carotid-carotid crossover bypass in a patient with symptomatic IAS after mechanical thrombectomy for ipsilateral ICAO. The optimal strategy for treating tandem proximal artery stenosis and ipsilateral distal artery occlusion is controversial.^[1,13,19] In the present case, we performed mechanical thrombectomy for the ICAO on the grounds of DWI-MRA mismatch to give priority to cerebral perfusion, and we intentionally left the IAS untreated at first because of the complex saddle lesion including SA occlusion. A previous report stated that the treatment of an IA saddle embolus must be performed with great care because of distal embolism.^[6]

The treatment of IAS consists of a transthoracic approach, an extrathoracic approach, and an endovascular approach in some literature review.^[3,4,14,17,18] Although the transthoracic approach has a high long-term patency rate (88% at 10 years), this approach is associated with significant operative mortality (8%).^[4] The extrathoracic approach (including SA-carotid bypass, carotid-carotid bypass, and others) has a similar patency rate (82% at 10 years) but a lower operative mortality rate (0.5%).^[3] On the other hands, in a previous report of endovascular therapy for IAS, long-term results have not yet been reported.

In the present case, we discussed optimal treatment for this IAS, including carotid-carotid crossover bypass and CCA ligation, SA-carotid bypass, IA - CCA bypass and endovascular surgery, with cardiac surgeons and cardiologists. SA-carotid bypass was not recommended because the occluded right SA was not suitable as a donor artery in the present case, and IA - CCA bypass which needed on-pump arrest procedure was invasive. Furthermore, in the present case, we considered that the plaque in the complex saddle lesion with SA occlusion was clinically unstable

because cerebral infarction had already occurred twice in the ipsilateral lesion. After a conference with cardiovascular group, we selected carotid-carotid crossover bypass and CCA ligation as an elective surgery to treat the symptomatic IAS.

The previous studies have shown that carotid-carotid crossover bypass is effective and safe for the IA as well as for CCA occlusive and aneurysmal diseases.^[3,7,9-11,16] Ozsvath *et al.*^[16] analyzed 24 carotid-carotid crossover bypass procedures and found no perioperative deaths and excellent bypass patency (92% at 3 years). In addition, the stroke-free survival rate was 94% at 4 year.^[16] Several studies have suggested that this excellent bypass patency results from the advantages of the retropharyngeal approach.^[16,20] Specifically, the retropharyngeal route is shorter than the anterior trachea route,^[2,5,16,20] and the graft in the retropharyngeal space can be protected from injury because of its deep position in the neck.^[2,5,16,20]

The materials currently used as vascular grafts for carotid-carotid crossover bypass are prosthetic vascular grafts^[7,9] and the autologous saphenous vein.^[11] In general, prosthetic vascular grafts are divided into expanded PTFE and Dacron. In the present case, we used a heparin-bound PTFE vascular graft. Although the superiority of prosthetic vascular grafts over autologous venous grafts remains unclear,^[8] PTFE grafts have two main advantages. First, they have supportive rings similar to tracheal rings, which overcomes the problems of venous distortion, kinking, and compression. Second, PTFE grafts do not require anticoagulant drugs after bypass surgery because of their specific heparin surface.

On the other hands, it has been reported that some complications relating carotid-carotid crossover bypass such as bleeding (4%), stroke (4%), and early occlusion (4%) could occur.^[16] Therefore, it is considered necessary to select an applicable case carefully.

CONCLUSION

Even though the indication is limited, carotid-carotid crossover bypass and CCA ligation can be an effective and safe option for treatment of symptomatic IAS.

Authors' contributions

Drs. Toyota, Taki, and Murakami contributed to the conception and design of the study. Drs. Toyota, Suematsu, Wada, Shimizu, Taki, and Murakami performed the surgery. Drs. Toyota, Taki, and Murakami contributed to the writing and revising of the manuscript.

Acknowledgment

We thank Angela Morben, DVM, ELS, from Edanz Group (<https://en-author-services.edanz.com/ac>), for editing a draft of this manuscript.

Declaration of patient consent

The authors certify that they have obtained all appropriate patient consent.

Financial support and sponsorship

Nil.

Conflicts of interest

There are no conflicts of interest.

REFERENCES

1. Akpınar CK, Gürkaş E, Aytac E. Carotid angioplasty-assisted mechanical thrombectomy without urgent stenting may be a better option in acute tandem occlusions. *Interv Neuroradiol* 2017;23:405-11.
2. Berguer R, Gonzalez JA. Revascularization by the retropharyngeal route for extensive disease of the extracranial arteries. *J Vasc Surg* 1994;19:217-24; discussion 225.
3. Berguer R, Morasch MD, Kline RA, Kazmers A, Friedland MS. Cervical reconstruction of the supra-aortic trunks: A 16-year experience. *J Vasc Surg* 1999;29:239-46; discussion 246-8.
4. Berguer R, Morasch MD, Kline RA. Transthoracic repair of innominate and common carotid artery disease: Immediate and long-term outcome for 100 consecutive surgical reconstructions. *J Vasc Surg* 1998;27:34-41; discussion 42.
5. Berguer R. The short retropharyngeal route for arterial bypass across the neck. *Ann Vasc Surg* 1986;1:127-9.
6. Brusett KA, Kwasnik EM, Marjani MA. Innominate artery saddle embolus: A pitfall for retrograde brachial embolectomy. *J Vasc Surg* 1997;25:569-71.
7. Chen C, Ye Z, Luo L, Guo Y, Chang Y, Ning X, *et al.* Carotid-carotid artery crossover bypass with a synthetic vascular graft for symptomatic Type 1A common carotid artery occlusion. *World Neurosurg* 2018;111:e286-93.
8. Klonaris C, Kouvelos GN, Kafaza M, Koutsoumpelis A, Katsargyris A, Tsigris C. Common carotid artery occlusion treatment: Revealing a gap in the current guidelines. *Eur J Vasc Endovasc Surg* 2013;46:291-8.
9. Kovacevic P, Velicki L, Ivanovic V, Kieffer E. Carotid-carotid bypass as an option in the treatment of infected pseudoaneurysm after prosthetic carotid replacement. *Ann Vasc Surg* 2013;27:239.e13-6.
10. Li ZY, Chen C, Ling C, He HY, Luo L, Li H, *et al.* Surgical procedures including carotid-carotid crossover bypass and ring-stripping hybrid operation for riley's Type 1A common carotid artery occlusion: An experience of 6 cases. *Ann Transl Med* 2020;8:439.
11. Morofuji Y, Matsunaga Y, Izumo T. Carotid-carotid bypass for a carotid artery aneurysm. *World Neurosurg* 2020;138:7-8.
12. Moustafa RR, Antoun NM, Coulden RA, Warburton EA, Baron JC. Stroke attributable to a calcific embolus from the brachiocephalic trunk. *Stroke* 2006;37:e6-8.
13. Mpotsaris A, Bussmeyer M, Buchner H, Weber W. Clinical outcome of neurointerventional emergency treatment of extra-or intracranial tandem occlusions in acute major stroke: Antegrade approach with wallstent and solitaire stent retriever. *Clin Neuroradiol* 2013;23:207-15.
14. Naylor AR, Ricco JB, de Borst GJ, Debus S, de Haro J, Halliday A, *et al.* Editor's choice-management of atherosclerotic carotid and vertebral artery disease: 2017 clinical practice guidelines of the European society for vascular surgery (ESVS). *Eur J Vasc Endovasc Surg* 2018;55:3-81.
15. Oweida SW, Ku DN, Justicz AG, Burnson B, Salam AA. Hemodynamic consequences of carotid-carotid bypass for innominate artery stenosis. *J Vasc Surg* 1991;13:416-22.
16. Ozsvath KJ, Roddy SP, Darling RC 3rd, Byrne J, Kreienberg PB, Choi D, *et al.* Carotid-carotid crossover bypass: Is it a durable procedure? *J Vasc Surg* 2003;37:582-5.
17. Paukovits TM, Lukács L, Bérczi V, Hirschberg K, Nemes B, Hüttl K. Percutaneous endovascular treatment of innominate artery lesions: A single-centre experience on 77 lesions. *Eur J Vasc Endovasc Surg* 2010;40:35-43.
18. van de Weijer MA, Vonken EJ, de Vries JP, Moll FL, Vos JA, de Borst GJ. Technical and clinical success and long-term durability of endovascular treatment for atherosclerotic aortic arch branch origin obstruction: Evaluation of 144 procedures. *Eur J Vasc Endovasc Surg* 2015;50:13-20.
19. Wilson MP, Murad MH, Krings T, Pereira VM, O'Kelly C, Rempel J, *et al.* Management of tandem occlusions in acute ischemic stroke-intracranial versus extracranial first and extracranial stenting versus angioplasty alone: A systematic review and meta-analysis. *J Neurointerv Surg* 2018;10:721-8.
20. Yoneyama F, Sato F, Tokunaga C, Sakamoto H, Enomoto Y, Watanabe Y, *et al.* Postoperative dysphagia in debranching thoracic endovascular aortic repair with retrosophageal carotid-carotid bypass. *Ann Vasc Surg* 2017;43:315.e1-4.

How to cite this article: Murakami T, Toyota S, Suematsu T, Wada Y, Shimizu T, Taki T. Carotid-carotid crossover bypass after mechanical thrombectomy for internal carotid artery occlusion due to plaque from stenosed innominate artery. *Surg Neurol Int* 2021;12:480.