

Case Report

Palliative Radiotherapy Provided Good Pain Relief for Painful Adrenal Metastasis

Masashi Endo^a Yukiko Fukuda^a Kazunari Ogawa^a Satoru Takahashi^a

Michiko Nakamura^a Masahiro Kawahara^b Keiko Akahane^b

Yoshitaka Yamanouchi^c Koichi Hagiwara^c Harushi Mori^a

Katsuyuki Shirai^a

^aDepartment of Radiology, Jichi Medical University Hospital, Shimotsuke, Japan;

^bDepartment of Radiology, Jichi Medical University Saitama Medical Center, Saitama, Japan;

^cDivision of Pulmonary Medicine, Department of Internal Medicine, Jichi Medical University Hospital, Shimotsuke, Japan

Keywords

Non-small cell lung carcinoma · Adrenal metastasis · Radiotherapy

Abstract

Adrenal metastases often occur in patients with metastasized lung cancer, but symptoms rarely develop. A 45-year-old man presented with right abdominal pain requiring strong opioids due to large right adrenal metastasis of lung adenocarcinoma. The tumor was 7.3 × 5.6 × 8.4 cm in size. He was treated with palliative radiotherapy (RT) up to 39 Gy in 13 fractions for this lesion without severe adverse effects. After RT, he had good pain relief, and opioids were no longer needed. Palliative RT for a large adrenal tumor can provide a good analgesic effect without relevant toxicity.

© 2021 The Author(s).

Published by S. Karger AG, Basel

Introduction

Adrenal metastases are frequently seen in patients with metastasized lung cancer. Rarely, the patients develop localized symptoms such as back or abdominal pain. Since these symptoms can worsen the patient's quality of life, palliative treatments are required. A historical study reported that palliative radiotherapy (RT) improved pain in 75.0% of patients with adrenal metastases of lung cancer [1]. To date, there are a few reports of palliative RT for adrenal metastases; however, the appropriate RT strategy is still unclear. A case of adrenal

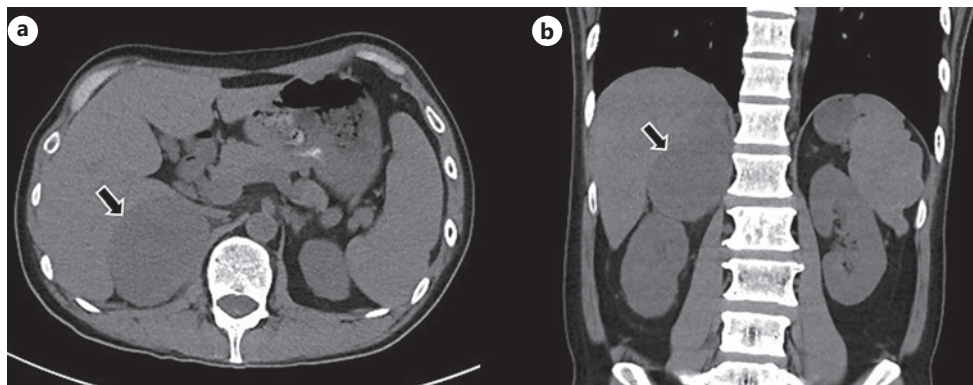


Fig. 1. Noncontrast CT scan of the abdomen. Axial (a) and coronal (b) images show a low-density mass in the right adrenal gland (arrow).

metastases from non-small cell lung carcinoma (NSCLC) with abdominal pain in which strong opioids could be discontinued after palliative RT is presented.

Case Report

A 45-year-old man was diagnosed with NSCLC (adenocarcinoma) in the right apex of the lung in December 2019. The tumor was accompanied by mediastinal invasion and pleural dissemination (cT4N0M1a stage IVA). The programmed cell death-ligand 1 expression of the tumor was 50–74%, whereas epidermal growth factor receptor mutation analysis and anaplastic lymphoma kinase rearrangement were negative. He had a history of peripheral T-cell lymphoma and received high-dose chemotherapy with autologous peripheral blood stem cell transplantation with complete remission in 2013, and there was no evidence of relapse.

He was treated with carboplatin (AUC 5 mg/mL/min), pemetrexed (500 mg/m²), and pembrolizumab (200 mg/body). After 4 courses, in March 2020, he presented with slowly increasing right abdominal pain. Noncontrast CT showed no significant changes in the primary tumor of the right lung, but a 7.3 × 5.6 × 8.4 cm mass in the right adrenal gland was identified (Fig. 1). The tumor volume was 200 cm³. Endoscopic ultrasound-fine needle aspiration for the adrenal tumor was performed, and the diagnosis was a metastasis of NSCLC. Due to the disease progression, S-1 (100 mg/day) was initiated as second-line chemotherapy.

Although he was taking oxycontin (10 mg twice per day), tramadol/acetaminophen (12.5 mg/375 mg 3 times per day) combination tablets, and naproxen (100 mg 3 times per day), the abdominal pain was uncontrolled. He was offered palliative RT with 39 Gy in 13 fractions to the right adrenal tumor (Fig. 2). During the RT, he developed nausea (grade 2) for which he received granisetron 2 mg/day. The nausea was well controlled, and the RT was tolerated without any other acute adverse events.

One month after completion of RT, the patient had good pain relief and was able to discontinue oxycontin. Noncontrast CT 6 months after treatment showed marked shrinkage of the adrenal tumor (Fig. 3). Furthermore, he reported improvement of the pain and was also able to stop taking tramadol/acetaminophen. At 9-month follow-up, he developed brain metastases for which he received whole-brain RT (30 Gy in 10 fractions). No abdominal pain requiring opioids and chronic severe adverse events occurred during follow-up. Docetaxel has been planned as third-line chemotherapy.

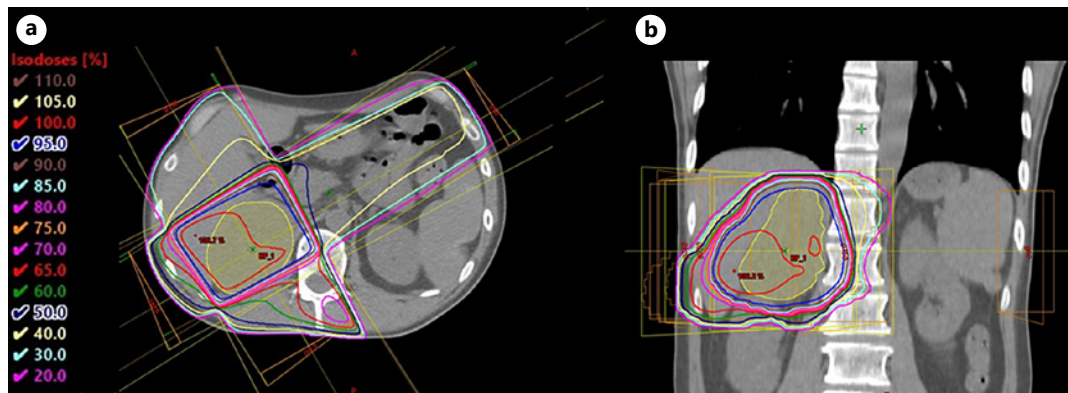


Fig. 2. Palliative RT with 39 Gy in 13 fractions was delivered to the right adrenal tumor. **a** Axial image. **b** Coronal image. The gross tumor volumes were contoured in yellow. RT, radiotherapy.

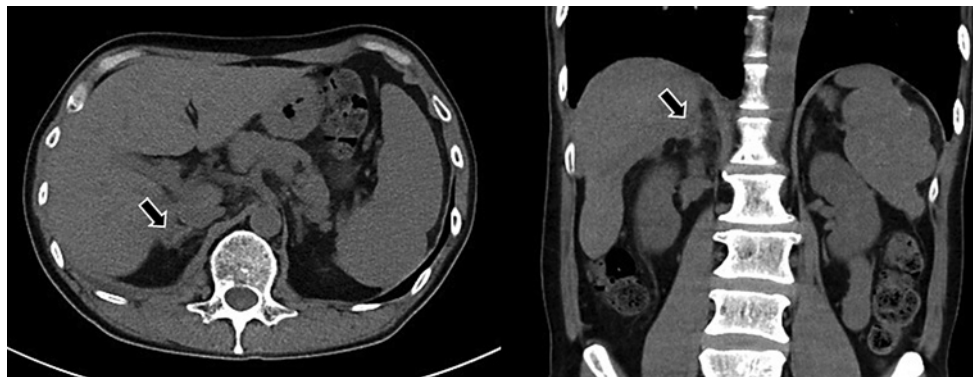


Fig. 3. After RT, the tumor has almost disappeared (arrow). RT, radiotherapy.

Discussion and Conclusion

This case highlights 2 important clinical issues. First, palliative RT provided a good analgesic effect for painful adrenal metastases of NSCLC. Second, RT was safe even for a large tumor because no significant toxicities occurred. There are few reports in the literature on palliative RT for adrenal lesions, and the treatment strategy has not yet been established.

Palliative RT provided a good analgesic effect for painful adrenal metastasis. The adrenal glands are known to be one of the common sites of metastases. A large autopsy study showed that lung cancer metastasized to the adrenal gland in 35.6% of cases [2]. On the other hand, patients with adrenal metastases rarely suffer from symptoms; Lam et al. [3] reported that only 4.3% of patients were symptomatic. Another study noted that only 2 of 16 patients with adrenal metastases had symptoms, and they both had pain [4]. According to Berger et al. [5], the pain syndrome is hypothesized to be involvement of or pressure on the abdominal ganglia, and it occurs only in patients with adrenal metastases >5 cm [5]. In 1990, Soffen et al. [1] reported that palliative RT improved pain in 75.0% (12 of 16 patients) with adrenal metastases of lung cancer. They also noted that 6 patients (37.5%) obtained complete pain relief and no longer needed analgesics. Although RT is already known to be effective for symptomatic adrenal metastases historically, it might have seldom been considered due to the short life expectancy of the patients [6]. Recently, advances

in the treatment of cases of extensive disease have prolonged the prognosis of patients, so that the management of symptomatic adrenal metastases will become an increasingly important issue. Palliative RT is thus still needed for patients with painful adrenal metastases and extensive disease. The present case showed that RT provided pain relief, which led to the discontinuation of opioids. For the painful conditions of such patients, opioids are currently invaluable, but clinicians need to be aware of their side effects and complications, which may threaten the patient's quality of life [7]. Thus, there are benefits for patients to discontinue opioids if possible.

The present case also showed that RT could be tolerated with limited toxicity for large adrenal metastases with a volume of 200 cm³. Few reports have evaluated the appropriate tumor size for conventional RT. To the best of our knowledge, the tumor volume of the largest adrenal metastasis treated with conventional RT has been reported by Buegy et al. [4], and it was 261 cm³. The authors noted that no high-grade acute and late toxicities were observed. There is a report of RT for controlling adrenal metastases of hepatocellular carcinoma [8]. In this report, the largest adrenal tumor was 15.0 cm in size, and severe adverse events were not frequent. As these reports show, the present case also suggests that irradiation can be safely performed even for large adrenal tumors.

From the perspective of local control, adrenalectomy is currently the standard treatment. A multicenter study suggested that adrenal metastasectomy could provide longer survival [9]. More recently, stereotactic body radiotherapy (SBRT) has emerged as a noninvasive modality for treating adrenal metastases, which is also available for patients not eligible for surgery. It has been reported that SBRT could also provide good local control with low toxicity [10]. However, these aggressive procedures can basically be indicated for patients with a controlled primary lesion and a limited number of metastases (defined as oligometastasis). Even if such treatment is not indicated for patients with painful adrenal metastases, palliative RT should be positively considered.

In conclusion, RT for large adrenal metastases of NSCLC could provide a good analgesic effect with safety. Thus, such patients should be considered for palliative RT, even if the tumor is large. Further studies are needed to evaluate the efficacy and safety of palliative RT for adrenal lesions.

Acknowledgment

The authors thank Forte Inc. (www.forte-science.co.jp) for their English language editing services.

Statement of Ethics

Written informed consent was obtained from the patient for publication of this case report and any accompanying images. The Jichi Medical University Central Clinical Research Ethics Committee has determined that our project does not meet "Common Rule" definition of human subjects' research and does not require CRB review. The Certified Review Board number is 3200006.

Conflict of Interest Statement

The authors have no conflicts of interest.

Funding Sources

This research did not receive any specific grant from funding agencies in the public, commercial, or not-for-profit sectors.

Author Contributions

M. Endo, H. Mori, and K. Shirai designed the study. M. Endo, Y. Yamanouchi, and K. Hagiwara were involved in the patient's management. Y. Fukuda, K. Ogawa, S. Takahashi, M. Nakamura, M. Kawahara, and K. Akahane contributed to the analysis of the results. K. Hagiwara, H. Mori, and K. Shirai supervised the project. All authors approved the final manuscript.

Data Availability Statement

Owing to ethical restrictions, the raw data underlying this study are available upon request to the corresponding author.

References

- 1 Soffen EM, Solin LJ, Rubenstein JH, Hanks GE. Palliative radiotherapy for symptomatic adrenal metastases. *Cancer*. 1990;65(6):1318–20.
- 2 Abrams HL, Spiro R, Goldstein N. Metastases in carcinoma; analysis of 1000 autopsied cases. *Cancer*. 1950; 3(1):74–85.
- 3 Lam KY, Lo CY. Metastatic tumours of the adrenal glands: a 30-year experience in a teaching hospital. *Clin Endocrinol*. 2002;56(1):95–101.
- 4 Buergy D, Rabe L, Siebenlist K, Stieler F, Fleckenstein J, Giordano FA, et al. Treatment of adrenal metastases with conventional or hypofractionated image-guided radiation therapy: patterns and outcomes. *Anticancer Res*. 2018;38(8):4789–96.
- 5 Berger MS, Cooley ME, Abraham JL. A pain syndrome associated with large adrenal metastases in patients with lung cancer. *J Pain Symptom Manage*. 1995;10(2):161–6.
- 6 Miyaji N, Miki T, Itoh Y, Shimada J, Takeshita T, Churei H, et al. Radiotherapy for adrenal gland metastasis from lung cancer: report of three cases. *Radiat Med*. 1999;17(1):71–5.
- 7 Benyamin R, Trescot AM, Datta S, Buenaventura R, Adlaka R, Sehgal N, et al. Opioid complications and side effects. *Pain Physician*. 2008;11(2):S105–20.
- 8 Jung J, Yoon SM, Park HC, Nam TK, Seong J, Chie EK, et al. Radiotherapy for adrenal metastasis from hepatocellular carcinoma: a multi-institutional retrospective study (KROG 13-05). *PLoS One*. 2016;11(3):e0152642.
- 9 Moreno P, De La Quintana Basarrate A, Musholt TJ, Paunovic I, Puccini M, Vidal O, et al. Adrenalectomy for solid tumor metastases: results of a multicenter European study. *Surgery*. 2013;154(6):1215–3.
- 10 Toesca DAS, Koong AJ, von Eyben R, Koong AC, Chang DT. Stereotactic body radiation therapy for adrenal gland metastases: outcomes and toxicity. *Adv Radiat Oncol*. 2018;3(4):621–9.