



Single-session EUS-guided gastroenterostomy and EUS-guided gallbladder drainage in a patient with concomitant gastric outlet obstruction and acalculous cholecystitis

Arslan Talat, MD,¹ Steven Troy, MD,² Prashanth Rau, MD,¹ Mark Hanscom, MD,¹ Anupam Singh, MD,¹ Jaroslav Zivny, MD,¹ Christopher Marshall, MD,¹ Neil B. Marya, MD¹

INTRODUCTION

EUS-guided interventions for cholecystitis and gastric outlet obstruction (GOO) are emerging techniques for high-risk surgical patients.^{1,2} Compared with percutaneous drainage, EUS-guided gallbladder drainage (EUS-GB) has superior clinical and high technical success rates and limited adverse events.³ Similarly, EUS-guided gastroenterostomy (EUS-GE) for GOO has clinical and technical success rates similar to surgical options, with reduced length of stay, hospital costs, and early resumption of oral intake.⁴ When needed, performing both of these procedures concomitantly can be efficient and can obviate the need for additional procedures. In this article, we report both a successful EUS-GB and a successful EUS-GE that were performed in a single session.

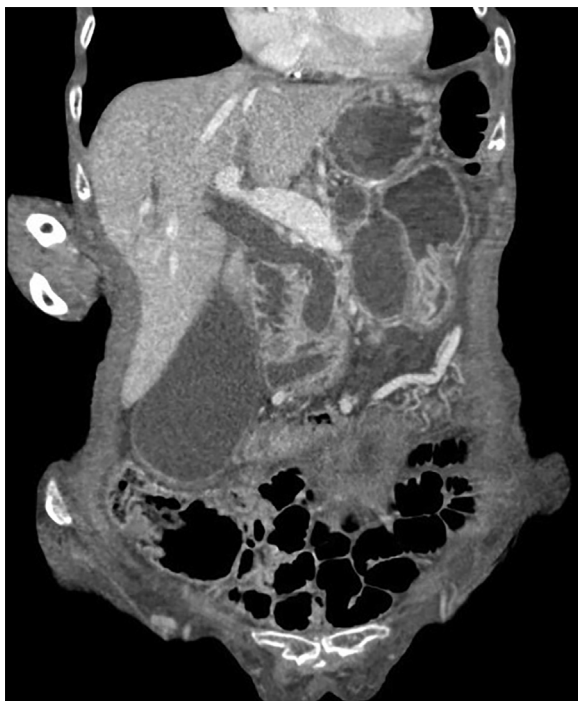

Figure 1. CT scan demonstrating a distended gallbladder and distended stomach.

CASE PRESENTATION

An 82-year-old woman with a history of unresectable pancreatic head adenocarcinoma presented to the hospital with worsening epigastric abdominal pain and difficulty tolerating oral intake. Laboratory work was notable for a total bilirubin level of 0.5 mg/dL and an alkaline phosphatase level of 666 U/L. Cross-sectional imaging of the abdomen demonstrated interval growth of the pancreatic tumor with duodenal invasion resulting in impending GOO. In addition, imaging showed a distended gallbladder with subtle pericholecystic stranding suggestive of acalculous cholecystitis (Fig. 1). Based on the proximity of the pancreatic tumor to the neck of the gallbladder, surgery showed that the patient was not a good candidate for cholecystectomy. Interventional radiology was consulted to perform a percutaneous cholecystostomy; however, they were unavailable to perform the procedure in an expedited fashion. Given the patient's deteriorating condition, our service was consulted for endoscopic management of cholecystitis in the context of impending GOO.

When thinking about what endoscopic interventions to pursue, we considered a few key points regarding this patient's clinical presentation. First, given that the patient was

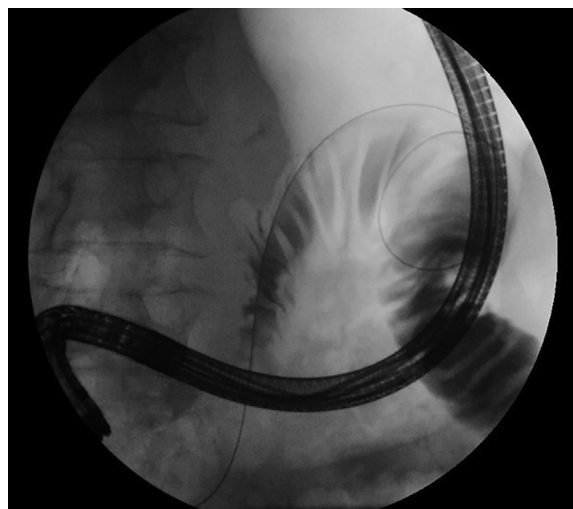


Figure 2. Abdominal radiograph demonstrating placement of a guidewire across the duodenal obstruction with a loop in the proximal jejunum.

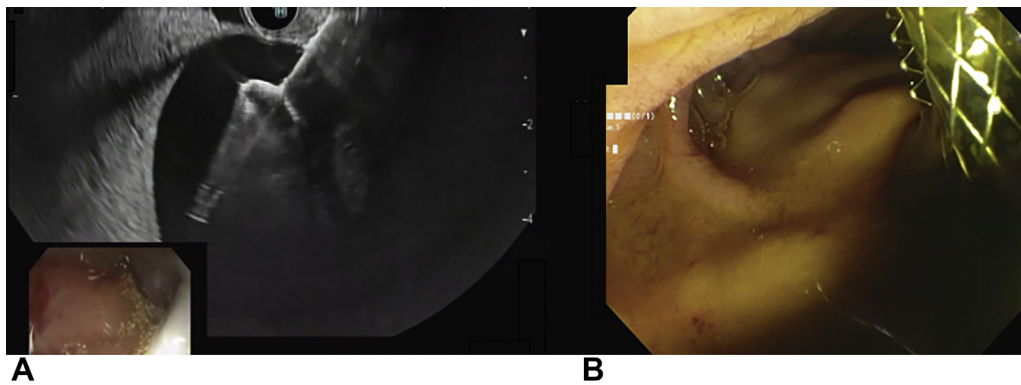


Figure 3. Side-by-side EUS (A) and endoscopic (B) images after gallbladder puncture and deployment of lumen-apposing metal stent.

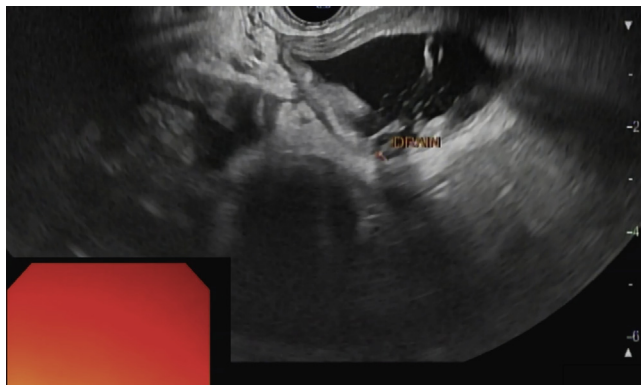


Figure 4. EUS image confirming that the examined small bowel contains the previously placed nasobiliary drain.

not jaundiced and had imaging evidence of cholecystitis, we believed that the most appropriate intervention should be targeted to decompressing the gallbladder. Second, given the patient's actively declining clinical status, we thought it was imperative to perform interventions that would have the highest level of success with the least amount of procedural time. Third, given that the imaging showed that the patient's duodenal stenosis may be just distal to the ampulla, we were concerned that we may be unable to obtain optimal duodenoscope positioning to perform transpapillary/transcystic gallbladder drainage safely and efficiently via ERCP. Given these 3 points, we opted to perform an EUS-GB.

We also were concerned that once biliary access was obtained and drainage commenced, the patient would develop excessive nausea and vomiting because of her impending GOO. Thus, we also wanted to perform an intervention to manage the patient's GOO. When considering options in this case, we chose to perform an EUS-GE instead of enteral stent placement because we did not want to interfere with the EUS-GB procedure. Thus, for this patient, we opted to perform an EUS-GB and an EUS-GE in sequence to manage her cholecystitis in the context of her impending GOO.

PROCEDURE

The entire procedure was performed with the patient in the supine position. With a therapeutic upper endoscope, we identified an acquired, extrinsic stenosis of the second portion of the duodenum. An occlusion balloon catheter over a 0.035-inch Hydra Jagwire (Boston Scientific, Marlborough, Mass, USA) was used to inject contrast into the distal duodenum and proximal jejunum. Once the wire looped in the jejunum (Fig. 2), a 10F nasobiliary drain (Cook Medical, Bloomington, Ind, USA) was put over the wire and into the jejunum.

A linear echoendoscope was then used to visualize the gallbladder. The optimal window for EUS-guided drainage was identified in the first portion of the duodenum. Using a freehand technique, we advanced a 10-mm × 10-mm AXIOS stent (Boston Scientific, Marlborough, Mass, USA) into the gallbladder, and the stent was successfully deployed, creating a cholecystoduodenostomy. Dark bile, pus, and sludge all drained through the stent (Fig. 3).

Once this was complete, the echoendoscope was pulled back into the stomach. Sonographically, a loop of small bowel was identified that contained the nasobiliary drain (Fig. 4). A large volume of normal saline solution, methylene blue, and contrast mixture was injected through the nasobiliary drain into the small bowel. Once the small bowel was adequately distended, an EUS-guided gastrojejunostomy was performed (Fig. 5). This was done using a freehand technique, and a 15-mm × 10-mm AXIOS stent was used to create the gastroenterostomy. Once the stent was deployed, methylene blue emptied into the stomach, confirming adequate placement (Fig. 6). The entire procedure time was 47 minutes (Video 1, available online at www.giejournal.org).

After the procedure, the patient's pain and nausea improved greatly, and she was soon advanced to a mechanical soft diet and was discharged. In the months after the procedure, the patient had no procedure-related adverse events and did not require any additional hospitalization or interventions for management of cholecystitis or

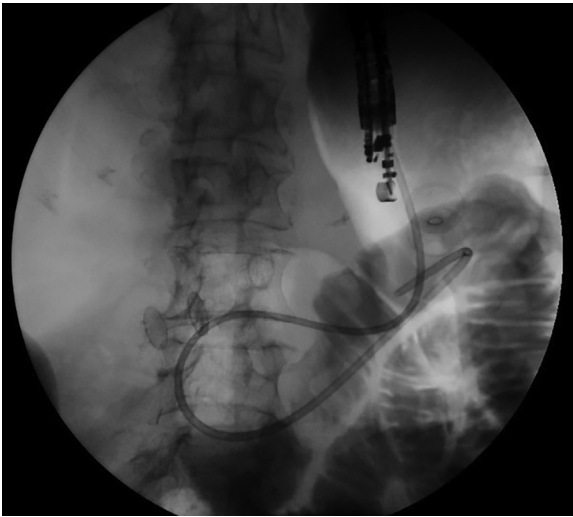


Figure 5. Abdominal radiograph demonstrating successful creation of a gastroenterostomy using a lumen-apposing metal stent.

GOO. She eventually died of her underlying illness 3 months after our procedures.

DISCUSSION

This case demonstrates the effective combination of 2 emerging therapeutic EUS techniques: EUS-GB and EUS-GE. Only a few articles have reported examples in which multiple therapeutic EUS techniques are applied in a single session.^{5,6}

When performing these procedures (especially in sequence), it is important to consider a few points. In our case, we chose to work distally-to-proximally to maintain efficiency and to avoid disrupting lumen-apposing metal stent (LAMS) placement. Specifically, we first placed the nasobiliary drain across the duodenal stenosis in the distal duodenum, then we performed EUS-GB in the duodenal bulb, and finally we performed EUS-GE from the gastric body. Regarding our decision to use a freehand technique for both LAMS placements, in our experience, a guidewire can occasionally push the opposing structure away from the echoendoscope and interfere with LAMS placement. This is particularly important for EUS-GE. Finally, we chose to perform EUS-GB and not EUS-biliary drainage in this case in part because we chose to go after the largest and safest target and because of recent evidence suggesting that EUS-GB can be a management strategy for malignant biliary obstruction.⁷

In patients with advanced malignancy, therapeutic EUS offers an opportunity to provide palliation and symptom improvement in a minimally invasive fashion. Combining techniques in a single session appears to be safe, efficient, and effective for high-risk surgical patients who may otherwise have limited options.

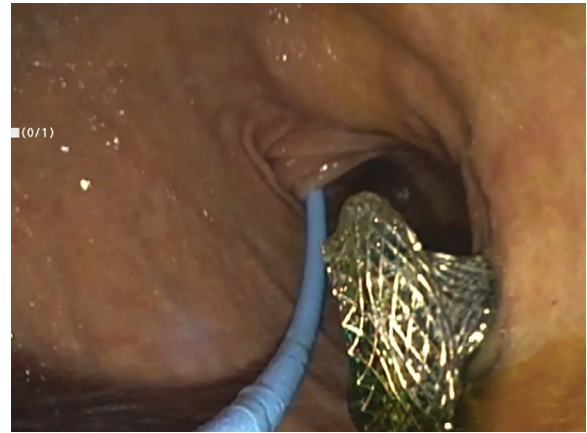


Figure 6. Endoscopic confirmation of gastroenterostomy stent placement as methylene blue rushes into the stomach after placement.

DISCLOSURE

Dr Marya is a consultant for Boston Scientific. All other authors disclosed no financial relationships.

Abbreviations: EUS-GB, endoscopic ultrasound-guided gallbladder drainage; EUS-GE, endoscopic ultrasound-guided gastroenterostomy; GOO, gastric outlet obstruction; LAMS, lumen-apposing metal stent.

REFERENCES

1. Ge PS, Young JY, Dong W, et al. EUS-guided gastroenterostomy versus enteral stent placement for palliation of malignant gastric outlet obstruction. *Surg Endosc* 2019;33:3404-11.
2. Teoh AYB, Kitano M, Itoi T, et al. Endosonography-guided gallbladder drainage versus percutaneous cholecystostomy in very high-risk surgical patients with acute cholecystitis: an international randomised multicentre controlled superiority trial (DRAC 1). *Gut* 2020;69:1085-91.
3. Podboy A, Yuan J, Stave CD, et al. Comparison of EUS-guided endoscopic transpapillary and percutaneous gallbladder drainage for acute cholecystitis: a systematic review with network meta-analysis. *Gastrointest Endosc* 2021;93:797-804.e1.
4. Kouanda A, Binmoeller K, Hamerski C, et al. Endoscopic ultrasound-guided gastroenterostomy versus open surgical gastrojejunostomy: clinical outcomes and cost effectiveness analysis. *Surg Endosc* 2021;35:7058-67.
5. Abidi WM, Thompson CC. Endoscopic choledochoduodenostomy and gastrojejunostomy in the treatment of biliary and duodenal obstruction. *Gastrointest Endosc* 2016;83:1287-8.
6. Platt KD, Bhalla S, Sondhi AR, et al. EUS-guided gastrojejunostomy and hepaticogastrostomy for malignant duodenal and biliary obstruction. *VideoGIE* 2021;6:95-7.
7. Issa D, Irani S, Law R, et al. Endoscopic ultrasound-guided gallbladder drainage as a rescue therapy for unresectable malignant biliary obstruction: a multicenter experience. *Endoscopy* 2021;53:827-31.

Division of Gastroenterology, University of Massachusetts Medical School, Worcester, Massachusetts (1), Department of Medicine, University of Massachusetts Medical School, Worcester, Massachusetts (2).

If you would like to chat with an author of this article, you may contact Dr Marya at Neil.Marya@umassmed.edu.

Copyright © 2022 American Society for Gastrointestinal Endoscopy. Published by Elsevier Inc. This is an open access article under the CC BY-NC-ND license (<http://creativecommons.org/licenses/by-nc-nd/4.0/>).

<https://doi.org/10.1016/j.vgje.2021.10.011>