


# Intra-Articular Tranexamic Acid Injection During the Hip Hemi-Arthroplasty in Elderly Patients: A Retrospective Study

Geriatric Orthopaedic Surgery  
& Rehabilitation  
Volume 9: 1-5  
© The Author(s) 2018  
Article reuse guidelines:  
sagepub.com/journals-permissions  
DOI: 10.1177/2151459318803851  
journals.sagepub.com/home/gos  


Wei Liu, MD<sup>1</sup>, Huangdong Hui, MD<sup>1</sup>, Yunhai Zhang, MD<sup>1</sup>,  
Weilong Lin, MBBS<sup>1</sup>, and Yongqian Fan, MD<sup>1</sup>

## Abstract

**Introduction:** The objective was to evaluate the safety and efficacy of intra-articular injection of tranexamic acid (TXA) in patients between 80 and 100 years of age with femoral neck fracture undergoing hip hemi-arthroplasty (HA). **Material and Methods:** We conducted a retrospective review to assess perioperative blood loss and transfusion rate after intra-articular injection of TXA during HA. This was a single-center, retrospective, single-surgeon, and standard care cohort study covering the period between January and December 2016. One hundred three consecutive patients undergoing HA under spinal or general anesthesia were included. Fifty-four and 49 patients received and did not receive intra-articular injection of TXA during the HA, respectively. After closing the capsule, 50 mL of a TXA solution at a concentration of 1 g/100 mL of saline was injected into joint capsule. We compared the following outcomes: preoperative hemoglobin (HB) level, postoperative day 1 HB level, postoperative day 3 HB level, the net reduction of HB level by postoperative day 3, transfusion rate, and 30- and 90-day postoperative mortality rates. In addition, we use logistic regression to analyze the factors affecting the transfusion rate. **Result:** Day 3 postoperative HB level and the net reduction in HB level within 3 days following surgery were  $93.22 \pm 11.70$  g/L and  $25.98 \pm 6.29$  g/L in TXA group, respectively, while were  $87.10 \pm 10.52$  g/L and  $35.44 \pm 8.61$  g/L in no-TXA group. Transfusion rate was 9% (5/54) in TXA group and 24% (12/49) in no-TXA group, respectively. The differences were statistically significant between the both groups. Logistic regression indicated that the topical administration of TXA would reduce the risk for transfusion, while in male diabetes mellitus would increase the risk. There were no significant differences in the deep venous thrombosis, pulmonary embolism, and mortality rates of 30 and 90 days postoperatively ( $P > .05$ ). **Discussion:** Because of lower systemic absorption and a higher concentration in the wound, topical use of TXA is safer for elderly patients who may have renal or liver dysfunction. TXA at therapeutic concentration does not affect platelet count, platelet aggregation, or coagulation parameters, and is of value in elderly patients who take antiplatelet drug for secondary prevention of cardiovascular diseases. **Conclusion:** For patients between 80 and 100 years of age with femoral neck fracture undergoing HA, intra-articular injection of TXA may reduce the perioperative blood loss and transfusion rate without increasing risk of thrombosis.

## Keywords

elderly, hip hemi-arthroplasty, hemoglobin, intra-articular injection, mortality, transfusion, tranexamic acid

Submitted April 3, 2018. Revised August 20, 2018. Accepted September 9, 2018.

## Introduction

Femoral neck fractures in the elderly patients are associated with high morbidity and mortality.<sup>1</sup> If elderly patients with femoral neck fractures are physically capable, various surgical options are available including internal fixation surgery and hip arthroplasty. The latter is associated with a large volume of blood loss perioperatively and a high blood transfusion rate. The estimated blood loss after hip replacement was reported to be up to 1800 mL,<sup>2,3</sup> with transfusion rates up to 69%.<sup>4,5</sup> Lioudakis et al showed that 26.2% of patients with hemi-arthroplasty

(HA) required intraoperative or postoperative transfusion.<sup>6</sup> For patients between 80 and 100 years of age, hip HA may be the preferred operative procedure due to low function demand and

<sup>1</sup> Department of Orthopaedics, Huadong Hospital Affiliated to Fudan University, Shanghai, China

### Corresponding Author:

Wei Liu, Department of Orthopaedics, Huadong Hospital Affiliated to Fudan University, 221 West Yan An Road, Shanghai, China.  
Email: liuliumsn@sina.com



significant medical comorbidity. To avoid the risk of blood transfusion-related reactions, infections, and heart overload and to lower the length of hospital stay and associated medical costs,<sup>7</sup> it is important for such patients to reduce the blood loss and transfusion volume for clinical and economical considerations.

A considerable amount of research has been conducted to reduce the complications of hip HA. One method involves the use of tranexamic acid (TXA), which is a synthetic derivative of the amino acid, lysine, which produces antifibrinolytic activity by competitively inhibiting lysine binding site on the plasminogen molecule. Tranexamic acid has been used in several orthopedic procedures and has been shown to be safe and effective. Many studies involving TXA injections have reported impressive clinical outcomes in patients undergoing total joint arthroplasty,<sup>8-11</sup> although one study reported disappointing results.<sup>12</sup> Current studies that utilized TXA generally involved intravenous administration of TXA.<sup>8-10</sup> Tranexamic acid can cause uncommon dose-dependent side effects, including nausea, vomiting, diarrhea, headache, orthostatic reaction, blurred vision, and vertigo.<sup>13</sup> According to Tuttle et al, readmission within 30 days with TXA use was higher.<sup>14</sup> Because of the adverse events associated with intravenous administration of TXA, the topical administration of TXA has been studied. Recent studies have shown satisfactory results and the topical administration of TXA appears to be superior to injection of TXA with respect to systemic side effects. Nevertheless, there are few studies involving the topical administration of TXA, even though topical TXA has been shown to be a potentially good agent in patients undergoing joint arthroplasty.<sup>15,16</sup>

The goal of our study was to determine whether the intra-articular injection of TXA reduces perioperative blood loss, the transfusion rate, and the complication rates for patients between 80 and 100 years of age with femoral neck fractures undergoing hip HA.

## Material and Methods

This retrospective study involved qualified patients who underwent hip HA between January and December 2016 in our Orthopedic Department. The study was approved by the Ethics and Research Committee of our institution. Consecutive patients with femoral neck fractures who were scheduled to undergo hip HA were included. The exclusion criteria were as follows: <80 or >100 years of age, revision surgery, internal fixation surgery, delayed surgery, previous thromboembolic events, and receiving anticoagulation therapy. There were 133 patients who underwent hip HA in 2016. Among the 133 patients, 103 fulfilled the inclusion criteria and finished the follow-up and were analyzed. We began to introduce TXA injections during the hip HA since July 2016. There were 54 (53%) patients and 49 (47%) who did and did not receive intra-articular injections of TXA, respectively. All patients underwent surgery within 48 hours of admission. Spinal anesthesia was administered to most of patients; general

anesthesia was administered to those patients who were not candidates for spinal anesthesia, such as patients with low-back pain. One senior surgeon performed all of the surgeries.

## Observation Outcomes

The patient data collected included the following: gender, age, comorbidities, American Society of Anesthesiologists (ASA) grade, anesthetic type, duration of surgery, preoperative hemoglobin (HB) level, intraoperative blood loss, intraoperative complications, postoperative day 1 HB level, postoperative day 3 HB level, net reduction in HB level (the reduction of HB level by postoperative day 3), deep venous thrombosis or pulmonary embolus morbidity, transfusion rate, length of hospital stay, and 30- and 90-day mortality rates. We also recorded the medication taken by the patient simultaneously, some of which influence the coagulation process.

## Surgical Procedure and Perioperative Treatment

A lateral approach was adopted in all surgeries. All patients received preoperative antibiotics within 1 hour of the surgical incision. The operative HA procedure and the prosthesis (Zimmer, Warsaw, Indiana) were identical for all patients. Hemostasis was achieved for major bleedings using electrocautery during the surgery procedure. After closing the capsule of the hip joint, the patients who received TXA were administered a 50-mL intra-articular injection of the TXA solution at a concentration of 1 g/100 mL of saline. No deep drainage system was placed. The wound was closed in a standard fashion. The postoperative therapeutic protocol and rehabilitation were standard and identical in all patients. Beginning on day 1 postoperatively, a standard dose of low-molecular-weight heparin was injected subcutaneously for anticoagulation. Routine blood tests were obtained in the morning on days 1 and 3 after surgery. If the postoperative HB level was <80 g/L, the patient received a blood transfusion to maintain the HB level >80 g/L. A Doppler ultrasound or computed tomography (CT) scan was not regularly performed to detect subclinical deep venous thrombosis or pulmonary embolism. The patient typically remained in the hospital for 5 or 7 days postoperatively until he/she was stable for discharge. As an outpatient, rivaroxaban was administered (10 mg daily) for anticoagulation until 35 days after surgery and regular return visit was required at 1 to 3 months after surgery.

## Statistical Analysis

Data were analyzed with SPSS software (version 21; SPSS, Inc, Chicago, Illinois). Continuous variables are expressed as the mean (standard deviation). An independent-sample *t* test was used to evaluate differences. A  $\chi^2$  test was used to compare categorical data. A *P* value <.05 was considered statistically significant in this study. Logistic regression analysis was used to evaluate risk factors contributing to transfusion.

**Table 1.** Baseline Demographical Characteristic of Patients in Both Groups.

	TXA (n = 54)	No TXA (n = 49)	P Value
Age (years)	84.98 (3.75)	85.38 (4.88)	.30
Gender			.49
Female	39 (72%)	39 (79%)	
Male	15 (28%)	10 (21%)	
Comorbidities			
Hypertension	15 (28%)	17 (34%)	.52
Diabetes mellitus	12 (22%)	11 (22%)	1.00
COPD	10 (18%)	8 (16%)	.80
Medicine			
Aspirin	13 (24%)	10 (20%)	.81
Clopidogrel	2 (4%)	2 (4%)	.65
Anesthetic type			.79
General	9 (16%)	7 (14%)	
Spine	45 (84%)	42 (86%)	
ASA grade			
II	18 (33%)	17 (34%)	.85
III	31 (57%)	26 (53%)	.85
IV	5 (20%)	6 (22%)	.89

Abbreviations: ASA, American Society of Anesthesiologists; COPD, chronic obstructive pulmonary disease; TXA, tranexamic acid.

**Table 2.** Postoperative Comparisons Between Both Groups.

	TXA (n = 54)	No TXA (n = 49)	P Value
Duration of surgery (minutes)	73.05 (10.11)	70.51 (8.61)	.05
Intraoperative blood loss (mL)	119.44 (38.87)	122.24 (47.96)	.74
Intraoperative complication	2/54	3/49	.67
Preoperative HB (g/L)	119.53 (12.78)	122.26 (9.78)	.18
Day 1 postoperative HB (g/L)	103.27 (17.77)	103.28 (9.71)	.99
Day 3 postoperative HB (g/L)	93.22 (11.70)	87.10 (10.52)	.00
Net reduction in HB level (g/L)	25.98 (6.29)	35.81 (9.73)	.00
Transfusion	5/54 (9%)	12/49 (24%)	.03
Ultrasound or CT scan	11/54 (20%)	8/49 (16%)	.60
Length of stay (day)	5.38 (0.56)	5.55 (0.64)	.17
Mortality			
30 days	1 (1%)	1 (2%)	.94
90 days	2 (3%)	1 (2%)	.62

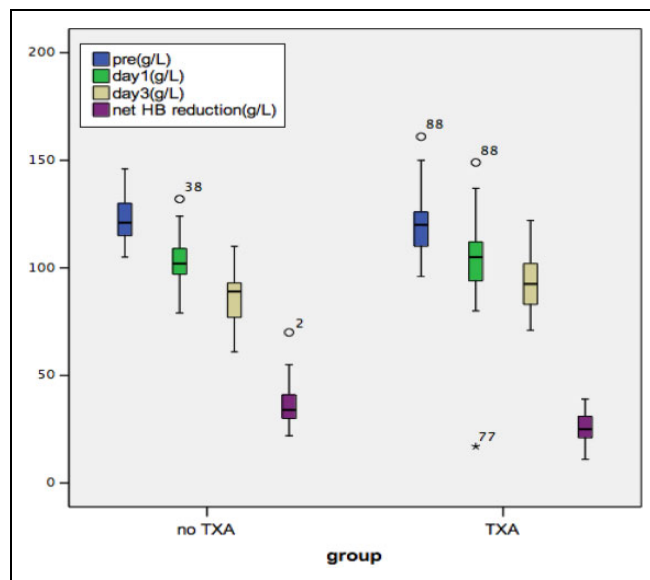
Abbreviations: CT, computed tomography; HB, hemoglobin; TXA, tranexamic acid.

## Results

### Pre- and Postoperative Comparisons Between 2 Groups

There were no significant differences between 2 groups with respect to age, gender, comorbidities, medications, ASA grade, and anesthetic type (Table 1).

There were no significant differences in the preoperative HB level, duration of surgery, intraoperative blood loss, and day 1 postoperative HB level between both groups. There were 5 patients, 2 in TXA and 3 in no-TXA, who suffered minor split fracture in femoral calcar. All implants were stable after cerclage wiring or cables. The difference was not statistically significant (Table 2). For day 3 postoperative HB level and the net reduction in HB level within 3 days following surgery, they were  $93.22 \pm 11.70$  g/L and  $25.98 \pm 6.29$  g/L in TXA group, respectively, while they were  $87.10 \pm 10.52$  g/L and  $35.44 \pm 8.61$  g/L in no-TXA group. The difference was statistically significant between both groups (Figure 1). There were 17 patients totally who received blood transfusion. The transfusion rate was 9% (5/54) in TXA group and 24% (12/49) in no-TXA group. The difference was statistically significant ( $P < .05$ ). There were 19 patients (11 in TXA group and 8 in no-TXA group) who had an ultrasound for suspected deep venous thrombosis; no deep venous thrombosis existed in either group. No patient was suspected to suffer pulmonary embolus and had a CT scan. There were also no statistically significant differences with respect to the length of hospital stay and day 30 and 90 mortality rates ( $P > .05$ ). A total of 3 patients died of lung infection in 2 groups during the follow-up period.



**Figure 1.** Hemoglobin level of preoperative, postoperative day 1, postoperative day 3 HB level, and net HB reduction. HB indicates hemoglobin.

### Logistics Regression Analysis

Transfusion was defined as the dependent variable, and risk factors, including age, duration of surgery, preoperative HB level, intraoperative blood loss, intraoperative complications, group, gender, comorbidities, medicine, ASA grade, were independent variables. The results showed diabetes mellitus, male gender, and intraoperative blood loss were independent risk factors for transfusion, while the TXA

**Table 3.** Logistic Regression Analysis of Variables for Transfusion.

	$\beta$	SE	Wals	P
Gender	-4.04	1.59	6.43	.01
Diabetes mellitus	-3.12	1.58	3.89	.04
Intraoperative blood loss	-0.04	0.01	7.99	.00
Preoperative HB level	0.36	0.11	10.13	.00
Group	4.87	1.61	9.15	.00

Abbreviations: HB, hemoglobin; SE, standard error.

group and high preoperative HB level would reduce the risk for transfusion (Table 3).

## Discussion

A number of studies have supported the safety and efficacy of TXA in total hip arthroplasty (THA).<sup>16-18</sup> Lee et al<sup>19</sup> administered TXA intravenously to patients undergoing HA for femoral neck fractures and reported a lower transfusion rate. Akizuki et al<sup>20</sup> first reported the topical use of TXA in orthopedic surgery in 1997; no postoperative blood transfusions occurred in 106 total knee arthroplasty (TKA) patients. Recently, the topical use of TXA has been shown to be effective in lowering blood loss in total hip and THA<sup>21</sup>; however, controversy exists about the topical use of TXA. Bagsby and Hur<sup>22</sup> and Martin et al<sup>23</sup> reported no differences in transfusion rates with the topical use of TXA in THA and TKA. Our study showed that an intra-articular injection of TXA in patients undergoing hip HA significantly reduced the perioperative bleeding and the risk for transfusion.

Tranexamic acid is excreted largely unchanged in urine and has a circulating half-life of approximately 2 hours<sup>24</sup>; a small amount of the drug is metabolized through the liver. Topical application of TXA leads to 70% lower systemic absorption and a higher concentration in the wound,<sup>25</sup> and it is even safer for older patients who have renal or liver dysfunction. At therapeutic concentrations,<sup>26</sup> TXA does not affect platelet count, platelet aggregation, or coagulation parameters. Tranexamic acid is of value in elderly patients who take aspirin or clopidogrel for secondary prevention of cardiovascular diseases because such antiplatelet drugs influence coagulation.

Although the use of TXA has yielded excellent results<sup>27,28</sup> in THA, and a number of meta-analyses have shown no increase in thromboembolic complications,<sup>29,30</sup> it is still too early to acknowledge the safety of TXA. Most of the available data would likely support TXA's safety in relatively healthy patients rather than those with higher risk. Furthermore, there were proposed contraindications for TXA use, including arterial and venous thrombosis, cerebral thrombosis, myocardial infarct, and acute renal failure. With current evidence, the safety of TXA in patients with higher risk conditions is still uncertain.<sup>31</sup> A case report by Bruce-Brand et al revealed a 65-year-old man with a previously undiagnosed patent foramen ovale who suffered pulmonary emboli and cerebrovascular infarction after

synchronous bilateral TKA, during which TXA was administered intravenously.<sup>32</sup> Nearly all of elderly patients received HA after femoral neck fracture were older than 80 and had several comorbidities simultaneously and were regarded as higher risk to a certain degree. Moreover, the method of applying of TXA in most of current studies has been intravenous; there are still few studies concerning the safety of topical use of TXA. Martin et al<sup>23</sup> reported no clinically significant increase in complications in TXA group. Konig et al<sup>33</sup> reported no thromboembolic complications with topical use of TXA in THA and TKA patients. We also achieved similar results with the topical use of TXA.

The results from our study are promising. As it was a retrospective and small study with a limited number of patients, some limitations need to be further improved. More patients should be included in a future study and randomized controlled trials would be a better way to demonstrate the results. As body mass index (BMI) has been shown to be an important predictor for transfusion for hip arthroplasty, it is necessary to add the BMI data into observation outcomes in further study.

## Conclusion

In our study, we had promising results. Specifically, topical administration of TXA (intra-articular) in hip HA had lower perioperative blood loss and a lower transfusion rate in hip HA for femoral neck fractures in elderly patients between 80 and 100 years of age, and no obvious symptomatic thromboembolic events occurred.

## Declaration of Conflicting Interests

The author(s) declared no potential conflicts of interest with respect to the research, authorship, and/or publication of this article.

## Funding

The author(s) received no financial support for the research, authorship, and/or publication of this article.

## References

1. Handoll HH, Cameron ID, Mak JC, Finnegan TP. Multidisciplinary rehabilitation for older people with hip fractures. *Cochrane Database Syst Rev.* 2009;(4):CD007125.
2. Kubota R, Nozawa M, Matsuda K, et al. Combined preoperative autologous blood donation and intra-operative cell salvage for hip surgery. *J Orthop Surg (Hong Kong).* 2009;17(3):288-290.
3. Smith LK, Williams DH, Langkamer VG. Post-operative blood salvage with autologous retransfusion in primary total hip replacement. *J Bone Joint Surg (Br).* 2007;89(8):1092-1097.
4. Rosencher N, Kerckamp HEM, Macheras G, et al. Orthopedic Surgery Transfusion Hemoglobin European Overview (OSTHEO) study: blood management in elective knee and hip arthroplasty in Europe. *Transfusion (Paris).* 2003;43(4):459-469.
5. Alshryda S, Mason J, Sarda P, et al. Topical (intra-articular) tranexamic acid reduces blood loss and transfusion rates following total hip replacement: a randomized controlled trial (TRANX-H). *J Bone Joint Surg Am.* 2013;95(21):1961-1968.

6. Liodakis E, Antoniou J, Zukor DJ, Huk OL, Epure LM, Bergeron SG. Major complications and transfusion rates after hemiarthroplasty and total hip arthroplasty for femoral neck fractures. *J Arthroplasty*. 2016;31(9):2008-2012.
7. Bierbaum BE, Callaghan JJ, Galante JO, Rubash HE, Tooms RE. An analysis of blood management in patients having a total hip or knee arthroplasty. *J Bone Joint Surg Am*. 1999;81(1):2-10.
8. Alshryda S, Sarda P, Sukeik M, Nargol A, Blenkissopp J, Mason JM. Tranexamic acid in total knee replacement: a systematic review and meta-analysis. *J Bone Joint Surg (Br)*. 2011;93(12):1577-1585.
9. Wind TC, Barfield WR, Moskal JT. The effect of tranexamic acid on transfusion rate in primary total hip arthroplasty. *J Arthroplasty*. 2014;29(2):387-389.
10. Kazemi SM, Mosaffa F, Ejazi A, et al. The effect of tranexamic acid on reducing blood loss in cementless total hip arthroplasty under epidural anesthesia. *Orthopedics*. 2010;33(1):17.
11. Charoencholvanich K, Siri wattanasakul P. Tranexamic acid reduces blood loss and blood transfusion after TKA: a prospective randomized controlled trial. *Clin Orthop Relat Res*. 2011; 469(10):2874-2880.
12. Garneti N, Field J. Bone bleeding during total hip arthroplasty after administration of tranexamic acid. *J Arthroplasty*. 2004; 19(4):488-492.
13. Elwatidy S, Jamjoom Z, Elgamel E, Zakaria A, Turkistani A, El-Dawlatly A. Efficacy and safety of prophylactic large dose of tranexamic acid in spine surgery: a prospective, randomized, double-blind, placebo-controlled study. *Spine*. 2008;33(24): 2577-2580.
14. Tuttle JR, Ritterman SA, Cassidy DB, Anazonwu WA, Froehlich JA, Rubin LE. Cost benefit analysis of topical tranexamic acid in primary total hip and knee arthroplasty. *J Arthroplasty*. 2014; 29(8):1512-1515.
15. Wind TC, Barfield WR, Moskal JT. The effect of tranexamic acid on blood loss and transfusion rate in primary total knee arthroplasty. *J Arthroplasty*. 2013;28(7):1080-1083.
16. Gandhi R, Evans HMK, Mahomed SR, Mahomed NN. Tranexamic acid and the reduction of blood loss in total knee and hip arthroplasty: a meta-analysis. *BMC Res Notes*. 2013;6:184.
17. Ralley FE, Berta D, Binns V, Howard J, Naudie DDR. One intraoperative dose of tranexamic acid for patients having primary hip or knee arthroplasty. *Clin Orthop Relat Res*. 2010;468(7): 1905-1911.
18. Zhou XD, Tao LJ, Li J, Wu LD. Do we really need tranexamic acid in total hip arthroplasty? A meta-analysis of nineteen randomized controlled trials. *Arch Orthop Trauma Surg*. 2013;133(7): 1017-1027.
19. Lee C, Freeman R, Edmondson M, Rogers BA. The efficacy of tranexamic acid in hip hemiarthroplasty: an observational cohort. *Injury*. 2015;46(10):1978-1982.
20. Akizuki S, Yasukawa Y, Takizawa T. A new method of hemostasis for cementless total knee arthroplasty. *Bullin*. 1997;56(4): 222-224.
21. Chang CH, Chang Y, Chen DW, Ueng SWN, Lee MS. Topical tranexamic acid reduces blood loss and transfusion rates associated with primary total hip arthroplasty. *Clin Orthop Relat Res*. 2014;472(5):1552-1557.
22. Bagsby DT, Hur J. Effect of intra-articular injection of tranexamic acid on postoperative hemoglobin in total hip arthroplasty. *Orthopedics*. 2014;37(6):e557-e562.
23. Martin JG, Cassatt KB, Kincaid-Cinnamon KA, Westendorf DS, Garton AS, Lemke JH. Topical administration of tranexamic acid in primary total hip and total knee arthroplasty. *J Arthroplasty*. 2014;29(5):889-894.
24. Pfizer. Cyklokapron (tranexamic acid) injection [package insert]. 2008. <http://www.pfizer.com/products/rx/prescription.jsp>. Accessed April 18, 2011.
25. Wong J, Abrishami A, El Beheiry H, et al. Topical application of tranexamic acid reduces postoperative blood loss in total knee arthroplasty: a randomized, controlled trial. *J Bone Joint Surg Am*. 2010;92(15):2503-2513.
26. Gillette BP, DeSimone LJ, Trousdale TR, Pagnano MW, Sierra RJ. Low risk of thromboembolic complications with tranexamic acid after primary total hip and knee arthroplasty. *Clin Orthop Relat Res*. 2013;471(1):150-154.
27. Zufferey PJ, Miquet M, Quenet S, et al. Tranexamic acid in hip fracture surgery: a randomized controlled trial. *Br J Anaesth*. 2010;104(1):23-30.
28. Vijay BS, Bedi V, Mitra S, Das B. Role of tranexamic acid in reducing postoperative blood loss and transfusion requirement in patients undergoing hip and femoral surgeries. *Saudi J Anaesth*. 2013;7(1):29-32.
29. Ker K, Edwards P, Perel P, Shakur H, Roberts I. Effect of tranexamic acid on surgical bleeding systematic review and cumulative meta-analysis. *BMJ*. 2012;344:e3054.
30. Sukeik M, Alshryda S, Haddad FS, Mason JM. Systematic review and meta-analysis of the use of tranexamic acid in total hip replacement. *J Bone Jt Surg Br*. 2011;93(1):39-46.
31. Fu DJ, Chen C, Guo L, Yang L. Use of intravenous tranexamic acid in total knee arthroplasty: a meta-analysis of randomized controlled trials. *Chin J Traumatol*. 2013;16(2):67-76.
32. Bruce-Brand R, Dragomir R, Baker J, Harty J. Cerebrovascular infarction following bilateral total knee arthroplasty and tranexamic acid administration. *Acta Orthop Belg*. 2013;79(3): 351-354.
33. Konig G, Hamlin BR, Waters JH. Topical tranexamic acid reduces blood loss and transfusion rates in total hip and total knee arthroplasty. *J Arthroplasty*. 2013;28(9):1473-1476.