



Case report

Descemet Membrane Endothelial Keratoplasty - Complication and management of a single case for tissue preparation and graft size linked to post-op descemetorhexis disparity

Mohit Parekh^{a,b}, Alessandro Ruzza^b, Abigail Kaye^c, Bernhard Steger^d, Stephen B. Kaye^{c,e}, Vito Romano^{c,e,*}

^a UCL Institute of Ophthalmology, London, United Kingdom

^b International Center for Ocular Physiopathology, The Veneto Eye Bank Foundation, Venice, Italy

^c Department of Ophthalmology, St. Paul's Eye Unit, Royal Liverpool University Hospital, Liverpool, United Kingdom

^d Department of Ophthalmology, Medical University of Innsbruck, Innsbruck, Austria

^e Department of Eye and Vision Science, University of Liverpool, Liverpool, United Kingdom

ARTICLE INFO

Keywords:

Endothelial keratoplasty
DMEK

ABSTRACT

Purpose: To report the management of an intraoperative complication during large (9.5 mm) ultra-thin Descemet Stripping Automated Endothelial Keratoplasty (UT-DSAEK) surgery in a patient with a large area of dysfunctional endothelium.

Observations: A single case study of an 89 y/o male with a history of Fuchs corneal endothelial dystrophy is presented. The patient was listed for a large UT-DSAEK, but due to an intraoperative complication during graft preparation, an 8.00 mm Descemet membrane endothelial keratoplasty (DMEK) was prepared from the same graft using a standardized SCUBA technique and delivered. Early postoperative examination of the graft showed decentred, residual corneal oedema in the absence of DM detachment and a well-formed anterior chamber. The endothelial graft was found attached after 3 months and the corneal oedema was cleared. After 5 months, the patient's BSCVA was recorded at 6/6(20/20) in the left eye, but complained of mild discomfort. A circular ring of corneal oedema was observed around the graft and decentralization of the transplanted graft was observed. Endothelial cell density (ECD) of the central cornea at 5th month was 1506 cells/mm² at a focal depth of 496 μm with some polymegathism.

Conclusions: and importance: It is possible to prepare DMEK starting from a failed DSAEK graft. Thickness map on corneal tomography could be a useful tool after DMEK for checking graft centration, function, and corneal recovery indirectly. It is recommended to only maintain a small distance between the descemetorhexis area and the size of the endothelial graft.

1. Introduction

Endothelial Keratoplasty (EK), especially Descemet Stripping Automated Endothelial Keratoplasty (DSAEK) has become a gold standard for keratoplasty procedures.¹ However, with advancements seen since the last decade, Descemet Membrane Endothelial Keratoplasty (DMEK) has also been a front-runner for treating EK cases, with advantages that include better visual recovery and early rehabilitation rates compared to penetrating keratoplasty (PK).^{2–4} DSAEK graft preparation methods are already standardized with the use of a microkeratome. Whereas DMEK is still being standardized due to the technical challenges that are observed during graft preparation and

implantation. A DMEK graft is usually prepared from a PK tissue.

We report a case where the patient was deemed suitable for Ultra Thin (UT-DSAEK) but due to the preparation of a non-uniform graft after microkeratome cutting with poor stromal bed, the tissue was further stripped from an UT-DSAEK graft and transplanted as a DMEK graft. We have also noted that matching the size of descemetorhexis with the graft size is important in order to avoid peripheral stromal edema and reduce the detachment rate. Thus, the aim of this single case report is to show that a DMEK graft can be prepared even after a failed DSAEK preparation further reducing possible wastage of tissue.

* Corresponding author. Department of Corneal and External Eye Diseases, St. Paul's Eye Unit, Royal Liverpool University Hospital, Liverpool, United Kingdom.
E-mail address: vito.romano@gmail.com (V. Romano).

<https://doi.org/10.1016/j.ajoc.2018.09.003>

Received 17 April 2018; Received in revised form 29 August 2018; Accepted 4 September 2018

Available online 06 September 2018

2451-9936/ © 2018 The Authors. Published by Elsevier Inc. This is an open access article under the CC BY license (<http://creativecommons.org/licenses/by/4.0/>).

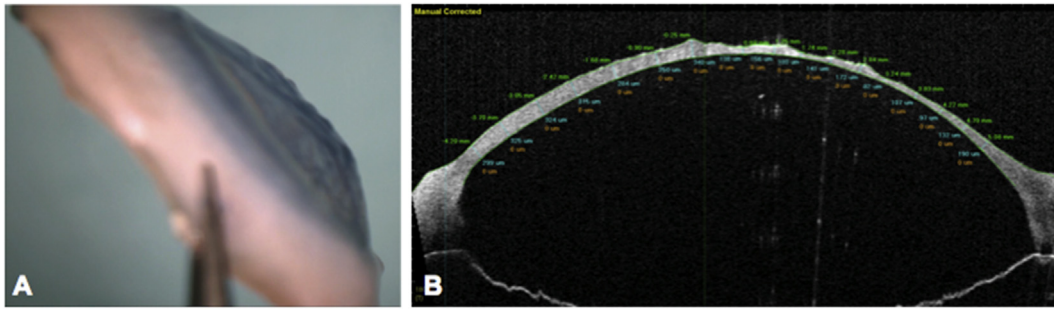


Fig. 1. A) Donor cornea and B) OCT image - showing irregular stromal surface due to loss of vacuum during UT-DSAEK preparation.

2. Case report

An 89-year-old man with a history of Fuchs corneal endothelial dystrophy presented in the left eye with reduced visual acuity and discomfort due to the development of pseudophakic corneal edema following previous uneventful cataract surgery in 2005. The best spectacle corrected distance visual acuity (BSCVA) was 6/18 (20/63) in the right eye and 6/24(20/80) in the left eye. Intraocular pressure was 12 mmHg in both the eyes with central corneal thickness in the left eye of 658 microns, measured using ultrasound pachymeter. The guttae and resulting endothelial dysfunction involved most of the endothelial surface, therefore, a large (9.5 mm) ultra-thin Descemet stripping automated endothelial keratoplasty (UT-DSAEK) was planned. The graft was prepared following our previously published protocol.^{5,6} However, due to loss of vacuum on the Barron trephine during cutting resulted in an irregular stromal surface (Fig. 1A), which was verified using anterior segment optical coherence tomography (AS-OCT) (SS-1000 Casia; Tomey Corporation, Nagoya, Japan) (Fig. 1B). In order to reduce the corneal wastage, a Descemet membrane endothelial keratoplasty (DMEK) was performed in his left eye using an 8.00 mm donor graft (prepared using SCUBA technique, video 1) placed within a recipient descemetorhexis of about 9.5 mm. Delivery and unfolding of the tissue was achieved without intraoperative complications. Topical prednisolone acetate 1% (Pred Forte, Allergan) and chloramphenicol 0.5% eye drops (chloramphenicol) four times a day were used post-operatively. An early postoperative examination of the graft showed it to be slightly temporally decentred, residual corneal edema in the absence of DM detachment and a well-formed anterior chamber. However, the endothelial graft remained attached and the corneal edema had cleared. After 3 months, AS-OCT (SS-1000 Casia; Tomey Corporation, Nagoya, Japan) confirmed that the graft was completely attached. After 5 months, the patient's BSCVA was recorded at 6/6(20/20) in the left eye, but with complain of mild discomfort. His left cornea was clear in the centre, but it showed a circular ring of corneal edema around the graft (Fig. 2A and B) evident on corneal tomography (Pentacam, Oculus, Germany). Corneal map (Fig. 2C) and AS-OCT (Fig. 2D) for thickness measurement showed decentralization of the transplanted graft with edema observed in the corneal map (Fig. 2C). Endothelial cell density (ECD) of the central cornea assessed using *in vivo* confocal microscopy (IVCM, Heidelberg Retina Tomographer II with Rostock Cornea Module; Heidelberg Engineering, Heidelberg, Germany) 5 months after surgery was 1506 cells/mm² at a focal depth of 496 μ m with some polymegathism.

Supplementary video related to this article can be found at <https://doi.org/10.1016/j.ajoc.2018.09.003>.

3. Discussion

This case report highlights some interesting points. It is possible to prepare a DMEK lenticule starting from a posterior lamellar graft (DSAEK). In cases of irregular donor surfaces it is still a valid and achievable option. A multimodal approach AS-OCT and the thickness

map on corneal tomography are useful tools after DMEK for indirectly checking graft centration, function, attachment, and corneal recovery. Melles et al. have previously reported the utility of corneal tomography in the follow-up to highlight early signs of rejection after DMEK.⁷ The size of descemetorhexis in DMEK should be slightly smaller compared to the diameter of the graft. It should be noted, that graft diameter or chord length in the eye differs from the diameter of the graft on the trephine block.⁸ This difference depends on the disparity between the radius of curvature of the trephine and that of the posterior cornea. The radius of curvature can be 9.5 mm (Hessburg-Barron trephine block), 7.5 mm (Moria trephine block) or 7.7 mm (Janach trephine block). The circumferential arc length of the trephined graft is the product of the trephine size (Y) and angle (radians). For example, for a trephine size of 8.0 mm on a trephine base of radius R_1 of 9.5 mm, the circumferential arc length is $9.5\text{mm} \times \alpha_1$, where α_1 can be calculated from the function, $\alpha_1 = 2\text{Arcsin}(Y_1/2R_1)$. Therefore, for an 8.00 mm sized graft, $\alpha_1 = 2\text{Asin}(4.00/2 \times 9.5)$ or 1.05 radians or 60°, giving a circumferential arc length C of 8.25 mm. If the graft assumes a radius of curvature on the posterior corneal surface R_2 in the eye of 5.70 mm, then $\alpha_2 = (C/R_2)$ or 1.75 radians or 100°. The expected chord length (Y_2) of the graft in the eye is therefore $Y_2 = 2(5.7) \sin 50^\circ$ or 7.75 mm. Therefore, for a 8 mm donor DMEK preparation we will have a smaller graft size of 7.75 mm in the eye using Barron, 7.9 mm using Moria, 7.88 mm using Janach. There is always an under sizing of the graft compared to the trephine used. This under sizing increases with larger diameter graft. Migration of endothelial cells to cover the gap between the edge of the graft and host Descemet's membrane and endothelium may not be a consistent event and in this case by 5 months, appeared insufficient to have bridged the circumferential gap of 1.75mm (9.5mm - 7.75mm).⁹ On the basis of better graft survival following larger grafts in DSAEK and knowing that the technical difficulties of manipulating a larger graft can be overcome,¹⁰ we would suggest using larger endothelial grafts with a donor trephine size of 9 mm or 9.5 mm.⁸ Since there are many factors that contribute to endothelial graft failure, the health of the donor endothelium is likely to be pivotal. It is reasonable to suggest, therefore, that transplanting larger grafts and replacing a larger proportion of diseased endothelial cells may lead to improved graft survival. Although this is just a single case observation, it reveals that it is possible to prepare a DMEK graft from an UT-DSAEK donor and that there may be a certain limitation of the donor endothelial cells to recover the exposed stromal area, it would however be beneficial to increase the size of the graft if the endothelial dysfunction affects a large area. The gap between a DMEK graft and the recipient periphery should be minimal to reduce the risk of peripheral corneal oedema.

Patient consent statement

The corneas were harvested by Fondazione Banca degli Occhi del Veneto Onlus for transplantation purpose after obtaining a written consent from the donor's next-of-kin.

A written consent from the patient was obtained before transplantation.

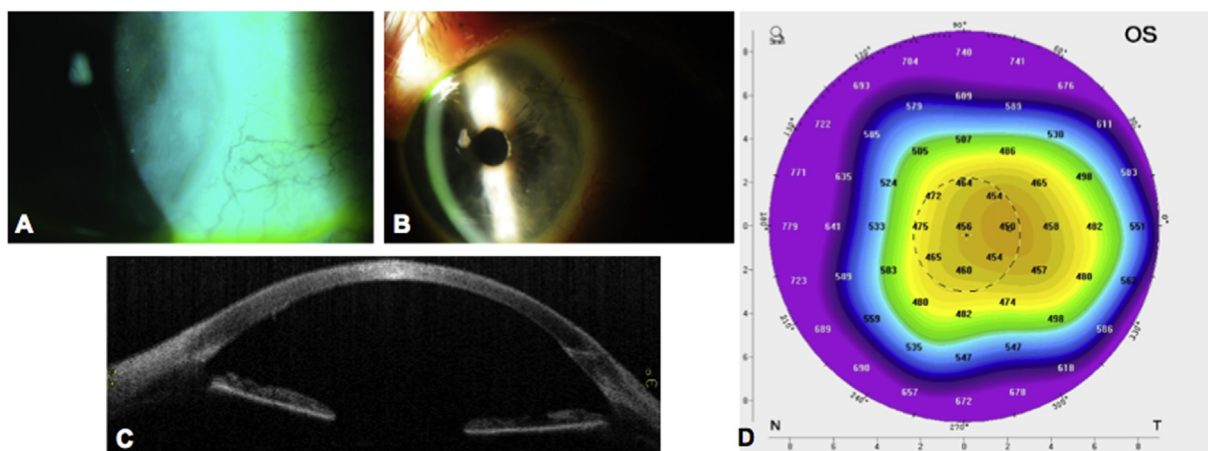


Fig. 2. A and B) Left eye of the patient showing circular corneal oedema all around the corneal graft, C) OCT image of the cornea with decentered DMEK graft and D) Thickness map showing decentered DMEK graft and increased corneal thickness of the exposed or bare stroma without the DMEK graft or endothelial cells compared to the central region.

Funding statement

None of the authors have any financial interest.

Conflicts of interest

None of the authors have any conflict of interest.

Authorship statement

All authors attest that they meet the current ICMJE criteria for authorship.

MP, AR, SK, VR - Substantial contributions to the conception or design of the work; or the acquisition, analysis, or interpretation of data for the work; AND.

MP, AK, BS, VR - Drafting the work or revising it critically for important intellectual content; AND.

MP, AR, AK, BS, SK, VR - Final approval of the version to be published; AND.

MP, AR, AK, BS, SK, VR - Agreement to be accountable for all aspects of the work in ensuring that questions related to the accuracy or integrity of any part of the work are appropriately investigated and resolved.

Acknowledgements

None.

References

1. Gorovoy MS. Descemet-stripping automated endothelial keratoplasty. *Cornea*. 2006;25:886–889.
2. Price Jr FW, Price MO. Descemet's stripping with endothelial keratoplasty in 200 eyes: early challenges and techniques to enhance donor adherence. *J Cataract Refract Surg*. 2006;32:411–418.
3. Melles GR, Ong TS, Ververs B, van der Wees J. Descemet membrane endothelial keratoplasty (DMEK). *Cornea*. 2006;25:987–990.
4. Melles GR. Posterior lamellar keratoplasty: DLEK to DSEK to DMEK. *Cornea*. 2006;25:879–881.
5. Romano V, Steger B, Chen JY, et al. Reliability of the effect of artificial anterior chamber pressure and corneal drying on corneal graft thickness. *Cornea*. 2015;34:866–869.
6. Romano V, Steger B, Myneni J, Batterbury M, Willoughby CE, Kaye SB. Preparation of ultrathin grafts for Descemet-stripping endothelial keratoplasty with a single microkeratome pass. *J Cataract Refract Surg*. 2017;43:12–15.
7. Moutsouris K, Dapena I, Ham L, Balachandran C, Oellerich S, Melles GR. Optical coherence tomography, Scheimpflug imaging, and slit-lamp biomicroscopy in the early detection of graft detachment after Descemet membrane endothelial keratoplasty. *Cornea*. 2011;30:1369–1375.
8. Romano V, Tey A, Hill NM, et al. Influence of graft size on graft survival following Descemet stripping automated endothelial keratoplasty. *Br J Ophthalmol*. 2015;99:784–788.
9. Lavy I, Verdijk RM, Bruinsma M, et al. Sex chromosome analysis of postmortem corneal endothelium after sex-mismatch Descemet membrane endothelial keratoplasty. *Cornea*. 2017;36:11–16.
10. Parekh M, Ruzza A, Ferrari S, et al. Endothelium-in versus endothelium-out for Descemet membrane endothelial keratoplasty graft preparation and implantation. *Acta Ophthalmol*. 2017;95:194–198.