

Severe aortic regurgitation complicating Takayasu's arteritis

Wala M. Alali, MD, Saeed A. Alahmari, FACC, FESC, Yahya S. Albebaishi, MD, Seham A. Alrashidi, MD.

ABSTRACT

نستعرض هنا حالة غير شائعة لأنثى تبلغ من العمر 48 عاماً تعاني من أعراض شديده لقلس الأبهر مع تمدد الأوعية الدموية للشريان الأورطي الصاعد وضيق التنفس التدريجي. أظهرت الاختبارات المعملية والتصوير التهاب الشرايين تكاياسو كسبب كامن. كما كشف مسح التصوير المقطعي الكامل انسداد الشريان السباتي الأيمن وكذلك تضيق في أصل الشرايين تحت الترقوة والفقري الأيسر. وبالإضافة إلى ذلك، أظهر الرنين المغناطيسي للقلب أوعية دموية في الجزء القريب من الشريان تحت الترقوة. التدخل بالكورتيكوستيرويدات قلل بشكل فعال الحاجة إلى العلاج الجراحي. الأطباء يجب دائماً النظر في التشخيص التفريقي TA في النتائج السريرية غير نمطية الموجودة لجميع المرضى الذين يعانون مشاكل خاصة في القلب وخاصة عندما يكون هنالك مشاركة صمام.

We present an uncommon case of a 48-year-old female patient with symptomatic presentation of a severe aortic regurgitation with aneurysm of the ascending aorta and progressive dyspnea. Detailed investigation of laboratory tests and imaging identified Takayasu's arteritis (TA) as the underlying etiology. Computed tomography scan revealed complete occlusion of the right carotid artery as well as stenosis at the origins of left subclavian and vertebral arteries. In addition, cardiac magnetic resonance angiogram showed aneurysm at the proximal segment of right subclavian artery. Intervention with corticosteroids effectively diminished the need for immediate surgical intervention. Treating physicians should always consider differential diagnosis of TA in the presence of atypical clinical findings in all patients with cardiac problems especially when there is valve involvement.

Saudi Med J 2017; Vol. 38 (8): 863-867
doi: 10.15537/smj.2017.8.12473

From the Department of Internal Medicine (Alali), the Department of Rheumatology (Alrashidi), Prince Sultan Military Medical City, and the Department of Cardiology (Alahmari, Albebaishi), Prince Sultan Cardiac Center, Riyadh, Kingdom of Saudi Arabia.

Received 12th March 2017. Accepted 22nd June 2017.

Address correspondence and reprint request to: Dr. Wala M. Alali, Department of Internal Medicine, Prince Sultan Military Medical City, Riyadh, Kingdom of Saudi Arabia. E-mail: wala.alali@hotmail.com

Takayasu's arteritis (TA) is a rare chronic large-vessel vasculitis, affecting mainly the aorta and its proximal branches.¹ Women under the age of 40 years are predominantly affected by TA with the highest prevalence reported in East Asia, especially Japan and Korea.¹ Takayasu's arteritis may cause aortic stenosis, aortic aneurysm and to a much lesser frequency aortic regurgitation (AR). The diagnosis of TA is based on clinical findings, relevant serological tests, and imaging studies. Prognosis is dependent mainly on the disease activity and complications with cardiac involvement.¹ Immunosuppressive therapy is the mainstay of TA management. Normally corticosteroids are used to induce remission followed by the introduction of steroid sparing drugs. Some severe cases may require surgical repair, but complications commonly occur due to the fragility of the valves because of the inflammation. Therefore, to improve the success rate of repair, surgical intervention is often best deferred until the inflammation has become well under control.² We report here an atypical case of severe AR with aortic aneurysms a complication of TA to further increase awareness of the broad spectrum of TA presentation and varied ethnicity.

Case Report. Patient information. We present the case of a 48-year-old female patient from the southern part of Saudi Arabia, diagnosed 2 years earlier with dilated cardiomyopathy (DCM) and severe AR. She presented acutely with intractable cough, worsening of breathlessness on exertion along with orthopnea and occasional paroxysmal nocturnal dyspnea. Her New York Heart Association (NYHA) HF classification progressed from class II at the time of the diagnosis 2 years ago to class IV on her latest presentation.

She reported few self-limited episodes of hemoptysis. She had no chest pain, palpitations or attacks of syncope. She reported fatigue, dizziness, weight loss, multiple first and second trimester abortions. In the most recent presentation, she reported recurring claudication of the upper limbs with previous history of painless bluish discoloration of left leg.

Clinical findings. The patient was hypertensive and reported difficulty with measuring her blood pressure in the left arm. Clinical examination revealed a heart rate of 105/min, regular and collapsing. Radial pulse of left arm was feeble and of normal volume in the right arm. The blood pressure was recorded as 90/50 mmHg in the left arm and 130/53 mmHg in the right arm. On auscultation, there was an early ejection murmur at the left costal margin consistent with AR. A bruit was heard over both carotid and the left subclavian artery. Angio-arteriography showed complete right carotid stenosis and less than 50% stenosis of the left carotid artery (Figure 1). Both left vertebral and subclavian arteries had segmental stenosis at the respective origins (Figure 2). There were no signs of weakness in the upper limbs noted, while the lower limbs exhibited post-inflammatory hypopigmented erythema nodosum like rash.

Timeline. Laboratory and serology test results demonstrated: white blood cells count (WBC) of $4.3 \times 10^9/L$, hemoglobin: 11.6 g/dl, platelets: 308, erythrocyte sedimentation rate (ESR): 42 mm/hour and a C-reactive protein (CRP) of 18 mg/L. The liver function tests, urea, creatinine, serum sodium and potassium were all within the normal range. The anti-nuclear antibodies (ANA) titer was 1/80 but the other auto antibodies tested, namely the anti-danti-double stranded DNA, cytoplasmic antineutrophil cytoplasmic antibodies, and perinuclear anti-neutrophil cytoplasmic antibodies did not show any rise in their respective titers. The imaging results of the CT scan revealed an old ischemic insult in the left basal ganglia. The echocardiogram exhibited 25% ejection fraction (EF), tricuspid aortic valve, mildly thickened leaflets, malcoapting cusps, opening well, and dilated aortic root. The angiography result was consistent with complete right side carotid stenosis, less than 50% stenosis in the left carotid, vertebral and subclavian arteries which had segmental stenosis at the origins. The renal magnetic resonance angiogram (MRA) showed dilation of infra and supra renal aorta (Table 1).

Diagnostic assessment. Following the cardiac MRA which showed right subclavian aneurysm, the patient was diagnosed with TA. She exhibited 5 out of the 6 major clinical diagnostic criteria developed for TA classification.¹

Disclosure. Authors have no conflict of interests, and the work was not supported or funded by any drug company.

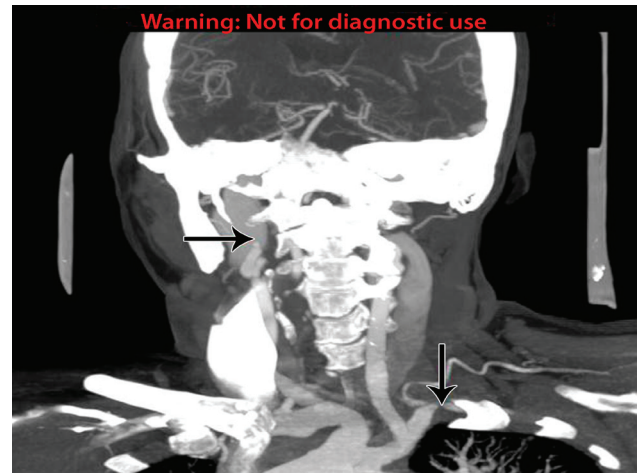


Figure 1 - Complete occlusion of the right internal carotid artery and irregular outline of left subclavian artery with narrowed segment.

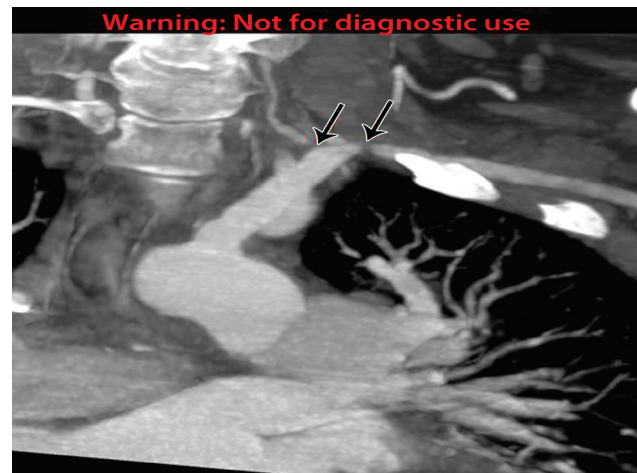

Figure 2 - Severe narrowing at the origin of left vertebral artery. Segmental stenosis of the left subclavian artery is noted.

Therapeutic intervention. Due to the fragile and inflamed vascular tissues, the planned aortic and mitral valve replacement surgery was postponed and immunosuppressive treatment initiated promptly. She was commenced on pulse therapy with 500 mg dose of methyl prednisolone daily for 3 days followed by 60 mg of oral prednisolone for 4 weeks. The dosage of prednisolone was tapered down by 5 mg weekly until reached the maintenance dose of 5 mg a day. She was also given regular low dose aspirin (81 mg).

Follow-up and outcomes. She improved clinically in response to the above measures. She reported minimum claudications and dyspnea during the follow up. The

Table 1 - Time line including follow up visits diagnostic tests and interventions.

Dates	Relevant past medical history and intervention		
25 February 2015	48-year-old female patient diagnosed with dilated cardiomyopathy (DCM) and severe aortic regurgitation (King Fahad Hospital, Riyadh, Saudi Arabia) with New York Heart Association (NYHA) HF: class II, presented to Prince Sultan Cardiac Center, Riyadh, Saudi Arabia.		
	Summaries from initial and follow up visits	Diagnostic testing	Intervention
6-9 March 2015	<p><u>Patient concerns:</u> acute intractable cough, worsening of breathlessness on exertion orthopnea & paroxysmal nocturnal dyspnea.</p> <p><u>Clinical assessment:</u> NYHA HF: class IV heart rate was 105/min, blood pressure 90/50 mmHg in the left arm, 130/53 mmHg in the right arm.</p> <p>Early ejection murmur at the left costal margin. Angio-arteriography: right carotid stenosis, <50% stenosis of left carotid artery. Lower limbs: post-inflammatory hypopigmented erythema nodosum like rash.</p>	<p>Blood test: CRP, ESR, liver function tests, urea, creatinine, serum sodium, potassium, ANA, anti-ds DNA, c-ANCA, p-ANCA, CBC, U/E</p> <p>Imaging: CT scan, cardiac MRI, Echo, angiography, MRA</p>	On attendance patient was taking aspirin, prednisolone and methotrexate 12.5 mg per os
March 2015	<p><u>Laboratory test results:</u> WBC: 4.3 10⁹/L, hemoglobin: 11.6 g/dl, platelets: 308, ESR: 42 mm/hour, CRP: 18 mg/L.</p> <p><u>Normal range:</u> Liver function tests, urea, creatinine, serum sodium and potassium, ANA titer was 1/80, other auto antibodies titer no change</p> <p><u>Imaging test results:</u> CT scan: Old ischemic insult in the left basal ganglia, Echo: 25% EF, tricuspid aortic valve, mildly thickened leaflets, malcoapting cusps, opening well and dilated aortic root, Angiography: Complete right side carotid stenosis, less than 50% stenosis in the left carotid, vertebral and subclavian arteries Renal MRA: dilation of infra and supra renal aorta</p>		
March 2015	<p><u>Cardiac MRA results:</u> Right subclavian aneurysm</p> <p><u>Diagnosis:</u> Takayasu's arteritis</p>	None	<p><u>Initial intervention:</u> Start on pulse therapy, regular low dose aspirin daily (81 mg) 500 mg, methyl prednisolone per day for 3 days, 60 mg of oral prednisolone for 4 weeks, reduced 500 mg of methyl prednisolone by 5 mg weekly Maintenance dose of methyl prednisolone 5mg per day, Adactone 25mg per os, concor 2.5 mg daily, candesartan 16 mg per os daily</p>
November 2015			
7 September 2017	<p>AVR (tissue), MVR (tissue) Tricuspid valve repair. Clinical improvement with reported minimum claudication and dyspnea CRP was less than 1 and the ESR was 5 mm/hour. The EF was 55%.</p>	<p>Blood test: CRP, ESR, and EF</p>	
<p>EF - ejection fraction, HF - heart failure, WBC - white blood cells count, CRP - C-reactive protein, and ESR -erythrocyte sedimentation rate, ANA - anti-nuclear antibodies, anti-ds DNA - anti-double stranded DNA, c-ANCA - cytoplasmic anti neutrophilic antibody , p-ANCA - perinuclear antineutrophilic cytoplasmic antibody, CBC - complete blood count, U/E - urea and electrolytes, Echo - echocardiogram, MRA - magnetic resonance angiogram, AVR - aortic valve replacement, MVR - Mitral valve replacement</p>			

CRP was less than 1 and the ESR was 5 mm/h. The EF was 55% (Table 1).

Discussion. Takayasu's arteritis often referred to as the "pulseless disease" is a chronic disease with variable severity and clinical manifestations, progression of which may cause damage to the arterial walls resulting in adverse outcomes such as rupture of the arteries.³ Such vascular complications in untreated patients with TA are the leading causes of morbidity and mortality.³ Initiating aggressive treatment for severe cases improves outcomes with a reportedly close to 90% 5-year survival rates.⁴ The diagnosis of TA is often made later when complications become evident posing a formidable challenge for early management and treatment of the disease. The difficulty for accurate TA diagnosis is compounded by the lack of specific diagnostic serologic tests; traditional biomarkers such as CRP and ESR levels are indicative of clinical inflammation but not all cases of active TA disease present with changes in ESR and CRP levels.^{5,6} Therefore, high index of suspicion is warranted in patients presenting with angina without any other identifiable risk factors or young adults diagnosed with hypertension and arterial bruits.

We have reported an uncommon case of a middle-aged female patient presenting with severe AR associated with aortic aneurysm as a secondary complication of TA. The carotid, subclavian, and vertebral arteries were all involved. The clinical diagnosis of TA in this patient was only established following the AR symptomatic presentation. The definitive diagnosis of TA was supported by the above findings together with the asymmetrical arm blood pressures, claudication symptoms, hypertension and the classical radiological changes. Over the past decade, the time frame from disease onset to clinical diagnosis has gradually diminished thanks to the advent in improved imaging modalities and medical treatment options. The classical characteristics of TA were not apparent in our patient at the time of diagnosis with AR and DCM. However, at later presentation the clinical features of TA were salient and it is plausible that a flare up was the reason for the worsening of her cardiac condition and the appearance of the diagnostic TA indications. Although the patient was diagnosed with TA at a relatively later stage, the condition; however, was amenable to immunosuppressive therapy and symptoms improved adequately to allow for the postponement of the surgical intervention. Despite improvement following surgery, valve detachment after anastomotic aneurysm may still occur due to the fragility of aortic wall or annular tissue because of TA.⁴ Previous studies^{5,7} found

that immunosuppressive agents achieved remission in patients with TA anywhere from 46% to 84% success rate. Similarly, early medical intervention for TA management prior to surgery even with complication of severe forms of AR has been further demonstrated with implementation of effective treatment using newer biological agents.⁶ Surgical intervention with valve or root replacement in patients with active disease can be very challenging and carries high complications rate due to the fragility of the inflamed tissue, which may lead to valve detachment or anastomotic aneurysm formation. Surgical intervention is therefore best delayed for the vascular inflammation to be sufficiently treated with immunosuppressive therapy.

Aortic valve regurgitation has been reported as a complication of up to 25% of TA cases.^{8,9} However, AR associated with aneurysm of the ascending aorta is a relatively rare complication of TA with few cases published in more than 3 decades.^{6,9} The clinical presentation, treatment approaches and outcomes have been variable in these case reports with the differences primarily due to the changes in treatment modalities. It is now generally accepted to only consider surgical intervention after the medical therapy is instigated in order to reduce inflammation to manageable levels.⁵ McGraw et al⁹ also suggested a delay in the surgical intervention was deemed necessary as it complicated the need to manipulate the inflamed tissue leading to worsening of the outcome such as valve detachment or dilatation of the residual aorta. Previously, Matsuura et al⁸ reviewed the late outcome of surgical treatment for aortic valve regurgitation due to TA and its relation with inflammation over 24 years in 90 patients and found an overall survival rate of 76.1% after 15 years follow up. The authors findings further showed presence of active inflammation in 10 pathological specimens 4 of which showed detachment of the valve or graft confirming that active inflammation is a major risk factor for detachment.⁸

Previous studies have reported significantly increased survival rates following aortic valve replacement in patients with AR complication secondary to TA condition.^{4,10} Kaku et al⁴ review of cardiac operations over 30 years in 20 patients with AR associated with TA revealed a 5-year survival rate of 90.9% after surgery with no case of valve or composite graft detachment evident.⁴ In our findings, 2 patients required a repeat of aortic root replacement while 2 other patients developed late dilatation of the residual thoraco-abdominal aorta.⁴ Similarly, Li et al¹⁰ found satisfactory outcomes with no case of valve detachment in patients with TA and surgical treatment of AR.¹⁰ Despite the rare association

of AR with TA, physicians should be alert to the possible diagnosis of TA given the high incidence of coronary artery diseases among these patients.

In conclusion, this case demonstrates a rare presentation of severe AR with aortic aneurysm secondary to TA in a middle-aged female patient of Arabian origin. High index of suspicion is necessary for early diagnosis of patients with TA to reduce or prevent further complications and adverse outcomes. The immunosuppressive therapy has proven as an effective perioperative measure in this case study and may benefit other patients with established cardiac complications by reducing or delaying the need for surgical intervention.

References

1. de Souza AW, de Carvalho JF. Diagnostic and classification criteria of Takayasu arteritis. *J Autoimmun* 2014; 48: 79-83.
2. Keser G, Direskeneli H, Aksu K. Management of Takayasu arteritis: a systematic review. *Rheumatology (Oxford)* 2014; 53: 793-801.
3. Numano F, Okawara M, Inomata H, Kobayashi Y. Takayasu's arteritis. *Lancet* 2000; 356: 1023-1025.
4. Kaku Y, Aomi S, Tomioka H, Yamazaki K. Surgery for aortic regurgitation and aortic root dilatation in Takayasu arteritis. *Asian Cardiovasc Thorac Ann* 2015; 23: 901-906.
5. Ohigashi H, Tamura N, Ebana Y, Harigai M, Maejima Y, Ashikaga T, et al. Effects of immunosuppressive and biological agents on refractory Takayasu arteritis patients unresponsive to glucocorticoid treatment. *J Cardiol* 2017; 69: 774-778.
6. Lee GY, Jang SY, Ko SM, Kim EK, Lee SH, Han H, et al. Cardiovascular manifestations of Takayasu arteritis and their relationship to the disease activity: analysis of 204 Korean patients at a single center. *Int J Cardiol* 2012; 159: 14-20.
7. Arnaud L, Haroche J, Limal N, Toledano D, Gambotti L, Costedoat Chalumeau N, et al. Takayasu arteritis in France: a single-center retrospective study of 82 cases comparing white, North African, and black patients. *Medicine (Baltimore)* 2010; 89: 1-17.
8. Matsuura K, Ogino H, Kobayashi J, Ishibashi-Ueda H, Matsuda H, Minatoya K, et al. Surgical treatment of aortic regurgitation due to Takayasu arteritis. *Circulation* 2005; 112: 3707-3712.
9. McGraw S, Tarter L, Farzaneh-Far A. Aortic regurgitation in Takayasu's arteritis. *QJM* 2015; 108: 421-422.
10. Li C, Liu Y, Qi R, Zheng J, Zhu J, Chang Q, et al. Repair of Aortic Regurgitation due to Takayasu Arteritis. *Heart Surg Forum* 2013; 16: 24.