

An Alternative Surgical Technique for Repair of Anomalous Origin of the Left Coronary Artery from the Pulmonary Artery

Young-su Kim, M.D., Mina Lee, M.D., Yang Hyun Cho, M.D., Ji-Hyuk Yang, M.D., Tae-Gook Jun, M.D.

Background: For the surgical management of anomalous origin of the left coronary artery from the pulmonary artery (ALCAPA), there have been various techniques that reduce the tension and kinking of the coronary artery during reimplantation to the aorta. The aim of this study is to describe the results of our modified technique of coronary reimplantation for the treatment of ALCAPA. **Methods:** Between October 2003 and February 2011, seven patients underwent coronary reimplantation with the modified technique (tubing formation with the sinus wall of the pulmonary artery and trapdoor formation at the site of implantation in the aorta). The median follow-up duration was 52 months (range, 4 to 72 months). Clinical outcomes and serial echocardiographic data were reviewed. **Results:** There was no mortality. One patient had a small amount of cerebral hemorrhage postoperatively and improved without any sequelae. Another patient had left diaphragm palsy and underwent diaphragm plication. Follow-up echocardiogram showed that all patients had normal ventricular function without chamber enlargement. **Conclusion:** Our modified technique (tubing formation with the sinus wall of the pulmonary artery and trapdoor formation at the site of implantation in the aorta) demonstrated successful clinical outcomes. We conclude that this surgical technique can be a potential alternative for the treatment of ALCAPA.

Key words: 1. Coronary vessel anomalies
2. Bland white Garland syndrome
3. Replantation
4. Congenital heart disease

INTRODUCTION

Anomalous origin of the left coronary artery from the pulmonary artery (ALCAPA) is a rare congenital heart disease, with a reported rate of 1 in 300,000 newborns. It is characterized by high infant mortality, and if untreated, 90% of the patients die within their first year [1-4]. During the prenatal period, myocardial development is normal due to the oxygenated pulmonary arterial blood and high pulmonary arterial pressure (PAP). After birth, however, the left coronary artery

(LCA) supplies deoxygenated blood at a low pressure to most of the left ventricular myocardium [5,6]. Thus, the anomalous origin must be corrected as early as possible [6,7]. Direct coronary artery reimplantation and various modifications have been introduced [8-10]. We have developed a modified, tension-free reimplantation technique using only native pulmonary arterial and aortic tissue. Herein, we introduce our technique and the related clinical outcomes.

Department of Thoracic and Cardiovascular Surgery, Samsung Medical Center, Sungkyunkwan University School of Medicine

Received: September 2, 2013, Revised: October 21, 2013, Accepted: October 25, 2013, Published online: June 5, 2014

Corresponding author: Tae-Gook Jun, Department of Thoracic and Cardiovascular Surgery, Samsung Medical Center, Sungkyunkwan University School of Medicine, 81 Irwon-ro, Gangnam-gu, Seoul 135-710, Korea
(Tel) 82-2-3410-3484 (Fax) 82-2-3410-0089 (E-mail) tg.jun@samsung.com

© The Korean Society for Thoracic and Cardiovascular Surgery. 2014. All right reserved.

© This is an open access article distributed under the terms of the Creative Commons Attribution Non-Commercial License (<http://creativecommons.org/licenses/by-nc/3.0>) which permits unrestricted non-commercial use, distribution, and reproduction in any medium, provided the original work is properly cited.

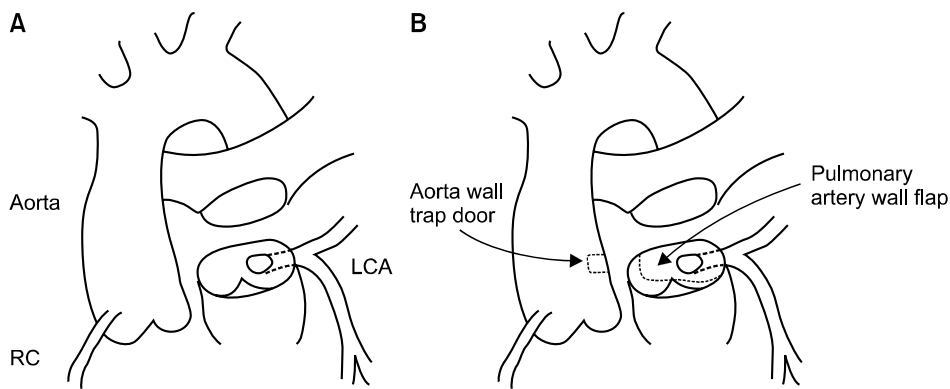


Fig. 1. (A) The main pulmonary artery is transected above the origin of the LCA. (B) The pulmonary artery flap and aortic trapdoor are designed as shown. RC, right coronary artery; LCA, left coronary artery.

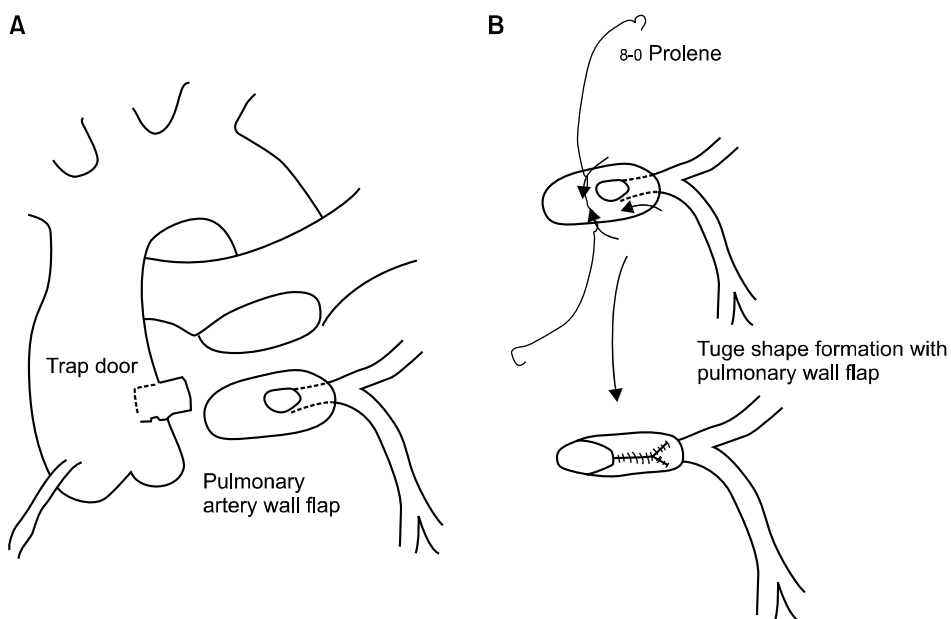


Fig. 2. (A) The left coronary artery is freed from the pulmonary artery, and the aortic trapdoor is opened anteriorly. (B) The pulmonary artery flap is folded to make a tube-like conduit.

METHODS

1) Patients

We identified 7 patients who had undergone surgery for ALCAPA at the Samsung Medical Center from October 2003 to February 2011. Permission to perform a retrospective review of medical records was obtained from the institutional review board of Samsung Medical Center; the need for individual consent for the study was waived. We reviewed their medical records. The median follow-up duration was 52 months (range, 4 to 72 months).

2) Surgical technique

Surgery was performed via standard median sternotomy

and cardiopulmonary bypass (CPB) using moderate hypothermia. Immediately after starting CPB, we clamped both pulmonary arteries. Cardioplegia was delivered via catheters in both the aorta and the pulmonary artery. We transected the main pulmonary artery above the LCA. The tissue around the origin of the LCA was resected anteriorly and posteriorly. The longitudinal pulmonary arterial tissue was folded at a 90-degree angle and sutured superiorly and inferiorly with 8-0 polypropylene to make a tubular conduit. Then, the appropriate site for anastomosis was identified and a trapdoor incision was made. The tubular coronary artery conduit was anastomosed to the aorta with a continuous 7-0 polypropylene suture. The defect in the pulmonary artery was repaired using glutaraldehyde-treated autologous pericardium

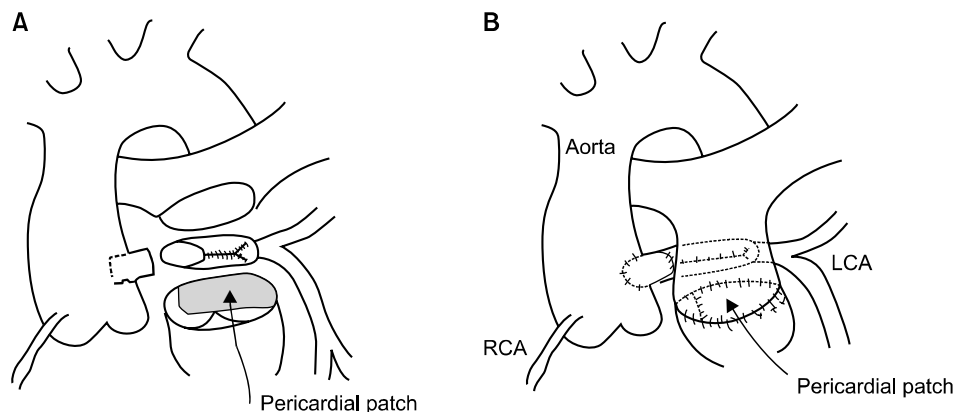


Fig. 3. (A) The LCA is anastomosed to the aortic trapdoor anteriorly and directly to the aorta posteriorly. (B) The pulmonary artery is repaired with autologous pericardium, and the main pulmonary artery is reconstructed. LCA, left coronary artery; RCA, right coronary artery.

Table 1. Patient characteristics

Patient no.	Age (mo)	Female	Preoperative		At last follow-up		MR repair
			LVEF (%)	MR	LVEF (%)	MR	
1	3	No	Poor	Moderate	74	Mild	No
2	6	Yes	15	Severe	58	Minimal	Yes
3	126	Yes	67	Moderate	56	No	No
4	2	Yes	32	Moderate-severe	69	Mild-moderate	No
5	2	Yes	62	Moderate	77	Minimal	No
6	32	Yes	43	Severe	70	Mild	Yes
7	3	Yes	32	Severe	87	No	No

LVEF, left ventricular ejection fraction; MR, mitral regurgitation.

(Figs. 1–3). Two patients who had a severe degree of mitral valve regurgitation with poor left ventricle (LV) function also underwent mitral valve repair.

RESULTS

The median age of the patients was 3 months (range, 2 to 126 months). There were six female patients and one male. Six patients were younger than 12 months at the time of surgery, and one was 10 years old. The patients had a diverse range of symptoms including poor oral intake, cyanosis, lethargy, and tachypnea. One patient did not have any symptoms and was diagnosed with ALCAPA incidentally. Echocardiography was diagnostic in all patients and demonstrated a significant left ventricular distension and mitral regurgitation in all patients (Table 1).

The median CPB and cross-clamp times were 164 minutes (range, 123 to 171 minutes) and 83 minutes (range, 59 to

103 minutes), respectively. There was no mortality. Two patients had postoperative complications. A three-month-old patient had cerebral hemorrhage but recovered well without sequelae. A two-month-old patient had left diaphragm palsy and was treated with diaphragm plication.

Left ventricular contractility was normal before discharge in two patients, and the left ventricular ejection fractions were normal at the last follow-up (Fig. 4). Three patients underwent follow-up computed tomography angiography or coronary angiography, which showed good coronary patency (Figs. 5, 6).

DISCUSSION

ALCAPA was first described by Brooks in 1885 [1] and was categorized into the infant type and adult type according to the timing of symptomatic presentation [4]. The infant type is more common than the adult type, since more than 90% of

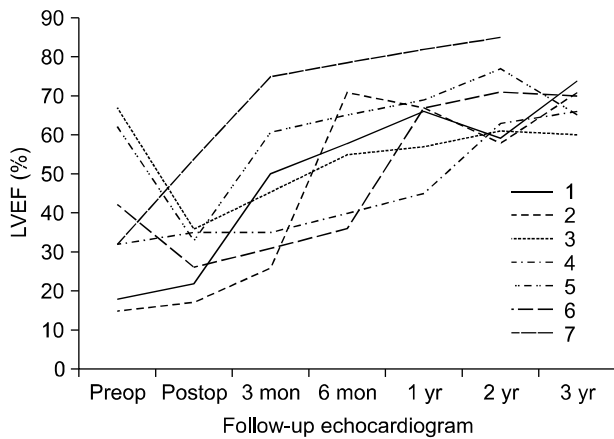


Fig. 4. Follow-up echocardiography showed enhancing LVEF. LVEF, left ventricular ejection fraction; Preop, preoperative; Postop, postoperative.

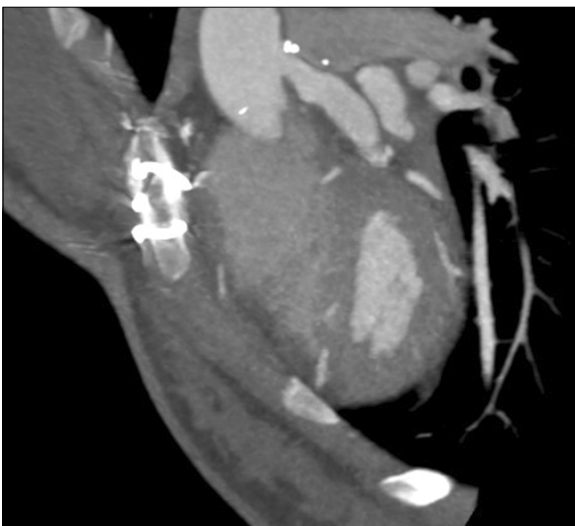


Fig. 5. Follow-up computed tomography angiography was performed 5 years after surgery. It showed good coronary patency.

patients who do not undergo surgery die within the first year of birth [11]. Myocardial ischemia is the most common cause of death. In infant-type ALCAPA, there is almost no collateral formation. Therefore, the myocardial perfusion pressure is low, causing acute infarction. The adult type, on the other hand, has an abundance of collaterals. Even so, myocardial circulation resistance is greater than PAP, and flow reversal occurs, which can progress to ischemia. This is referred to as the “steal phenomenon” and eventually requires surgical correction as well [2,11].

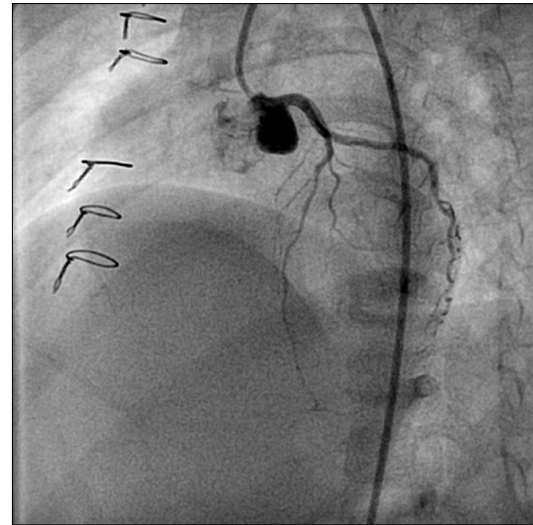


Fig. 6. One year later, patient 7 underwent coronary angiography, which verified the patent left coronary artery.

Surgical correction was first attempted by Potts in 1953 by producing an aortopulmonary shunt to elevate the pulmonary artery pressure and saturation. The first successful case was performed by Sabiston, in which correction was made to a one-coronary system with LCA ligation [5]. LCA ligation is currently not recommended due to high early and late mortality [6].

The currently accepted principle of surgical correction is to maintain the two-coronary system through various techniques such as coronary button transfer, the Takeuchi procedure, and coronary artery bypass graft combined with ligation of the anomalous LCA [11]. Among these techniques, coronary button transfer is used most frequently for the infant type with excellent results [11,12]. In the LCA button transfer technique, the anastomosis should be tension free without any kinks. Because extended LCA dissection can injure branch vessels, modified operational techniques have been used by various centers, including adjustment of the position of the anastomosis in accordance with the origin of the LCA [8] or creation of a pulmonary artery flap to increase the length [7,13-16]. We have used the pulmonary artery tube flap and aortic trapdoor techniques. These techniques allow for tension-free anastomosis without kinking. Thus, we did not experience any coronary artery complications.

It is common for ALCAPA to be accompanied by mitral

regurgitation (MR). If isolated MR is accompanied by LV dysfunction or dilatation, the possibility of ALCAPA must be considered [9]. MR occurs due to LV dysfunction and dilatation as well as ischemic damage to the papillary muscles. Simultaneous correction of MR during ALCAPA surgery remains controversial [9,12,17,18]. In this study, we selectively used mitral annuloplasty in two patients, and no patients had significant MR at the last follow-up.

In conclusion, our modified coronary transfer technique, consisting of a pulmonary artery flap tube and aortic trap-door, is safe and useful. This technique provides a large and long left main coronary artery without extensive dissection.

CONFLICT OF INTEREST

No potential conflict of interest relevant to this article was reported.

REFERENCES

1. Brooks HS. *Two cases of an abnormal coronary artery of the heart arising from the pulmonary artery: with some remarks upon the effect of this anomaly in producing cirroid dilatation of the vessels.* J Anat Physiol 1885;20(Pt 1):26-9.
2. Backer CL, Stout MJ, Zales VR, et al. *Anomalous origin of the left coronary artery: a twenty-year review of surgical management.* J Thorac Cardiovasc Surg 1992;103:1049-57.
3. Kreutzer C, Schlichter AJ, Roman MI, Kreutzer GO. *Emergency ligation of anomalous left coronary artery arising from the pulmonary artery.* Ann Thorac Surg 2000;69:1591-2.
4. Wesselhoeft H, Fawcett JS, Johnson AL. *Anomalous origin of the left coronary artery from the pulmonary trunk: its clinical spectrum, pathology, and pathophysiology, based on a review of 140 cases with seven further cases.* Circulation 1968;38:403-25.
5. Edwards JE. *The direction of blood flow in coronary arteries arising from the pulmonary trunk.* Circulation 1964;29:163-6.
6. Jin Z, Berger F, Uhlemann F, Schroder C, et al. *Improvement in left ventricular dysfunction after aortic reimplantation in 11 consecutive paediatric patients with anomalous origin of the left coronary artery from the pulmonary artery: early results of a serial echocardiographic follow-up.* Eur Heart J 1994;15:1044-9.
7. Alexi-Meskishvili V, Hetzer R, Weng Y, et al. *Anomalous origin of the left coronary artery from the pulmonary artery: early results with direct aortic reimplantation.* J Thorac Cardiovasc Surg 1994;108:354-62.
8. Neches WH, Mathews RA, Park SC, et al. *Anomalous origin of the left coronary artery from the pulmonary artery: a new method of surgical repair.* Circulation 1974;50:582-7.
9. Vouhe PR, Tamisier D, Sidi D, et al. *Anomalous left coronary artery from the pulmonary artery: results of isolated aortic reimplantation.* Ann Thorac Surg 1992;54:621-6.
10. Turley K, Szarnicki RJ, Flachsbart KD, Richter RC, Popper RW, Tarnoff H. *Aortic implantation is possible in all cases of anomalous origin of the left coronary artery from the pulmonary artery.* Ann Thorac Surg 1995;60:84-9.
11. Pena E, Nguyen ET, Merchant N, Dennie G. *ALCAPA syndrome: not just a pediatric disease.* Radiographics 2009;29:553-65.
12. Dodge-Khatami A, Mavroudis C, Backer CL. *Anomalous origin of the left coronary artery from the pulmonary artery: collective review of surgical therapy.* Ann Thorac Surg 2002;74:946-55.
13. Alsoufi B, Sallehuddin A, Bulbul Z, et al. *Surgical strategy to establish a dual-coronary system for the management of anomalous left coronary artery origin from the pulmonary artery.* Ann Thorac Surg 2008;86:170-6.
14. El-Rassi I, Soueide A, Sweid O, Chabb B. *Transfer technique of an anomalous coronary artery from the anterior pulmonary artery.* Ann Thorac Surg 2012;93:1738-40.
15. Barth MJ, Allen BS, Gulecyuz M, Chiemmongkoltip P, Cuneo B, Ilbawi MN. *Experience with an alternative technique for the management of anomalous left coronary artery from the pulmonary artery.* Ann Thorac Surg 2003;76:1429-34.
16. Kang CH, Kim WH, Seo HJ, et al. *Surgical treatment of anomalous origin of coronary artery from the pulmonary artery: postoperative changes of ventricular dimensions and mitral regurgitation.* Korean J Thorac Cardiovasc Surg 2004;37:19-26.
17. Azakie A, Russell JL, McCrindle BW, et al. *Anatomic repair of anomalous left coronary artery from the pulmonary artery by aortic reimplantation: early survival, patterns of ventricular recovery and late outcome.* Ann Thorac Surg 2003;75:1535-41.
18. Caspi J, Pettitt TW, Sperrazza C, Mulder T, Stopa A. *Reimplantation of anomalous left coronary artery from the pulmonary artery without mitral valve repair.* Ann Thorac Surg 2007;84:619-23.