

# An 18-Year-Old Man With Hepatitis B Virus Infection and Hepatoblastoma

Seyed Saeid Mohammadi Bonehi<sup>1\*</sup>, Homayoon Vahedi<sup>2</sup>, Mehdi Saberifiroozi<sup>3</sup>, Mohammad Vasei<sup>4</sup>, Amir Pejman Hashemi Taheri<sup>5</sup>

1. Gastroenterology Fellow, Digestive Disease Research Center, Shariati Hospital, Tehran University of Medical Sciences, Tehran, Iran
2. Associate Professor, Digestive Disease Research Center, Shariati Hospital, Tehran University of Medical Sciences, Tehran, Iran
3. Professor, Digestive Disease Research Center, Shariati Hospital, Tehran University of Medical Sciences, Tehran, Iran
4. Professor, Department of Pathology, Shariati Hospital, Tehran University of Medical Sciences, Tehran, Iran
5. Assistant Professor, Department of Radiology, Shariati Hospital, Tehran University of Medical Sciences, Tehran, Iran

**\* Corresponding Author:**

Seyed Saeid Mohammadi Bonehi, MD  
 Digestive Disease Research Center, Shariati Hospital, Tehran University of Medical Sciences, Tehran, Iran.  
 Tel: +98 21 82415104  
 Fax: +98 21 82415000  
 Email: ssmmbb293@yahoo.com  
 Received: 27 Mar. 2012  
 Accepted: 12 May 2012

## ABSTRACT

A young man presented with a large liver mass and positive hepatitis B virus markers. This 18-year-old male has developed ascites, jaundice, high serum alpha fetoprotein (AFP) level, liver mass and portal hypertension, without fever or calcification in the mass. All favored the diagnosis of rapidly, progressive hepatocellular carcinoma, however proven hepatoblastoma in liver biopsy. Hepatoblastoma usually manifests prior to the third year of life, but can rarely be seen in older children or adults. Although HCC rarely can be presented in young patients with HBV infection, but in patients without cirrhosis hepatoblastoma should be considered as the first possible diagnosis.

## KEYWORDS

Liver mass; Malignancy; Hepatoblastoma; High alpha fetoprotein; Hepatitis B; Ascites

Please cite this paper as:

Mohammadi Bonehi SS, Vahedi H, Saberifiroozi M, Vasei M, Hashemi Taheri AP. An 18-year-old Man with Hepatitis B Virus Infection and Hepatoblastoma. *Middle East J Dig Dis* 2012;4:173-6.

## INTRODUCTION

Hepatoblastoma is a primary malignant liver tumor that originates from embryonic and fetal liver cells. It constitutes 30%-45% of all primary liver tumors and 50%-60% of all malignant tumors that occur during childhood.<sup>1,2</sup> Hepatoblastoma is often associated with a congenital anomaly, particularly with familial adenomatous polyposis coli.<sup>3</sup> It is primarily a tumor of young children, and more than 90% of tumors usually present before five years old, but rarely presents in older children or adults.<sup>4,5</sup> Males are affected twice as often as females. However with increasing age, the gender difference equalizes. This is a relatively rapid growing tumor. The serum alfa-fetoprotein (AFP) levels are markedly elevated in approximately 90% of the patients. The tumor can be diagnosed by ultrasonography, CT scan or MRI. Calcifications are frequently visualized.<sup>6</sup>

## CASE REPORT

An 18-year-old man referred due to right upper quadrant (RUQ) pain since two months prior to admission in this hospital. The RUQ pain, which was constant has had radiation to his back, and gradually was worsened. He gradually developed yellowish discoloration of the sclera and skin and abdominal distention. He had complaints of low

back pain, that aggravated by movement since one month prior to admission. The patient had anorexia with a 15 kg weight loss during these two months with no history of fever, chills, vomiting, diarrhea, change in bowel habits or tarry stools.

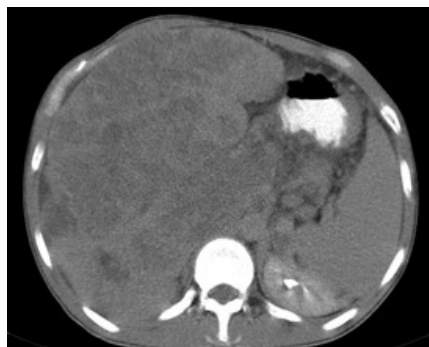In physical examination he was icteric and wasted. The abdomen was protruded, flanks were bulged and shifting dullness was positive. Few collateral vessels were present in abdominal surface. The liver was enlarged with firm two nodular consistency, and spleen was palpable by ballotement maneuver. Examination of genitalia and testes were normal. Laboratory results were as follows: hemoglobin (9.1 g/dl), platelets (257000/mm<sup>3</sup>), Homocysteine: 20.5 μmol/L (normal 5-15), anti-cardiolipinIgM 2.9 MPL (normal <15), anti-phospholipid IgG: 1.8 (normal <10), protein C: 127% (normal 70-130), protein S: 51% (normal 65-140), lupus anticoagulant: negative, alanine aminotransferase: 113 IU/L, aspartate aminotransferase: 495 IU/L, alkaline phosphatase: 1253 IU/L, total bilirubin: 12.6 mg/dl, direct bilirubin: 12 mg/dl and LDH: 789 U/L, serum HBs Ag was positive and HBV DNA serum level was 247 IU/ml. Total protein, albumin, and coagulation indexes were within normal ranges. Paracentesis of ascitic fluid showed clear color with high serum ascites albumin gradient, without findings of peritonitis.

Ultrasonography of abdomen showed a coarse liver parenchyma, without mass or space occupying lesion. The portal vein diameter was 11 mm. The spleen was 201x55 mm with a homogeneous echo pattern. Moderate ascites was also noted.

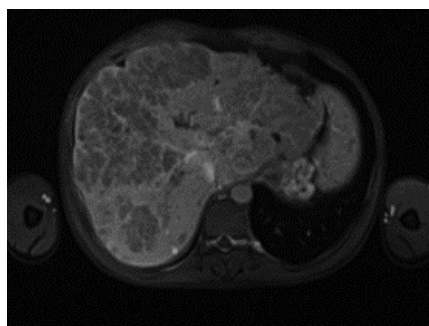
Endoscopy was notable for the presence of F1 esophageal varices, and fundal varices (without active bleeding or stigmata of recent hemorrhage), and a kissing type duodenal ulcer disease.

Color Doppler Ultrasonography of abdomen showed splenic and portal vein thrombosis, but the hepatic artery and inferior vena cava were normal. The initial serum alpha-fetoprotein level was 300 ng/ml (normal 0-8.5) that after ten days increased to 112000 ng/ml. Spiral triphasic CT scan (Fig. 1) and MRI (Fig. 2) revealed atrophic right lobe with mild enlargement of left lobe.

The caudate lobe was heterogeneous and severely enlarged. There was thrombosis in the main portal vein with extension to the intra-hepatic branches,



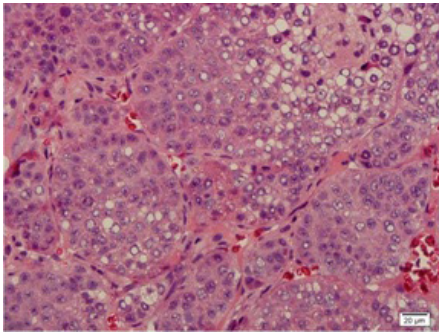
**Fig 1:** Triphasic CT scan of the liver shows a large heterogeneous caudate lobe, with small right and left liver lobes.



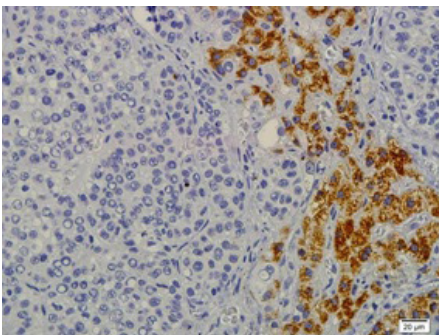
**Fig 2:** MRI shows the presence of a large liver mass.

and splenic vein. Moderate ascites was also seen. The patient underwent a liver biopsy under sonography guide.

Liver biopsy (Figs. 3 and 4) contained normal as well as neoplastic tissues. In the non-neoplastic tissues, there was no evidence of cirrhosis. The tumor component was composed of small and large nests of small hepatocyte-like cells. The nests were separated by very delicate fibrovascular fascicles. The individual cells were round to polygonal shaped with amphophilic to somewhat eosinophilic cytoplasm and round to oval hyperchromatic nuclei with occasional nucleoli. Intranuclear optically clear inclusions were occasionally seen. Intracytoplasmic micro- as well as macro-vesicular fat accumulation was prominent. There were also scattered and large aggregates of polygonal cells with abundant fat accumulation in the cytoplasm (Fig. 3). Immunohistochemistry (IHC) was positive for Hepar1 (focal), vimentin, CK, AFP, pCEA and AFP (diffuse), and alfa-1 anti-trypsin. IHC was negative for CD34, synaptophysin, NSE, TTF-1, desmin, chromogranin, placental alkaline phosphatase,



**Fig 3:** H&E stain of liver mass shows some fat vesicles with no evidence of cirrhosis.



**Fig 4:** Immunohistochemistry for Hepar-1 was focally positive in the mass.

CD99, CD10, albumin, and S100. According to the histopathology features and IHC profile, the diagnosis was reported as fetal type hepatoblastoma.

## DISCUSSION

Hepatoblastoma is the most common primary liver tumor of childhood and adolescence, but is rarely found in adults, this tumor presents more commonly before the age of three years, predominantly in males.<sup>7-9</sup> However with increasing age the gender difference disappears and the incidence becomes equal among genders. Hepatoblastoma commonly forms a large mass within the right lobe of the liver.<sup>6</sup> Multiple nodules in both lobes are also a common presentation. Less common is the diffuse tumor that involves the entire liver.<sup>4</sup> In children, hepatoblastoma can be presented with rapidly enlarging upper abdominal mass, weight loss, and or failure to thrive; in adults symptoms of abdominal pain, fever, malaise and the presence of an abdominal mass are more frequent.<sup>10</sup> Paraneoplastic syndrome with unusual finding, such as virilization also can be seen. The serum marker AFP is mostly elevated in this tumor.<sup>11</sup>

Initial diagnostic evaluations for liver structural abnor-

malities are based on imaging studies. Ultrasonography is a noninvasive modality useful in the evaluation of liver mass. Hepatoblastoma presents as a hyperechoic, solid, intrahepatic mass on ultrasound.<sup>12</sup> Other standard investigations include CT and MRI. Calcification is seen in tumors detected by CT scan.<sup>13</sup>

Hepatocellular carcinoma is the most common primary liver tumor seen in adults and is closely related to cirrhosis and chronic liver disease, particularly in patients with chronic hepatitis B virus infection. Patients with hepatocellular carcinoma remain asymptomatic for a long period of time. Diagnosis of hepatocellular carcinoma should be considered in patients with cirrhosis who deteriorate clinically or has a liver mass in radiological workups.<sup>14</sup> In any patient with cirrhosis and newly developed signs of decompensation such as ascites, hepatic encephalopathy, variceal bleeding or fever of unknown origin, the presence of hepatocellular carcinoma should be investigated.<sup>15</sup>

Our patient presented with ascites, esophageal varices and a large firm liver and positive hepatitis B virus antigen, so the initial clinical impression was HBV induced liver cirrhosis with hepatocellular carcinoma, but normal platelet count, and albumin was not in favor of advanced portal hypertension.

Hepatocellular carcinoma is the first diagnosis in any patient with clinical findings of cirrhosis, liver mass and elevated serum AFP. HCC have been reported in HBV infected non-cirrhotic young patients below age 20 but is a rare finding. In a report by Sezaki et al. only four out of 187 patients with HCC were young with ages; 10, 22, 23, and 26 years. They suggested predisposition to HCC due to integration of HBV genome into host genome during intrauterine life.<sup>16</sup> Although development of portal vein thrombosis in a patient with cirrhosis can be explained, however the presence of both cirrhosis and hepatocellular carcinoma in a young adult with isolated HBV infection is very unusual. In young patients with liver mass (es), without evidence of cirrhosis and an elevated AFP, hepatoblastoma should be considered.

The impression of caudate lobe hypertrophy in the radiologic reports can cause confusion in such cases for differentiation between cirrhosis plus hepatocellular carcinoma versus a large slowly growing hepatoblastoma arising from caudate lobe within non cirrhotic liver. Any pathology that causes caudate lobe enlargement can induce pressure effect on the portal venous system. This process can induce right and left lobe liver atrophy and

portal vein thrombosis also. However for final diagnosis, liver biopsy was performed, which confirmed large hepatoblastoma. Pathologic diagnosis of adult hepatoblastoma is difficult in that hepatic teratoma; carcinosarcoma, malignant mesenchymal tumor, and hepatocellular with sarcomatous changes and hepatoblastomatous lesions should also be considered and be differentiated by appropriate immunohistochemistry evaluation.

Treatment of choice is complete surgical resection, and without surgery the survival is poor. However improvements in survival have occurred with standardized chemotherapy that reduces the tumor size, enabling complete tumor excision. This process can be performed in patients who present with unresectable or metastatic disease.<sup>17</sup> Chemotherapy reduces bleeding from the tumor and surrounding normal parenchyma and vascular structures, therefore facilitating resection of lesion. Chemotherapy has been proven effective as both an adjuvant and neoadjuvant treatment for tumor shrinkage, followed by surgical removal of the mass. Hepatoblastoma is sensitive to chemotherapeutic drugs such as doxorubicin, cisplatin, vincristine, 5-FU, and cyclophosphamide.<sup>18</sup>

This presentation of hepatoblastoma in a young patient with positive hepatitis B virus infection and portal hypertension (ascites, esophageal varices, and splenomegaly) is unusual. However the normal platelet count and serum albumin in the patient is not in favor of advanced cirrhosis as the cause of portal hypertension. The histologic evaluation of non-tumoral segments of liver can help us for differentiation of cirrhosis with HCC or a non-HCC liver tumor arising in a non-cirrhotic liver. Calcification within the mass, which is in favor of hepatoblastoma, was not shown in abdominal triphasic CT scan; and only the liver biopsy results were positive for hepatoblastoma. The patient expired one month after diagnosis because his family rejected treatment.

#### CONFLICT OF INTEREST

The authors declare no conflict of interest related to this work.

#### REFERENCES

- Dancyngier, H. Hepatoblastoma. In: Dancyngier H. Clinical Hepatology, Principles and Practice of Hepatobiliary Diseases. Springer Heidelberg Dordrecht London New York, 2010 pp. 1388-9.
- Hadzic N, Finegold MJ. Liver neoplasia in children. *Clin Liver Dis* 2011;**15**:443-62.
- Giardiello FM, Petersen GM, Brensinger JD, Luce MC, Cayouette MC, Bacon J, et al. Hepatoblastoma and APC gene mutation in familial adenomatous polyposis. *Gut* 1996;**39**:867-9.
- Stocker JT, Ishak KG. Hepatoblastoma, in Okuda K, Ishak KG (eds): Neoplasms of the Liver, Tokyo, Springer-Verlag, 1987, pp 127-136.
- Kacker LK, Khan EM, Gupta R, Kapoor VK, Pandey R, Gupta RK, et al. Hepatoblastoma in an adult with biliary obstruction and associated portal venous thrombosis. *HPB Surg* 1995;**9**:47-9.
- Honan RP, Haqqani MT. Mixed hepatoblastoma in the adult: case report and review of the literature. *J Clin Pathol* 1980;**33**:1058-63.
- Ahn HJ, Kwon KW, Choi YJ, Kim HJ, Hong SP, Oh D, et al. Mixed hepatoblastoma in an adult—a case report and literature review. *J Korean Med Sci* 1997;**12**:369-73.
- Bortolasi L, Marchiori L, Dal Dosso I, Colombari R, Nicolli N. Hepatoblastoma in adult age: a report of two cases. *Hepato-gastroenterology* 1996;**43**:1073-8.
- Anderson BB, Ukah F, Tette A, Villaflor SG, Koh D, Seton P. Primary tumors of the liver. *J Natl Med Assoc* 1992;**84**:129-35.
- Fiaschetti V, Fiori R, Gaspari E, Crusco S, Simonetti G. Mixed hepatoblastoma in a young male adult: a case report and literature review. *Case Report Med* 2010;2010:919457.
- Ke HY, Chen JH, Jen YM, Yu JC, Hsieh CB, Chen CJ, et al. Ruptured hepatoblastoma with massive internal bleeding in an adult. *World J Gastroenterol* 2005;**11**:6235-7.
- de Campo M, de Campo JF. Ultrasound of primary hepatic tumours in childhood. *Pediatr Radiol* 1988;**19**:19-24.
- Pichardo-Bahena R, Méndez-Sánchez N. Images in hepatology. Hepatoblastoma. *Ann Hepatol* 2005;**4**:131.
- Venook AP, Papandreou C, Furuse J, de Guevara LL. The incidence and epidemiology of hepatocellular carcinoma: a global and regional perspective. *Oncologist* 2010;**15**Suppl 4:5-13.
- Di Bisceglie AM. Hepatitis B and hepatocellular carcinoma. *Hepatology* 2009;**49**:S56-60.
- Sezaki H, Kobayashi M, Hosaka T, Someya T, Akuta N, Suzuki F, et al. Hepatocellular carcinoma in noncirrhotic young adult patients with chronic hepatitis B viral infection. *J Gastroenterol* 2004;**39**:550-6.
- Pimpalwar AP, Sharif K, Ramani P, Stevens M, Grundy R, Morland B, et al. Strategy for hepatoblastoma management: Transplant versus nontransplant surgery. *J Pediatr Surg* 2002;**37**:240-5.
- Reynolds M. Pediatric liver tumors. *Semin Surg Oncol* 1999;**16**:159-72.