

# Silicone-induced Granuloma After Buttock Augmentation

Mansher Singh, MD\*  
 Isaac H. Solomon, MD, PhD†  
 Michael S. Calderwood, MD,  
 MPH‡  
 Simon G. Talbot, MD\*

**Summary:** Liquid silicone is inexpensive, minimally antigenic, and likely noncarcinogenic. Its simplicity of use has made it popular as a soft-tissue filler in some parts of the world for patients seeking rapid soft-tissue augmentation of the face, breast, and buttocks. However, multiple reports describe the complications of silicone injections such as cellulitis, abscess, ulceration, and foreign body migration. We present an unusual complication of granulomatous reaction secondary to silicone injection for buttock augmentation, with a literature review of this entity and treatment options. Our patient was a 54-year-old woman who underwent bilateral buttock augmentation in the Dominican Republic using percutaneous injection of liquid silicone. She presented to our facility 1 year after this procedure with pain and inflammation of both buttocks. She was diagnosed with multiple silicone granulomas. Her symptoms completely resolved with a 3-week course of minocycline. Granulomatous reactions to silicone may occur months to years after the silicone injection. The incidence of such complications may be increased when nonmedical-grade silicone is used, and hence, when these procedures are performed in developing countries. Tetracycline antibiotics, especially minocycline, may be used to achieve sustained remission. (*Plast Reconstr Surg Glob Open* 2016;4:e624; doi: 10.1097/GOX.0000000000000618; Published online 19 February 2016.)

Liquid silicone has been used extensively as an injectable soft-tissue filler.<sup>1</sup> It is inexpensive, available “off the shelf,” minimally antigenic, and likely noncarcinogenic, and it has demonstrated long-term in vivo stability.<sup>2</sup> Injection is simple and allows for immediate, visible results with minimal downtime for patients. These properties make it a popular choice for soft-tissue augmentation in some parts of the world. However, the lack of well-documented

controlled trials limits its usage, and there have been multiple reports describing the complications of silicone injection such as cellulitis, abscess, ulceration, disfiguring scarring, and foreign body migration.<sup>3–14</sup> In this study, we report on a granulomatous reaction secondary to silicone injection for the buttock augmentation performed in the Dominican Republic and review the available literature on this topic, particularly focusing on treatment modalities.

## CASE REPORT

The patient, a 54-year-old woman, presented to our emergency room with 4 days of erythema, induration, and pain in her bilateral buttocks (Fig. 1). Her medical history was significant for bilateral buttock augmentation, performed once on an outpatient, approximately 1 year before in the Dominican Republic. We contacted the practitioner who performed the

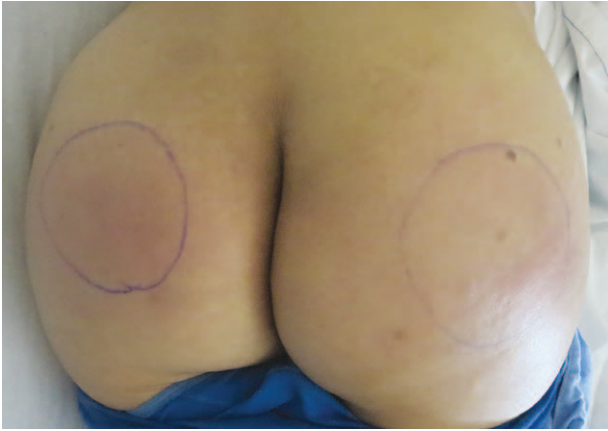From the \*Division of Plastic Surgery, Department of Surgery, †Department of Pathology, and ‡Division of Infectious Disease, Department of Medicine, Brigham and Women’s Hospital, Harvard Medical School, Boston, Mass.

Received for publication December 15, 2015; accepted January 13, 2016.

Copyright © 2016 The Authors. Published by Wolters Kluwer Health, Inc. on behalf of The American Society of Plastic Surgeons. All rights reserved. This is an open-access article distributed under the terms of the Creative Commons Attribution-Non Commercial-No Derivatives License 4.0 (CCBY-NC-ND), where it is permissible to download and share the work provided it is properly cited. The work cannot be changed in any way or used commercially.

DOI: 10.1097/GOX.0000000000000618

**Disclosure:** The authors have no financial interest to declare in relation to the content of this article. The Article Processing Charge was paid for by the authors.



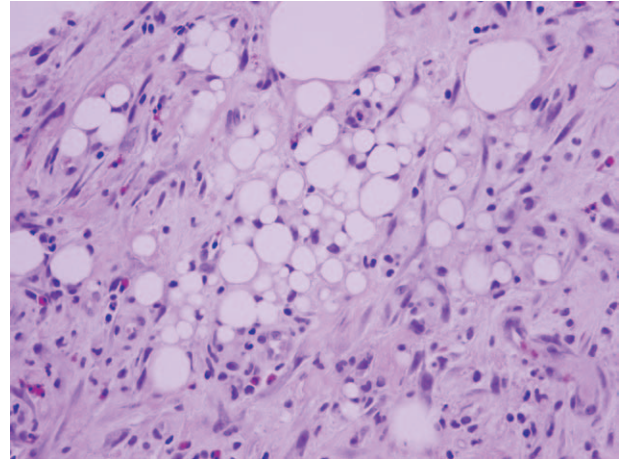
**Fig. 1.** Erythematous indurated lesions in bilateral buttocks 1 year after silicone injections for buttock augmentation.

procedure by phone, but they did not have a record of the substance injected. The patient had a temperature of 101.2°F, and laboratory results showed a leukocytosis of 12.2 thousands/microliter. Because of the concern about the possibility of infection (which we have seen commonly in similar patients), the patient was empirically started on vancomycin and ceftriaxone pending further studies. Magnetic resonance imaging was performed, which demonstrated extensive edema of the gluteal subcutaneous tissue, numerous nodular foci likely representing injected foreign material, consistent with silicone, and no discrete drainable fluid. To rule out the infection and accurately diagnose the injected substance, we performed a deep tissue biopsy. This was sent for Gram stain and bacterial, fungal, and mycobacterial cultures—all of which returned negative. Pathology was consistent with a silicone granulomatous reaction associated with patchy acute inflammation (Fig. 2).

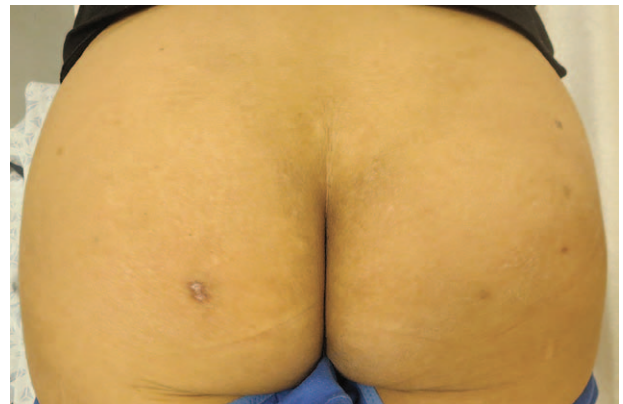After review of the pathology, vancomycin and ceftriaxone were discontinued, and the patient was transitioned to twice daily 100 mg minocycline to treat this inflammatory reaction. She did not receive steroids. Her symptoms completely resolved within 3 weeks, and minocycline was discontinued (Fig. 3). Given the diffuse and extensive nature of her silicone injections and resolution of her symptoms with medical management, we decided against surgical debridement. She has not had any recurrence of her symptoms during 18-month follow-up.

## DISCUSSION

Medical-grade silicone is a standardized sterile preparation with high purity and long shelf life.<sup>6,15</sup> Its use as a soft-tissue filler has been described using a microdroplet technique (0.01–0.03 mL droplets of silicone) in the deep dermal or subdermal plane at 1- to 3-mm intervals with 4- to 6-week intervals



**Fig. 2.** Biopsy from the buttock shows silicone granulomas consisting of variably sized vacuoles surrounded by scattered lymphocytes, eosinophils, neutrophils, and plasma cells. Giant cells are often present but were not identified in this biopsy (hematoxylin and eosin stain, 40x).



**Fig. 3.** Resolution of symptoms after completion of 3-week minocycline therapy. Scar on the right buttock is secondary to biopsy for pathology.

between repeated injections.<sup>16</sup> By using this technique, multiple authors have described satisfactory results.<sup>16,17</sup> However, complications have been reported. Injection of large volumes of silicone can result in tracking along tissue planes to distant sites.<sup>17,18</sup> Industrial or nonmedical silicone may be associated with high complication rates.<sup>19,20</sup> Inexperienced practitioners may also be more apt to inject less judiciously. Furthermore, it can be challenging to determine the technique and materials used when such procedures are performed in foreign countries and present in the United States with complications.

Erythema, edema, and textural changes that occur immediately after the procedure are generally self-limited. Serious complications include chronic cellulitis and abscess formation, ulceration, pneumonitis, cosmetic irregularities and asymmetries,

**Table 1. Disease and Treatment Characteristics of the Patients Diagnosed with Silicone Granulomas Secondary to Buttock Augmentation with Liquid Silicone Injection**

Authors	Age/Sex	Incubation Period	Material/Practitioner	Symptoms	Treatment
Pasternack et al <sup>8</sup>	47/F	10 y	Medical grade/ nonprofessional (DR)	Erythema, swelling of anterior legs	Etanercept × 2 mo
Pasternack et al <sup>8</sup>	37/F	5 mo	Not described	Erythematous nodules and plaques in buttocks	Etanercept × 1 mo
Schwartzfarb et al <sup>9</sup>	40/F	9 mo	Medical grade/ nonprofessional	Recurrent cellulitis of right lower extremity	Prednisone × 30 mg daily (tapered) + minocycline
Altmeyer et al <sup>10</sup>	38/F	1 y	Unknown grade/ illegal practitioner	Erythematous plaques in bilateral gluteal cleft	Not discussed
Lopiccolo et al <sup>11</sup>	29/F	3 y	Unknown grade/ illegal practitioner	Fever, chills, pain nodules in buttocks and posterior thighs	Minocycline 100 mg bid × 4wk + tetracycline 500mg bid × 8 wk
Camuzard et al <sup>13</sup>	63/F	9 y	Unknown grade/ unknown	Inflammatory plaques on buttocks, hypercalcemia	Prednisone 30 mg daily × 3wk (tapered)
Emer et al <sup>12</sup>	30/F	Not described	Unknown grade/ unknown	Edematous, indurated plaques and nodules of buttocks	Minocycline 100 mg bid
Paul et al <sup>14</sup>	47/F	9 mo to 2 y	Unknown grade/not described (DR)	Erythematous indurated plaques on the left buttock	Doxycycline 100 mg × bid

bid, twice daily; F, female; DR, Dominican Republic.

perforation or injuries to critical structures, foreign body reactions, and migration of silicone. These can present even years after injection.<sup>3-7</sup> Granulomatous reactions after silicone injection for buttock augmentation have only been reported in limited studies.<sup>8-14</sup> A summary of available reports of silicone granuloma after liquid silicone injection for buttock augmentation is described in Table 1. The period between procedure and symptoms ranges from 5 months to 10 years. Almost all reported patients have been treated by unlicensed practitioners with an unknown grade of silicone.<sup>11</sup> Most of the patients with this complication present with erythema, induration, and plaques (well-circumscribed, elevated, superficial, solid lesions) in the buttocks. Two of 8 patients described in the literature underwent this procedure in Dominican Republic similar to our index patient.<sup>8,14</sup>

When patients present with an incomplete history, questionable circumstances, or unknown surgery, an accurate diagnosis is a key step in directing appropriate treatment. We have been successful in achieving diagnoses with a combination of laboratory studies, imaging, and tissue pathology. Perhaps most important at the outset is to rule out a severe or atypical infection, many of which we have seen in cosmetic surgical patients returning from surgery in the developing world.

The treatment of silicone granulomas can be challenging, and a number of treatment modalities have been described with varying degrees of success. Tetracycline antibiotics, mainly minocycline, have been reported to result in complete resolution of symptoms in multiple studies.<sup>21,22</sup> This could be

attributed to the inherent antiinflammatory and immune-modulating capacity of this drug. Other immunomodulating therapies, such as etanercept, have been described.<sup>8,23</sup> Oral steroids may result in temporary resolution but seem to be prone to recurrence during tapering.<sup>21,24</sup> Surgical excision may be considered if a granuloma is well circumscribed, but these injections are typically so extensive and diffuse that surgery can be complicated and disfiguring and complete silicone removal is often impossible.<sup>6</sup>

## CONCLUSIONS

Granulomatous reactions to silicone may occur months to years after silicone injection for buttock augmentation. The incidence of such complications may be increased when nonmedical-grade silicone or poor technique is used. Given the abundance of well-studied alternative substances and the relative success of fat grafting in larger volume cases, we do not perform liquid silicone injections. The use of tetracycline antibiotics, especially minocycline, appears to be successful at achieving sustained remission.

*Simon G. Talbot, MD*

Division of Plastic Surgery  
Department of Surgery  
Brigham and Women's Hospital  
Harvard Medical School  
75 Francis St., Boston, MA 02115  
E-mail: sgtalbot@partners.org

## REFERENCES

1. Loustau HD, Mayer HF, Catterino L. Dermolipectomy of the thighs and buttocks to solve a massive silicone oil injection. *Aesthetic Plast Surg*. 2009;33:657-660.

2. Sobanko J, Scheinfeld N, Kriegel D. Liquid injectable silicone: should you implement it in your practice? *Cosmet Dermatol*. 2006;19:534–536.
3. Rapaport MJ, Vinnik C, Zarem H. Injectable silicone: cause of facial nodules, cellulitis, ulceration, and migration. *Aesthetic Plast Surg*. 1996;20:267–276.
4. Ellenbogen R, Rubin L. Injectable fluid silicone therapy. Human morbidity and mortality. *JAMA* 1975;234:308–309.
5. Gurvitis GE. Silicone pneumonitis after a cosmetic augmentation procedure. *N Engl J Med*. 2006;354:211–212.
6. Ficarra G, Mosqueda-Taylor A, Carlos R. Silicone granuloma of the facial tissues: a report of seven cases. *Oral Surg Oral Med Oral Pathol Oral Radiol Endod*. 2002;94:65–73.
7. Arin MJ, Bâte J, Krieg T, et al. Silicone granuloma of the face treated with minocycline. *J Am Acad Dermatol*. 2005;52(2 Suppl 1):53–56.
8. Pasternack FR, Fox LP, Engler DE. Silicone granulomas treated with etanercept. *Arch Dermatol*. 2005;141:13–15.
9. Schwartzfarb EM, Hametti JM, Romanelli P, et al. Foreign body granuloma formation secondary to silicone injection. *Dermatol Online J*. 2008;14:20.
10. Altmeyer MD, Anderson LL, Wang AR. Silicone migration and granuloma formation. *J Cosmet Dermatol*. 2009;8:92–97.
11. Lopiccolo MC, Workman BJ, Chaffins ML, et al. Silicone granulomas after soft-tissue augmentation of the buttocks: a case report and review of management. *Dermatol Surg*. 2011;37:720–725.
12. Emer J, Roberts D, Levy L, et al. Indurated plaques and nodules on the buttocks of a young healthy female. *J Clin Aesthet Dermatol*. 2013;6:46–49.
13. Camuzard O, Dumas P, Foissac R, et al. Severe granulomatous reaction associated with hypercalcemia occurring after silicone soft tissue augmentation of the buttocks: a case report. *Aesthetic Plast Surg*. 2014;38:95–99.
14. Paul S, Goyal A, Duncan LM, et al. Granulomatous reaction to liquid injectable silicone for gluteal enhancement: review of management options and success of doxycycline. *Dermatol Ther*. 2015;28:98–101.
15. Selmanowitz VJ, Orentreich N. Medical-grade fluid silicone. A monographic review. *J Dermatol Surg Oncol*. 1977;3:597–611.
16. Narins RS, Beer K. Liquid injectable silicone: a review of its history, immunology, technical considerations, complications, and potential. *Plast Reconstr Surg*. 2006;118(3 Suppl):77S–84S.
17. Duffy DM. Liquid silicone for soft tissue augmentation. *Dermatol Surg*. 2005;31(11 Pt 2):1530–1541.
18. Orentreich DS. Liquid injectable silicone: techniques for soft tissue augmentation. *Clin Plast Surg*. 2000;27:595–612.
19. Prather CL, Jones DH. Liquid injectable silicone for soft tissue augmentation. *Dermatol Ther*. 2006;19:159–168.
20. Duffy DM. The silicone conundrum: a battle of anecdotes. *Dermatol Surg*. 2002;28:590–594.
21. Arin MJ, Bâte J, Krieg T, et al. Silicone granuloma of the face treated with minocycline. *J Am Acad Dermatol*. 2005;52(2 Suppl 1):53–56.
22. Beer K. Delayed onset nodules from liquid injectable silicone: report of a case, evaluation of associated histopathology and results of treatment with minocycline and celocoxib. *J Drugs Dermatol*. 2009;8:952–954.
23. Desai AM, Browning J, Rosen T. Etanercept therapy for silicone granuloma. *J Drugs Dermatol*. 2006;5:894–896.
24. Lemperle G, Gauthier-Hazan N. Foreign body granulomas after all injectable dermal fillers: part 2. Treatment options. *Plast Reconstr Surg*. 2009;123:1864–1873.