

Improved analysis of palm creases

Jin Seo Park¹, Dong Sun Shin², Wonsug Jung², Min Suk Chung²

Department of Anatomy, ¹Dongguk University School of Medicine, Gyeongju, ²Ajou University School of Medicine, Suwon, Korea

Abstract: Palm creases are helpful in revealing anthropologic characteristics and diagnosing chromosomal aberrations, and have been analyzed qualitatively and quantitatively. However, previous methods of analyzing palm creases were not objective so that reproducibility could not be guaranteed. In this study, a more objective morphologic analysis of palm creases was developed. The features of the improved methods include the strict definition of major and minor palm creases and the systematic classification of major palm creases based on their relationships, branches, and variants. Furthermore, based on the analysis of 3,216 Koreans, palm creases were anthropologically interpreted. There was a tendency for palm creases to be evenly distributed on the palm, which was acknowledged by the relationship between major and minor creases as well as by the incidences of major creases types. This tendency was consistent with the role of palm creases to facilitate folding of palm skin. The union of major palm creases was frequent in males and right palms to have powerful hand grip. The new method of analyzing palm creases is expected to be widely used for anthropologic investigation and chromosomal diagnosis.

Key words: Dermatoglyphics, analysis, physical anthropology

Received May 6, 2010; Revised May 31, 2010; Accepted June 7, 2010

Introduction

As palm creases are helpful in discovering anthropologic characteristics and diagnosing several diseases, including chromosomal aberrations, palm creases have been analyzed qualitatively (Alter 1970; Chaube 1977; Dar *et al.*, 1977) and quantitatively (Dar & Schmidt, 1976). However, previous methods of analyzing palm creases have not been sufficiently objective, thus reproducibility could not be guaranteed for the following reasons. First, major and minor palm creases were not strictly defined so that the relationships, branches, variants, and starting and termination points of major palm creases were not explicit. Second, the qualitative and quantitative analyses were not systematic, and not applied to the palm creases of a large sample (Alter 1970; Dar & Schmidt, 1976; Chaube 1977). The main purpose of this study was the

presentation of improved methods of analyzing palm creases, the features of which include the strict definition of the major and minor palm creases and the systematic classification of palm creases on the basis of their relationships, branches, and variants. The secondary purpose of this study was the application of the presented methods in this study to a large Korean sample, followed by more objective and detailed interpretation of the palm creases.

Materials and Methods

Both right and left palm creases of 3,216 volunteers (2,095 males and 1,121 females) who resided in Suwon, Korea were analyzed. The age range of the volunteers was from 17~29 years (average, 20 years). Volunteers with deformed hands and palm creases which could not be analyzed were excluded. The palms were cleansed with soap. After smearing stamp ink on the bilateral palms of the volunteers, they were imprinted on paper strongly enough to obviously show palm creases and distal ends of the palms. Sometimes, palm creases on the paper could not be appropriately analyzed due to poor

Corresponding author:

Min Suk Chung

Address: Worldcup-ro 164, Suwon, Korea [443-749]

Tel : +82-31-219-5032, Fax : +82-31-219-5039, E-mail : dissect@ajou.ac.kr

Copyright © 2010. Anatomy and Cell Biology

This is an Open Access article distributed under the terms of the Creative Commons Attribution Non-Commercial License (<http://creativecommons.org/licenses/by-nc/3.0/>) which permits unrestricted non-commercial use, distribution, and reproduction in any medium, provided the original work is properly cited.

printing conditions. In such cases, the palm creases were regarded as a missing value.

Palm creases were distinguished into major and minor creases. Major palm creases consist of radial longitudinal creases (I), proximal transverse creases (II), and distal transverse creases (III), which were further analyzed qualitatively and quantitatively. However, the minor palm creases were not analyzed and just observed (Fig. 1).

Major palm creases were classified in detail. Based on the relationship between I and II, palm creases were classified into closed, open, and meeting creases (Fig. 2). Based on the relationship between II and III, palm creases were classified

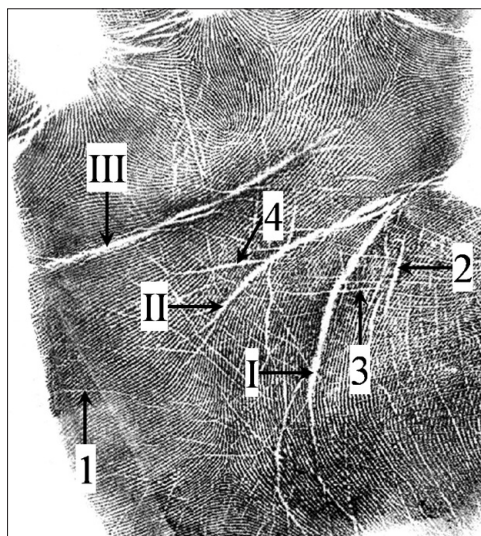


Fig. 1. Definition of major and minor palm creases. Major palm creases are defined as follows. Radial longitudinal crease (I) becomes distinct according to the flexion of carpometacarpal joints of the thumb. Proximal (II) and distal transverse creases (III) become distinct according to the flexion of the metacarpophalangeal joints of the second to fifth fingers. Minor palm creases are defined as palm creases which are narrower than the two times of the epidermal groove width in palmprints (1), apart from major palm creases (2), crossing major palm creases (3), or leading to major palm creases by the sharpened end (4).

into normal, simian, Sydney, and Suwon creases (Fig. 3). Furthermore, based on the branches of II and III, normal, simian, and Sydney creases were classified into subtypes (Fig. 4). Lastly, based on variants of I, II, and III, each major palm crease was classified (Fig. 5).

A grid was drawn on the palm print, and X and Y coordinates of the starting and termination points of I, II, and III were obtained. The total degree of transversality (T-DoT) of palm creases was calculated based on the methods of Dar and Schmidt (1976) (Fig. 6).

To compare the incidence of palm crease types between genders or between sides, a chi-square test was performed. To compare T-DoT between genders, an unpaired t-test was performed, and to compare T-DoT between sides, a paired t-test was performed. SPSS version 14 (SPSS Inc., Chicago, IL, USA) was used as the statistical software, and differences were considered significant at a $P < 0.05$.

Results

A closed crease based on the relationship between I and II was the most common crease, followed by open and meeting creases. Closed creases were more frequent in males than in females; in contrast, open and meeting creases were more frequent in females than in males (Table 1).

Concerning the relationship between II and III, normal creases were most common, followed by simian, Sydney, and Suwon creases. Normal creases were more frequent in females than in males; in contrast, the simian, Sydney, and Suwon creases were more frequent in males than in females. The Suwon crease was found only in males. Normal creases were more frequent in the left palm than in the right, while the simian crease was more frequent in the right palm than in the left palm (Table 2).

Simian 2, 4, and 5, decided by the branches of II and III,

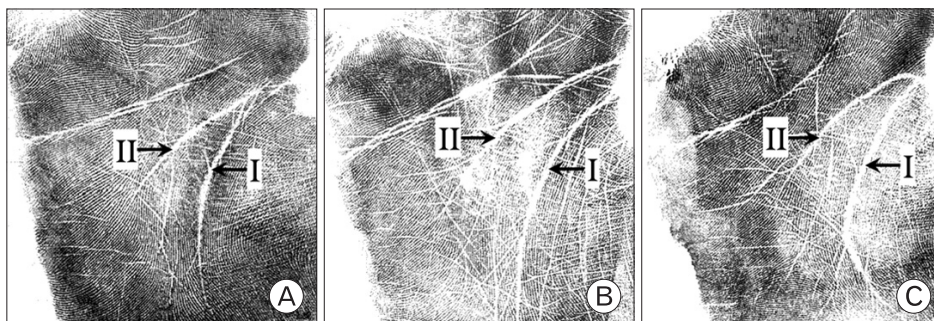


Fig. 2. Types of palm creases based on the radial longitudinal crease (I) and proximal transverse crease (II). Closed crease (A): I and II meet to form a common crease. Open crease (B): I and II do not meet. Meeting crease (C): I and II meet on the radial border of the palm.

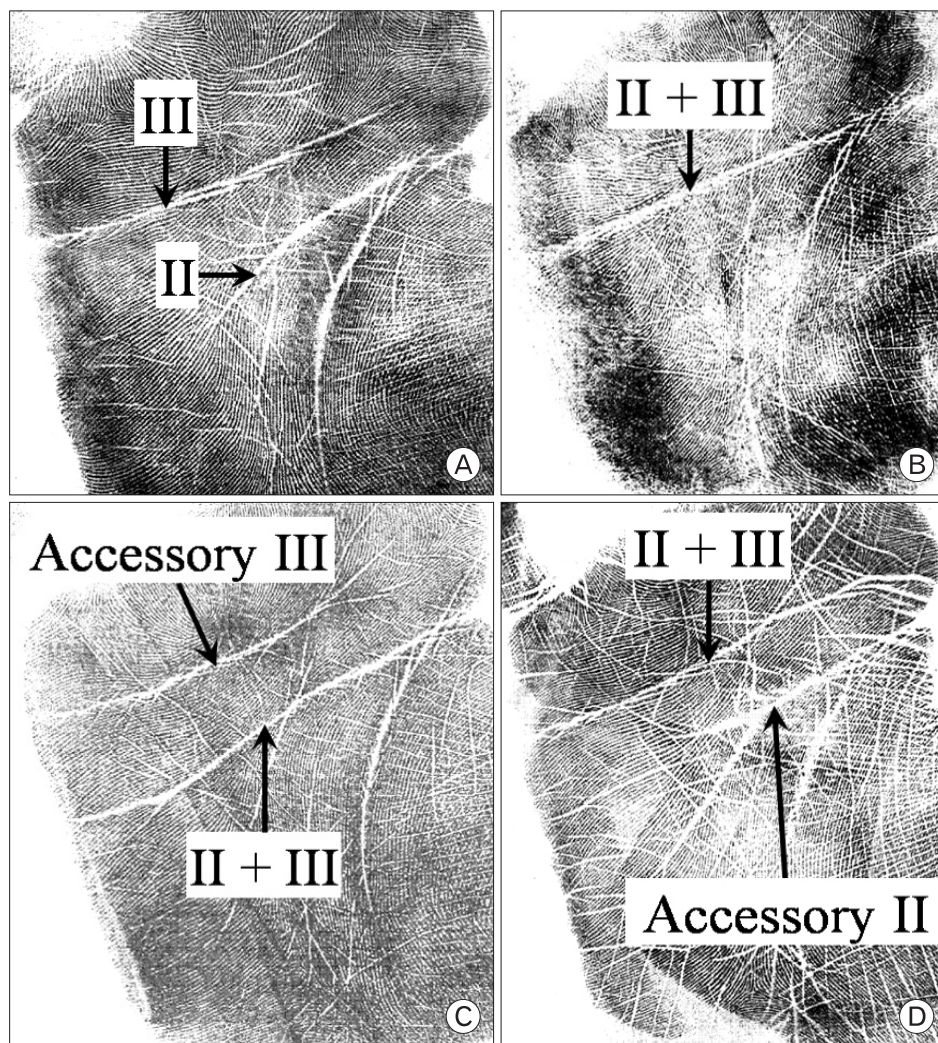


Fig. 3. Types of palm creases based on the relationship between the proximal transverse crease (II) and distal transverse crease (III). Normal crease (A): II and III do not meet. Simian crease (B): II and III meet to cross the palm. Sydney crease (C): II and III meet, accompanied by accessory III. Suwon crease (D): II and III meet accompanied by accessory II.

were frequent among simian subtypes, and Sydney 1 and 2 were frequent among Sydney subtypes. Simian subtypes with branches (Simian 2, 3, 4, and 5) were more frequent than Sydney subtypes with branches (Sydney 2, 3, 4, 5, and 6). Sydney subtypes with proximal branches (Sydney 2) were more frequent than Sydney subtypes with distal branches (Sydney 3, 5, and 6) (Table 3).

Among the variants of creases, branched and forked variants were frequent in I, II, and III, and an accessory variant was frequent in I. Branched, forked, and accessory variants were more frequent in I and III than in II (Table 4).

To reveal the frequent starting and termination points of palm creases, each X and Y coordinate was grouped by 10 units, and the incidences of the frequent starting and termination points are shown in Fig. 7. The termination points of I, II, and III were variable between individuals, while the starting points were constant.

The T-DoT of the Sydney crease was greatest, followed by the simian and normal creases. The T-DoT of normal and simian creases was greater in females than in males, and the T-DoT of normal creases was greater in the left palm than in the right palm (Table 5).

In some cases, major palm creases were not distinct, but minor palm creases were more distinct than usual (Fig. 8).

Discussion

Palm creases are of practical use because they can be analyzed quickly without physical pain, high costs, or age considerations (Caplan 1990).

Palm creases are helpful in revealing the anthropologic characteristics of the populations of different ethnic origins. For example, the frequencies of normal, simian, and Sydney

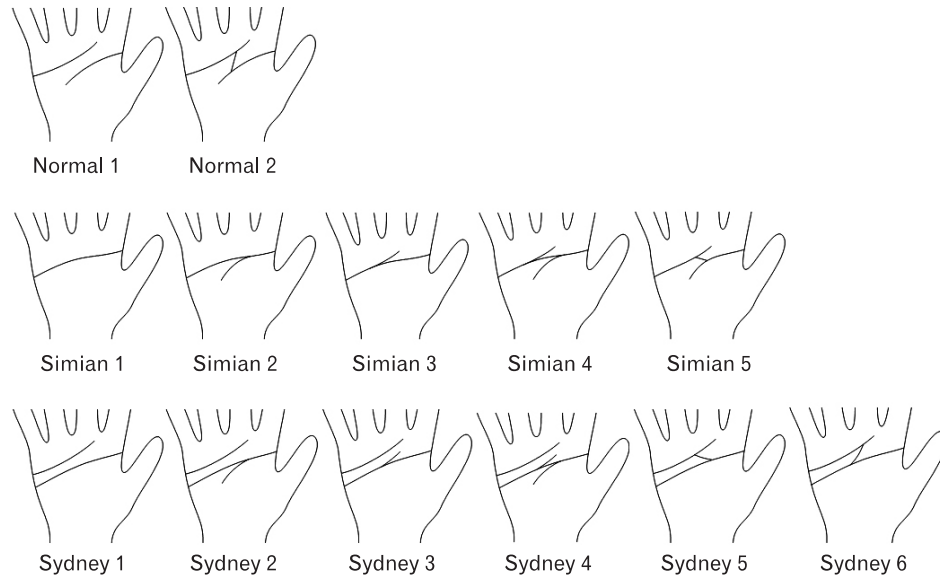


Fig. 4. Subtypes of normal, simian, and Sydney creases based on the branches of the proximal transverse crease (II) and distal transverse crease (III). Normal 1: II and III do not meet absolutely. Normal 2: II and III meet by recurrent branches of II, III. Simian 1: Branch of II or III does not exist. Simian 2: Proximal branch of II exists. Simian 3: Distal branch of III exists. Simian 4: Proximal branch of II and distal branch of III exist. Simian 5: II and III meet by branches of II and III. Sydney 1: Branch of II or III does not exist. Sydney 2: Proximal branch of II exists. Sydney 3: Distal branch of III exists. Sydney 4: Proximal branch of II and distal branch of III exist. Sydney 5: II and accessory III meet by branches of II and accessory III. Sydney 6: II and accessory III meet by the recurrent branches of II and accessory III.

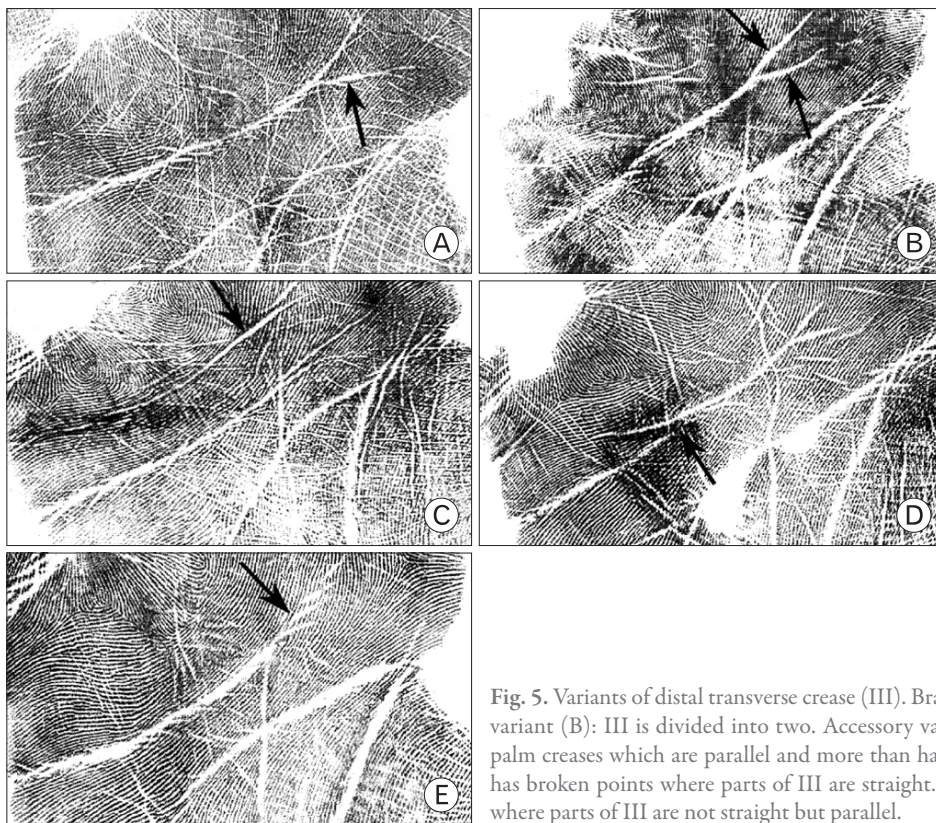


Fig. 5. Variants of distal transverse crease (III). Branched variant (A): III has branches. Forked variant (B): III is divided into two. Accessory variant (C): III is accompanied by accessory palm creases which are parallel and more than half of the III length. Broken variant (D): III has broken points where parts of III are straight. Cascade variant (E): III has broken points where parts of III are not straight but parallel.

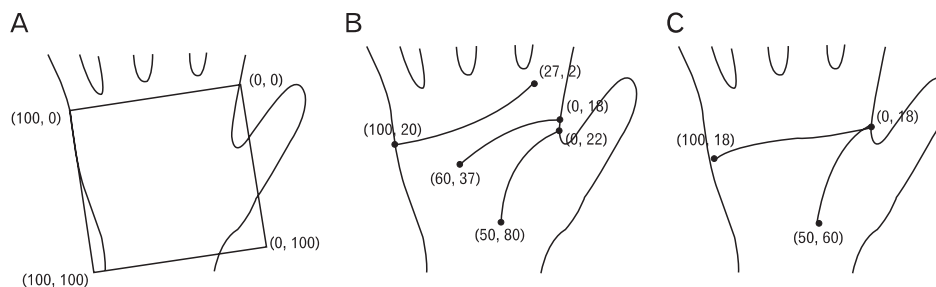


Fig. 6. X and Y coordinates of radial longitudinal crease (I), proximal transverse crease (II), distal transverse crease (III), and total degree of transversality (T-DoT). $T-DoT = (\text{the sum of X-axis distances of I, II, III}) / (\text{the sum of Y-axis distances of I, II, III})$. A grid drawn on the palm in the manner that the zero point (0, 0) of the grid is drawn on the distal and radial end of the palm, and the X-axis end point (100, 0) of the grid is drawn on the distal and ulnar end of the palm (A). An example of X and Y coordinates in normal crease. $T-DoT = (50 + 60 + 73) / (58 + 19 + 18)$ (B). An example of X and Y coordinates in the simian crease. $T-DoT = (50 + 100) / (42 + 0)$ (C).

Table 1. Incidence of closed, open, and meeting creases in Koreans according to sex and side

	Male		Female		Total
	Right	Left	Right	Left	
Closed crease	90.2%*	91.4%*	77.4%*	80.4%*	87.0%
Open crease	5.6%*	5.2%*	13.6%*	12.1%*	7.8%
Meeting crease	4.2%*	3.4%*	9.0%*	7.5%*	5.2%
Total	100.0% (1,836)	100.0% (1,696)	100.0% (877)	100.0% (787)	100.0% (5,196)

(Cases)
* $P < 0.05$ between male and female.

Table 2. Incidence of normal, simian, Sydney, and Suwon creases in Koreans according to sex and side

	Male		Female		Total
	Right	Left	Right	Left	
Normal crease	81.2%* [†]	83.5%* [†]	86.8%* [†]	91.1%* [†]	84.4%
Simian crease	15.6%* [†]	12.5%* [†]	11.4%* [†]	7.5%* [†]	12.6%
Sydney crease	2.8%* [†]	3.0%* [†]	1.8%* [†]	1.4%* [†]	2.5%
Suwon crease	0.4%* [†]	1.0%* [†]	0.0%	0.0%	0.5%
Total	100.0% (1,836)	100.0% (1,696)	100.0% (877)	100.0% (787)	100.0% (5,196)

(Cases)
* $P < 0.05$ between male and female, [†] $P < 0.05$ between the right and left palms.

creases are different between Caucasians and Negroes (Dar *et al.*, 1977). However, in the field of physical anthropology, palm creases are used less than fingerprints and palmprints because the methods of analyzing palm creases are not very objective (Eswaraiah & Bali, 1978; Tay 1979).

Table 3. Incidence of the subtypes of normal, simian, and Sydney creases in Koreans according to sex and side

	Male		Female		Total
	Right	Left	Right	Left	
Normal 1	91.2%	94.5%	94.5%	95.5%	93.5%
Normal 2	8.8%	5.5%	5.5%	4.5%	6.5%
Total	100.0% (1,493)	100.0% (1,418)	100.0% (761)	100.0% (717)	100.0% (4,389)
Simian 1	8.0%	9.4%	4.0%	8.5%	7.9%
Simian 2	32.2%	30.7%	20.0%	23.7%	29.0%
Simian 3	3.1%	2.4%	2.0%	3.4%	2.7%
Simian 4	23.8%	29.2%	21.0%	28.8%	25.5%
Simian 5	32.9%	28.3%	53.0%	35.6%	34.8%
Total	100.0% (286)	100.0% (212)	100.0% (100)	100.0% (59)	100.0% (658)
Sydney 1	25.0%	17.3%	43.8%	18.2%	23.8%
Sydney 2	66.7%	67.3%	56.2%	54.5%	64.6%
Sydney 3	2.0%	0.0%	0.0%	0.0%	0.8%
Sydney 4	5.9%	13.5%	0.0%	18.2%	9.2%
Sydney 5	0.0%	0.0%	0.0%	9.1%	0.8%
Sydney 6	0.0%	1.9%	0.0%	0.0%	0.8%
Total	100.0% (51)	100.0% (52)	100.0% (16)	100.0% (11)	100.0% (130)

(Cases)

Palm creases have additional features that might indicate the possibility of chromosomal aberrations. For example, simian creases are frequent and the T-DoT of simian creases is high in Down syndrome [trisomy 21] (Dar & Schmidt, 1976; Chung *et al.*, 2000). Palm creases are also useful for diagnosing intrauterine toxin exposure (Dar *et al.*, 1977), fetal alcoholic syndrome (Jones *et al.*, 2006), mental retardation (Dar & Jaffe, 1983), neoplasia (Oorthuys *et al.*, 1979; Edelstein *et al.*, 1991), and other diseases. For enhancing the diagnostic

Table 4. Incidence of the variants of I, II, and III in Koreans according to sex and side

		Male		Female		Total
		Right	Left	Right	Left	
I	Non-variant	77.7%	79.5%	79.0%	84.2%	79.5%
	Branched	5.8%	7.2%	6.0%	3.8%	6.0%
	Forked	10.3%	7.5%	6.7%	4.2%	7.9%
	Accessory	4.0%	4.8%	7.3%	7.0%	5.2%
	Broken	2.1%	0.9%	1.0%	0.8%	1.3%
	Cascade	0.1%	0.1%	0.0%	0.0%	0.0%
	Total	100.0% (1,837)	100.0% (1,700)	100.0% (877)	100.0% (787)	100.0% (5,201)
II	Non-variant	85.5%	87.1%	85.2%	84.1%	85.7%
	Branched	7.3%	7.3%	8.4%	8.8%	7.7%
	Forked	5.8%	4.6%	5.0%	5.3%	5.2%
	Accessory	0.4%	0.3%	0.8%	0.7%	0.5%
	Broken	1.0%	0.7%	0.5%	1.0%	0.8%
	Cascade	0.0%	0.0%	0.1%	0.1%	0.0%
	Total	100.0% (1,501)	100.0% (1,436)	100.0% (761)	100.0% (717)	100.0% (4,415)
III	Non-variant	70.3%	69.7%	73.2%	72.4%	70.9%
	Branched	16.6%	14.5%	15.6%	15.1%	15.5%
	Forked	9.8%	11.4%	9.0%	9.1%	10.1%
	Accessory	0.6%	0.7%	0.6%	1.0%	0.7%
	Broken	1.7%	2.2%	1.5%	1.4%	1.8%
	Cascade	1.0%	1.5%	0.1%	1.0%	1.0%
	Total	100.0% (1,544)	100.0% (1,471)	100.0% (777)	100.0% (728)	100.0% (4,520)

(Cases)

value of palm creases, the methods of analyzing palm creases should be objective.

The methods of analyzing palm creases can be divided into qualitative and quantitative methods. The qualitative analysis consists of classifying types of palm creases based on the relationship, branches, and variants of palm creases (Alter 1970; Chaube 1977; Dar *et al.*, 1977). The quantitative analysis consists of calculating the T-DoT after identifying the starting and termination points of palm creases (Dar & Schmidt, 1976).

In this study, we presented more objective methods for analyzing palm creases, applied to the analysis of 3,216 Korean palm creases. The improved manner has the following features.

First, major and minor palm creases are strictly defined. Major palm creases are defined as those becoming distinct according to the flexion of the carpometacarpal joint of the thumb and the flexion of the metacarpophalangeal joints in

the other fingers (Fig. 1). To define the major palm creases more strictly, the remnants (the minor palm creases) must be defined simultaneously.

Minor palm creases are divided into two categories. In one category, minor palm creases are defined as palm creases narrower than twice of the epidermal groove width. The width of palm creases is in direct proportion to the width of epidermal groove of palmprints, and both widths are in inverse proportion to the amount of stamp ink smeared on the palm. Therefore, the epidermal groove of palmprints provides useful criteria for defining minor palm creases (Dar & Schmidt, 1976). In the other category, minor palm creases are defined as palm creases apart from major palm creases, crossing major palm creases, or connecting to the major palm creases by the sharpened end. The minor palm creases definitely have a different size, number, and direction from major palm creases (Fig. 1).

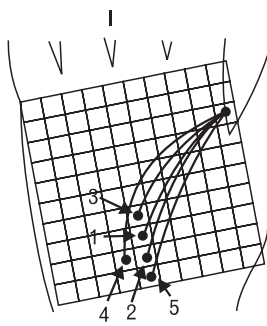
The second feature of the improved methods is the systematic classification of palm creases based on the relationship, branches, and variants of I, II, and III (Figs. 2~5). For example, while the previous method used the relationship between I and II, and that of II and III simultaneously to classify palm crease types (Chaube 1977), the improved method uses the relationship between I and II, and the relationship between II and III separately. In another example, while the previous method used different principles to classify palm crease subtypes (Alter 1970; Dar *et al.*, 1977), the improved method uses a consistent rule. Furthermore, the new method names the types and subtypes of palm creases scientifically.

Systematic classification of palm crease types introduces a new type which has not been previously reported. The new logical type of palm creases shows that II and III meet, accompanied by accessory II (Fig. 3), and occurs with an incidence of 0.5% (Table 2). This new type has been named 'Suwon crease' because it was first found in Suwon, Korea, like the 'Sydney crease' that was first found in Sydney, Australia (Purvis-Smith & Menser, 1968).

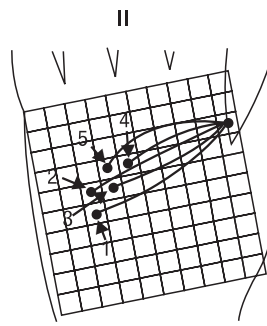
The third feature of the enhanced methods is the systematic analysis of the starting and termination points of palm creases for quantitative analysis. While the previous method only used X and Y coordinates to calculate the T-DoT of palm creases (Dar & Schmidt, 1976), the new method uses those not only to calculate the T-DoT, but also to reveal the frequent starting and termination points of palm creases (Fig. 7).

The improved methods were applied to numerous palm

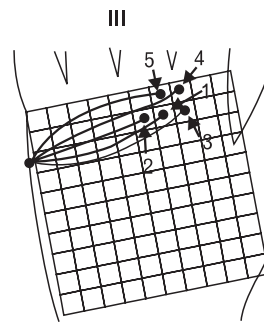
Normal crease (4,390 cases)



1 (18.2%), 2 (13.3%),
3 (11.4%), 4 (6.6%),
5 (5.4%), Others (45.1%)

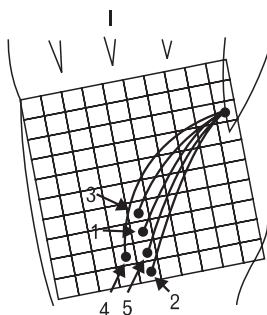


1 (23.2%), 2 (10.4%),
3 (9.9%), 4 (8.3%),
5 (7.7%), Others (40.5%)

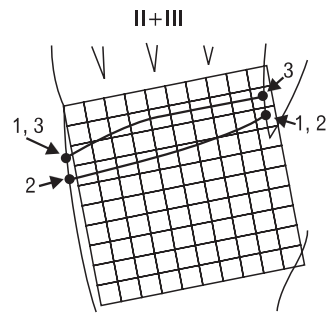


1 (18.7%), 2 (15.0%),
3 (14.2%), 4 (9.0%),
5 (6.4%), Others (36.7%)

Simian crease (657 cases)

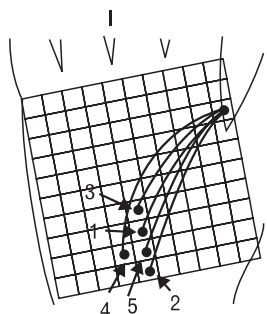


1 (16.0%), 2 (13.2%),
3 (10.4%), 4 (7.6%),
5 (5.9%), Others (46.9%)

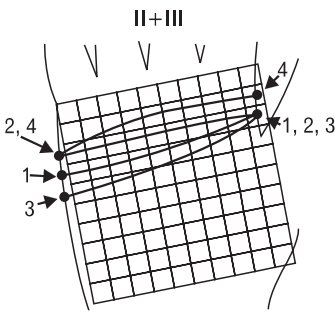


1 (59.5%), 2 (21.9%),
3 (7.2%), Others (1.4%)

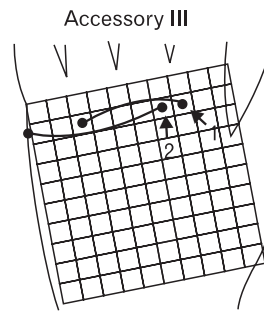
Sydney crease (129 cases)



1 (16.3%), 2 (15.5%),
3 (9.3%), 4 (7.0%),
5 (6.2%), Others (45.7%)



1 (33.3%), 2 (27.1%),
3 (13.2%), 4 (5.4%),
Others (21.0%)



1 (7.7%), 2 (4.7%),
Others (87.6%)

Fig. 7. Incidences of the starting and termination points of the radial longitudinal crease (I), proximal transverse crease (II), and distal transverse crease (III) of normal, simian, Sydney creases in Koreans. Numbers 1, 2, 3, 4, 5 in illustration mean frequent cases of the individual palm creases.

creases of Koreans, and then palm creases were interpreted anthropologically as follows.

The role of palm creases, which facilitates folding of palm skin for free hand movement, can be verified by the following facts. Palm creases are more distinct than sole creases because hand movement is freer than foot movement. Palm creases of

humans are more prominent than those of animals because the hand movement of humans is freer than that of animals. The monkey has simian creases because the thumb is flexed in the same direction as the other fingers when the monkey grasps a stick (Popich & Smith, 1970).

There is a tendency for palm creases to be evenly

Table 5. Total degree of transversality (T-DoT) of normal, simian, and Sydney creases in Koreans according to sex and side

	Male			Female		
	Cases	Right	Left	Cases	Right	Left
Normal crease	1,162	2.18±0.39% ^{*†}	2.23±0.41 ^{*†}	566	2.24±0.47 ^{*†}	2.34±0.48 ^{*†}
Simian crease	96	2.83±0.88	2.84±0.86 [*]	26	2.97±0.95	3.11±0.99 [*]
Sydney crease	19	3.10±0.69	2.98±0.65	4	3.23±0.54	2.91±0.89

*P<0.05 between male and female. †P<0.05 between the right and left palms.

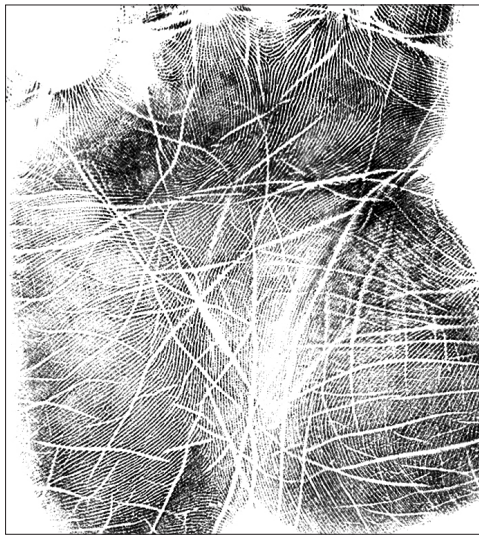


Fig. 8. A case in which the major palm creases are not distinct, but the minor palm creases are distinct.

distributed on the palm. This tendency is consistent with the role of palm creases, and verified by the following results. First, minor palm creases are distinct in cases that major palm creases are not distinct (Fig. 8) because minor palm creases may supplement the role of major palm creases. Second, Sydney creases are more frequent than Suwon creases (Table 2) because Sydney creases have accessory III, which is not close to any major palm creases, while Suwon creases have accessory II, which is close to I (Fig. 3). Third, simian creases have more branches than Sydney creases (Table 3; Fig. 4) because simian creases have two major palm creases, and Sydney creases have three major palm creases (Fig. 3). Fourth, Sydney creases have more proximal branches than distal branches (Table 3; Fig. 4) because Sydney creases have distally-located accessory III (Fig. 3). Fifth, the branched, forked, and accessory variants occur less in II than in I and III (Table 4; Fig. 5) because II intervenes between I and III.

Union of major palm creases is likely to be caused by powerful hand grip because of the following results. Closed, simian, Sydney, and Suwon creases, in which major palm

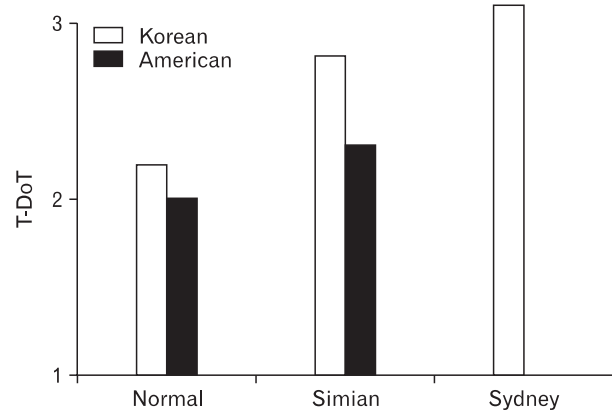


Fig. 9. Total degree of transversality (T-DoT) of normal, simian, and Sydney creases in Koreans and Americans. American Sydney creases are not reported (Dar & Schmidt, 1976).

creases were united (Figs. 2 and 3), were frequent in males and the right palm (Tables 1 and 2), both of those are known to have powerful hand grip, and these results are consistent with other studies (Davies 1966; Dar *et al.*, 1977). To clarify this, it is necessary to analyze palm creases according to the power, handedness, and habit of hands.

The T-DoT was different according to palm crease type, sex, and tribe. The T-DoT of the Sydney crease was greatest, followed by that of the simian and normal creases (Table 5; Fig. 9). These results seem to happen because T-DoT is in proportion to the number of transversally-passing palm creases (Fig. 6). T-DoT was greater in females than in males, and was greater in Koreans than in Americans (Table 5; Fig. 9). These results seem to happen because T-DoT is in proportion to the ratio of palm width to palm length, which may be different according to sex and tribe. To make this matter clear, the relationship between T-DoT and palm measurements should be further studied.

In this study, improved methods of analyzing palm creases were presented: The enhanced methods include the strict definition of major palm creases and the well organized analyses of major creases, which have not been attempted

before. Successively, the results of palm creases from more than 3,000 subjects were interpreted anthropologically. The better methods of analyzing palm creases are hopefully used for revealing anthropologic characteristics and for diagnosing chromosomal aberrations.

References

- Alter M. (1970). Variation in palmar creases. *Am J Dis Child* 120: 424-431
- Caplan RM. (1990). How fingerprints came into use for personal identification. *J Am Acad Dermatol* 23: 109-114
- Chaube R. (1977). Palmar creases in population studies. *Am J Phys Anthropol* 47: 7-9
- Chung MS, Kim YS, Kim HJ, Sohn HJ, Han HS. (2000). Dermatoglyphic characteristics of the Korean patients with numeral aberrations of chromosome. *Korean J Phys Anthropol* 13: 31-38
- Dar H, Jaffe M. (1983). Dermatoglyphic and palmar-crease alterations as indicators of early intra-uterine insult in mental retardation. *Dev Med Child Neurol* 25: 53-59
- Dar H, Schmidt R. (1976). Topographic approach for analysis of palm crease variants. *J Med Genet* 13: 310-313
- Dar H, Schmidt R, Nitowsky HM. (1977). Palmar crease variants and their clinical significance: a study of newborns at risk. *Pediatr Res* 11: 103-108
- Davies PA. (1966). Sex and the single transverse palmar crease in newborn singletons. *Dev Med Child Neurol* 8: 729-734
- Edelstein J, Amylon M, Walsh JA. (1991). Dermatoglyphics and acute lymphocytic leukemia in children. *J Pediatr Oncol Nurs* 8: 30-38
- Eswaraiah G, Bali RS. (1978). Palmar flexion creases and dermatoglyphics in leprosy patients. *Int J Lepr Other Mycobact Dis* 46: 56-60
- Jones KL, Robinson LK, Bakhireva LN, et al. (2006). Accuracy of the diagnosis of physical features of fetal alcohol syndrome by pediatricians after specialized training. *Pediatrics* 118: e1734-1738
- Oorthuys AM, de Vaan GA, Behrendt H, Geerts SJ. (1979). Palmar flexion creases in childhood neoplasia. *Cancer* 43: 749-759
- Popich GA, Smith DW. (1970). The genesis and significance of digital and palmar hand creases: preliminary report. *J Pediatr* 77: 1017-1023
- Purvis-Smith SG, Menser MA. (1968). Dermatoglyphics in adults with congenital rubella. *Lancet* 2: 141-143
- Tay JS. (1979). The genetics of palmar creases. A study in the inheritance of liability estimated from the incidence among relatives. *Ann Hum Genet* 42: 327-332