

Clinical evaluations of mineralized collagen in the extraction sites preservation

Lu Feng^{1,2,†}, Liang Zhang^{3,†}, Yun Cui⁴, Tian-Xi Song⁴, Zhi-Ye Qiu^{4,5}, Xiu-Mei Wang^{5,*} and Bao-Sheng Tan^{2,*}

¹Department of Stomatology, Dongzhimen Hospital, Beijing University of Chinese Medicine, Beijing 100700, China;

²Beijing Stomatological Hospital, Capital Medical University, Beijing 100050, China; ³Second Outpatient Department, General Hospital of Beijing Military Region, Beijing 100125, China; ⁴Beijing Allgens Medical Science and Technology Co., Ltd., Beijing 100176, China; ⁵State Key Laboratory of New Ceramics and Fine Processing, School of Materials Science and Engineering, Tsinghua University, Beijing 100084, China

[†]These authors contributed equally to this work.

*Correspondence address. Tel: +86-10-62772850; Fax: +86-10-62772850; E-mail: wxm@mail.tsinghua.edu.cn and Tel: +86-10-57099178; Fax: +86-10-57099178; E-mail: dentisttan1006@163.com

Received 11 October 2015; revised 13 November 2015; accepted 16 November 2015

Abstract

The purpose of this study was to explore the different effects between biomimetic mineralized collagen (MC) and ordinary physically blended hydroxyapatite/collagen (HA/Col) composite in evaluating new bone formation and regenerated bone height in human extraction sockets. Thirty-four patients who cannot retain teeth caused by trauma or decay were randomly selected from Department of Stomatology of Dongzhimen Hospital from December 2013 to December 2014. The patients were randomly divided into two groups. After the operation of tooth extraction, 17 patients were implanted with biomimetic MC (MC group), and other 17 patients were implanted with ordinary physically blended nHA/Col composite (nHA/Col group). X-ray positioning projection by auto-photographing was taken to test the distance between the lowest position and the neighboring CEJm-CEJd immediately, 1 month and 3 months after the operation. The height of new bone formation of the MC group was significantly higher than the nHA/Col group. Biomimetic MC showed better clinical outcomes in the bone formation for extraction site preservation and would have broad application prospect in the field of oral and maxillofacial surgeries.

Keywords: mineralized collagen; biomimetic; extraction site preservation; bone formation height

Introduction

With the development of stomatology and material science, the rates of successful implanting supported denture are more and more higher, and these applications are widely accepted by more and more patients. At the same time, it is particularly necessary for an adequate of bone volume in the implant spot, because it is not only related to the success rate of implant surgery but also in terms of the aesthetic of gum soft tissue [1]. Clinicians prefer to conduct bone grafting at the time of tooth extraction for these patients who have an inadequate bone around the dental implant placement, thus can maximize to conserve bone volume and shorten the cycle of treatment.

Sites preservation [2] is a feasible method to solve the problem of lower bone level and long duration treatment, in which autologous bone, allogeneic bone or biological materials are placed in the extracted tooth socket following extraction. However, these materials have exhibited various shortcomings, such as the autologous bone from iliac bone has a satisfactory clinical effect and is regarded as a 'gold standard', but the source of autologous bones is limited, pain and infection in donor site are often associated with bone grafting. Also, allogeneic bone transplantation has some problems such as immunological rejection, cross infection of disease and ethical issues. So, tissue engineering expert researches were focused on the development of organic and/or inorganic compound. At present, internationally bone substitute




Figure 1. (a) Scanning electron microscope (SEM) images of MC. (b) The morphology of MC

materials researches focus on biological ceramic, polymer such as collagen (Col) and high molecular compound and hydroxyapatite (HA)/Col composite materials. But biological ceramic and polymer has some defects is difficult to meet the requirements of bone reconstruction and clinical applications. And mineralized collagen (MC) is the building blocks for various connective tissues such as bone, cartilage, tendon and dentin [3–5], therefore the research of nano-HA/Col (nHA/Col) composites which assemble organizational structure and function has become hot research area of artificial bone substitute materials [3, 6, 7].

Cui and co-workers [8] designed hierarchical self-assembly of MC nano-fibrils, which has natural bone like in terms of both the composition and the microstructure. The structure was consistent with the hierarchical structure of the self-assembled MC composite as described by Landis *et al.* [9], and the structure was demonstrated by conventional and high-resolution transmission electron microscopy for the first time [8]. Due to their biocompatibility, composition and structure are more similar to the natural bone, which in theory will be more popular and show more obvious advantages compared with the ordinary physically blended hydroxyapatite/Col (HA/Col) composite [10].

In this work, we explored the different effect between biomimetic MC and ordinary physically blended HA/Col composite result in evaluated new bone formation in human extraction sockets and bone height.

Experimental

Materials

The biomimetic MC implants were produced by Beijing Allgens Medical Science & Technology Co., Ltd. The implants were fabricated into extraction socket plug, which were easy to use by a dentist during the operation. The MC used in this study was hierarchical self-assembled nHA/Col composite, which has the same composition and microstructure with the nature bone and synthesized via an *in vitro* biomimetic mineralization process. As described by previously published literatures [8, 11], during the process of *in vitro* biomimetic mineralization, HA crystals grew on the surface of the Col fibrils with triple helices and their crystallographic *c*-axes oriented along the longitudinal axes of the fibrils to form MC fibrils. Then the MC fibrils aligned parallel to each other to form MC fibers. Such MC were collected and made into extraction socket plugs possessing a sponge-like structure with interconnected three-dimensional pores, Fig. 1b. As shown in Fig. 1a, the pore size was

100–400 μm , and the porosity was tested to be 90% [12]. These structures could provide sufficient space for cell adhesion, proliferation and osteoblast differentiation, which would accelerate the process of bone healing.

HA/Col bone graft material was provided by School of Materials Science and Engineering, Tsinghua University. The HA/Col material used in this study only has the same composition with the nature bone, the two component of hydroxyapatite and Col are physically blended and not biomimetic synthesis. Besides, its porosity is lower than the MC material.

Method

Patient selection: A total of 28 patients with 34 implants aged from 18 to 79 years were randomly selected from department of stomatology of Dongzhimen hospital from December 2013 to December 12, who cannot to retain the teeth caused by trauma or decay.

Accepting criteria: (i) All patients were systemically healthy, no tooth extraction contraindications; (ii) patients had intact four walls bone after tooth extraction and no bad granulation tissues in the extraction sockets and (iii) Patients were without active periodontitis and had a good oral hygiene.

These patients were randomly divided into two groups, group A was implanted with MC material and group B was implanted with HA/Col material. These patients should signature on the operation agreement and the experiment consent form before the operation.

Surgical procedures: Local mucosa was disinfected with Tincture of iodine and the periosteum of the tooth extraction sites was anaesthetized with 3% Articaine; separated the gums from the teeth, loosened and extracted the teeth, curetted the extraction sockets and made sure that there is no bad granulation tissue in the socket and had intact four walls bone, the extraction sockets were grafted with MC material and HA/Col material randomly. The top of the gums were sutured 2–3 stitches with interrupted suture or 8-character-pattern to prevent the bone fillings fall out.

Evaluate the means: X-ray (SINORA HELIODENT Vario, Made in Germany) positioning projection by auto-photographing was taken to test the bone formation height, observe the speed and the quality of bone formation immediately, 1M and 3M after operation.

Measurement method: Take the connective line of the cemento-enamel junction of neighboring tooth on the mesial and distal sides (CEJm-CEJd) AB as the baseline, the lowest position on alveolar ridge defect as C point, and line of CD was perpendicular to the line of AB (Fig. 2). The distance of CD was measured at 1M and 3M after operation.

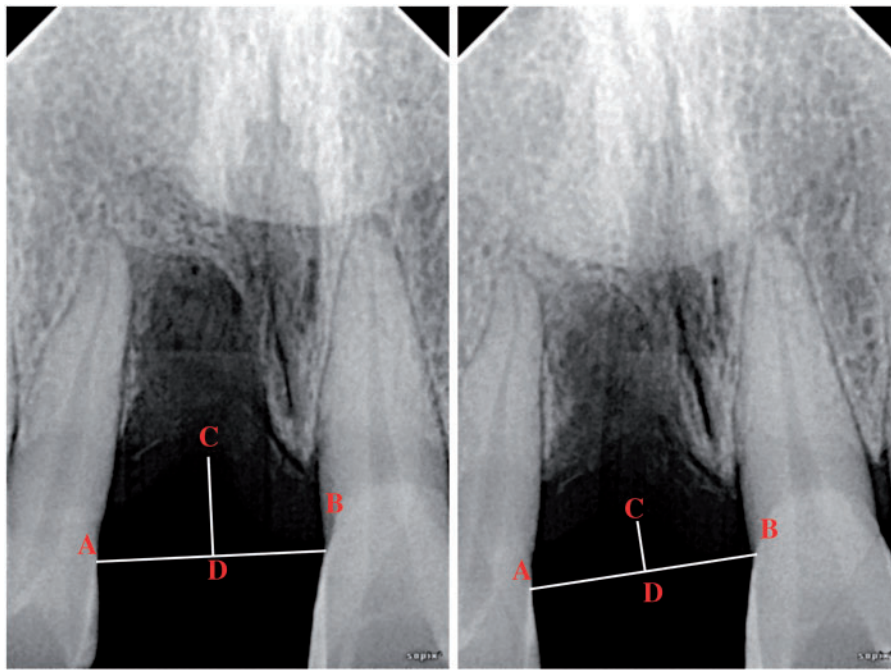


Figure 2. The measurement method of test and the distance between the lowest position and the neighboring CEJm-CEJd after operation

Statistical analysis: Using SPSS18.0 statistical software for statistical analysis, distributions of variables were given as the mean and the standard deviation. The measurement data used variance test, counting card information using the test, the comparison of proportions using Fisher exact probability test. $P < 0.05$ represents the difference was statistically significant.

Results

We collected 28 patients with 34 implants in total. Group A included 13 patients with 17 implants, implanted with MC material produced by Beijing Allgens Medical Science & Technology Co., Ltd, group B included 15 patients with 17 implants, implanted with HA/Col material produced by School of Materials Science and Engineering, Tsinghua University. The accomplished cases of the two types of materials at different sites are listed in Table 1.

The influence of the two types of materials on bone formation height

The distance between the lowest position and the neighboring CEJm-CEJd was measured after the two types of materials were implanted into the tooth extraction sockets for 1 month and 3 months, the data are listed in Table 2. The height differences of group A is obviously higher than the control group B, which demonstrated that the bone formation height of group A was higher than group B in 1 month to 3 months. The data of the bone formation height of the two types of materials in site preservation were statistically analyzed in further, listed in Table 3.

For the factor of method, $F = 15.62$, $P = 0.0004 < 0.05$, the differences were statistically significant, which demonstrated that the MC material could be more effectively in preserving the height of alveolar bone than HA/Col material after tooth extractions. But for the method of time, $F = 0.26$, $P = 0.6171 > 0.05$, the differences did not achieve statistical significance, suggested that the MC material had no significant advantages at the same time after surgery

Table 1. Accomplished cases of the two types of materials at different sites and different sexes

Tooth position	Type A		Type B		Total
	M	F	M	F	
Front teeth	3	3	3	3	12
Molar	3	3	3	3	12
Premolar	3	2	2	3	10

Table 2. The distance between the lowest position and the neighboring CEJm-CEJd of the two types of materials at different times (cm)

Object of observation (implantation site)	A			B		
	1 M	3M	Height differences	1M	3M	Height differences
1	1.51	1.35	0.16	2.36	2.73	-0.37
2	0.62	0.34	0.28	1.76	1.70	0.06
3	1.81	1.73	0.08	2.25	2.54	-0.29
4	1.93	1.08	0.85	2.59	2.68	-0.09
5	1.93	0.62	1.31	1.86	2.23	-0.37
6	0.57	0.61	-0.04	2.07	2.32	-0.25
7	2.16	2.00	0.16	2.39	2.45	-0.06
8	3.00	2.97	0.03	1.96	2.02	-0.06
9	0.98	0.32	0.66	2.98	2.72	0.26
10	1.00	0.81	0.19	1.75	1.53	0.22
11	1.56	1.02	0.54	2.38	2.65	-0.27
12	1.35	1.25	0.1	1.55	1.82	-0.27
13	0.69	0.45	0.24	1.07	1.55	-0.48
14	1.68	1.35	0.33	1.05	1.54	-0.49
15	1.87	1.54	0.33	1.37	1.81	-0.44
16	2.00	1.88	0.12	1.87	1.94	-0.07
17	1.69	1.46	0.23	2.16	2.62	-0.46
$\bar{x} \pm s$				0.33 ± 0.12		-0.20 ± 0.05

compared to the HA/Col material. Research on synthetical two factors method it showed statistically significant, $F = 34.01$ $P < 0.0001$, the results illustrated that the longer time implanted the better osteogenesis effects obtained, the alveolar bone height 3 months after surgery was higher than 1 month after surgery when the same type of material implanted into the teeth extraction sockets, the results was accorded with the fundamental rules of bone remodeling of human.

Figure 3 exhibited two typical cases implanted with MC and HA/Col material. A, female, aged 64 years, implanted with MC material after removal of the mandibular left lateral incisor tooth and the mandible right lateral incisor tooth. B, female, aged 35 years, implanted with HA/Col material after removal of the maxillary right lateral incisor tooth. We can found that both new-bone formation height and density of case A were superior to case B at the same time by gross observation.

Table 3. The contrasting results of the bone formation height of the two types of materials

Effect	Num DF	Den DF	F Value	Pr > F
Type	1	31	15.62	0.0004
Time	1	31	0.26	0.6171
Type*time	1	31	34.01	<.0001

The height and width of the new bone formation of some cases who are willing to dental implantation were measured by CT immediately and 3 months after surgery. Figure 4 shows a male aged 47 years implanted with MC material after removal of the mandibular right third molar. Spiral CT three-dimensional reconstruction and measurement of the height and width of new bone formation, each cases selected six point. The mean height and width of new bone formation at the 3rd month are 0.84 ± 0.0046 mm and 0.47 ± 0.11 mm, respectively. Through statistics of the other four cases who were examined with CT, we found that the mean height and width of new bone formation who were implanted with MC were superior to those implanted with HA/Col material in general.

The speed of new bone formation of the two types of materials

The morphology of the contact interface between the surrounding tissue and the implanted material was observed by X-ray Micro-Computed Tomography, and the number of the cases that the morphological change at different time is listed in the Table 4.

The morphological change of the two types of materials at different time was further statistically analyzed, listed in Table 5. Chi-square = 0.9089, $P = 0.3404$, the difference between the two groups were not statistically significant. The contact interface of the two

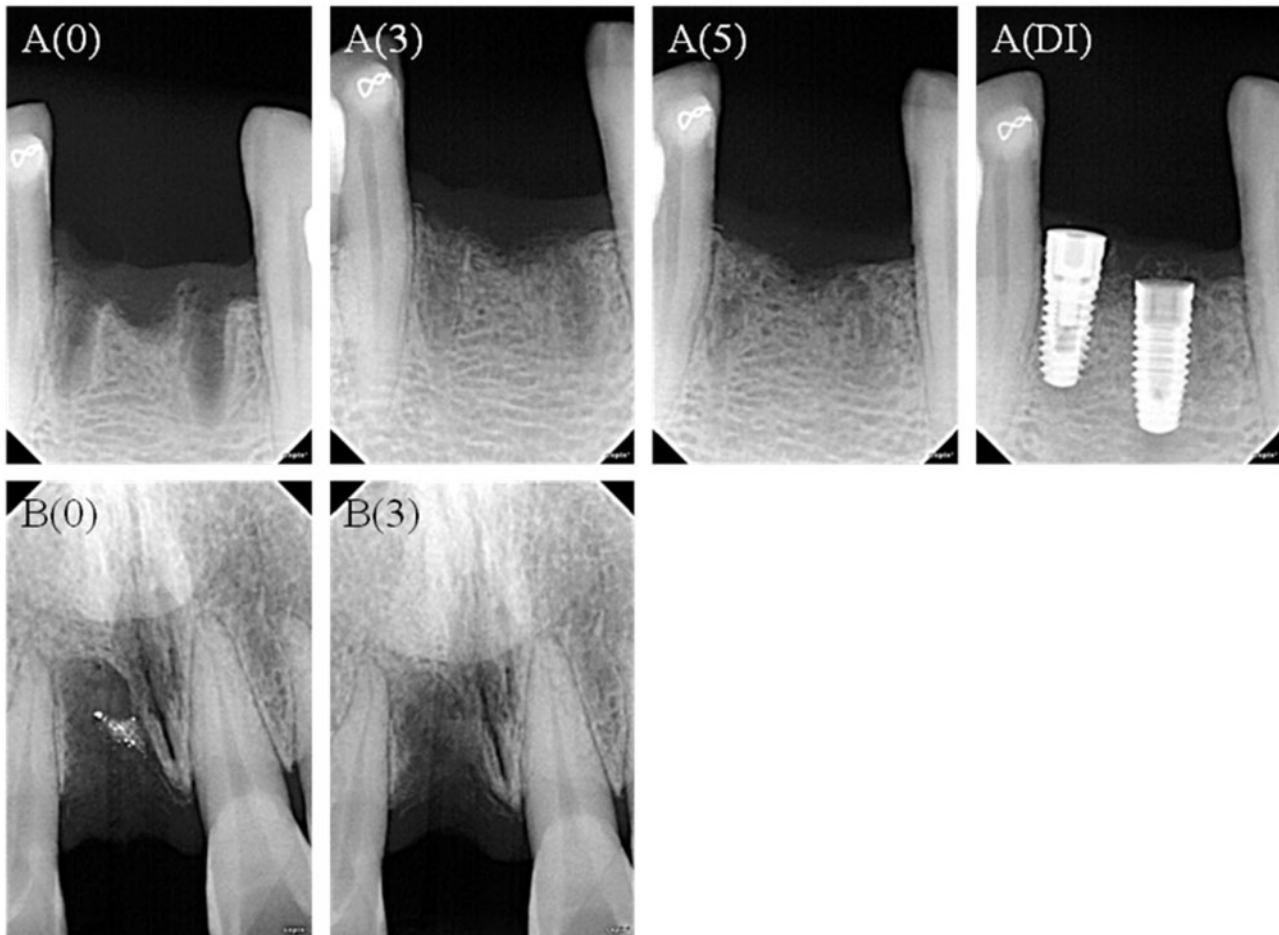


Figure 3. The X ray film of two typical cases implanted with MC and HA/col material. A(0): immediately after surgery; A(3) and B(5): implanted with MC material 3 months and 5 months after surgery; A(DI): dental implants after implanted with MC material 5 months; B(0): immediately after surgery; B(3): implanted with HA/col material 3 months after surgery

groups became ambiguous from 1 month, so could be speculated that the time of morphological change is the start of new bone formation. The MC material had no advantage in speed of osteogenesis than the HA/Col material.

The speed of new bone formation of the two types of materials

The distance between the lowest position and the neighboring CEJm-CEJd was measured after the two types of materials implanted into the tooth extraction sockets 1 month and 3 months, the difference between different implanted sites and different sexes were compared. Data are listed in Table 6.

The results of the influence that materials implanted in different sites and different sexes to the osteogenesis effects were statistically analyzed as presented in Tables 7 and 8. The interaction of style and time is 0.000, below the 0.05 threshold, had statistical significance. All values of interactions in the last column are greater than 0.005,

except Time*Type, and illustrated that the MC material is higher than HA/Col material in terms of new bone formation in 1–3 months but could not demonstrate that bone formation was related to the different implantation sites and sex.

Discussion

Healing of extraction sockets

Healing of extraction sockets is characterized by internal change and external change, the former manifest as lead to formation of bone within the socket and the latter manifest as lead to loss of alveolar ridge width and height [13]. So resorption and reconstruction of the external buccal and lingual socket walls result in a change in the dimensions of the ridge, this change may lead to the width and height of the alveolar ridge down and further affect the optimal implant aesthetics. The process of the healing of extraction sockets was first proposed by Steinhardt in 1932, and through the in-depth study

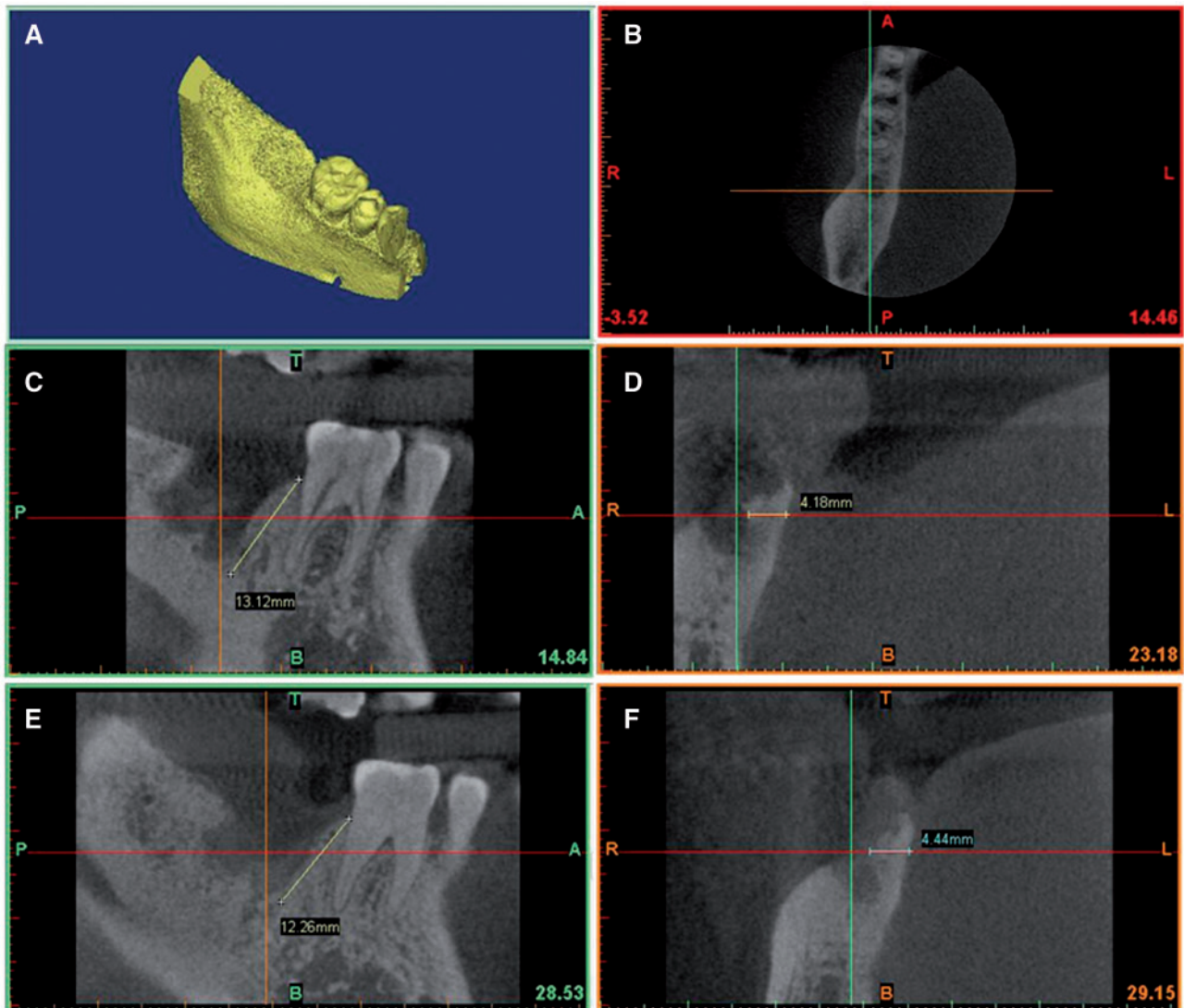


Figure 4. Spiral CT three-dimensional reconstruction and measurement of the height and width of new bone formation for one case implanted with MC immediately and 3 months after surgery. (A) Three-dimensional reconstruction immediately after surgery. (B) Three-dimensional localization both horizontally and vertically. (C and D) The depth and width of teeth extraction socket immediately after surgery. (E and F) The depth and width of teeth extraction socket 3 months after surgery

Table 4. The comparison of the morphological change of the teeth extraction sockets with time

Groups	1M change	1M no change	3M change	3M no change
A	8	9	15	2
B	5	12	14	3
Total	13	21	29	5

Table 5. The contrasting results of the time of morphological change of the teeth extraction sockets

Statistic	Degree of freedom	Value	Probability
Chi-square	1	0.9089	0.3404
Likelihood ratio chi-square	1	0.9148	0.3389
Continuous correction chi-square	1	0.3361	0.5621
Mantel-Haenszel chi-square	1	0.8776	0.3489
Phi coefficient		0.1770	
Coefficient of association		0.1743	
Cramer's ν		0.1770	

Table 6. The height differences in 1–3 months between the lowest position and the neighboring CEJm-CEJd after the two types of materials implanted in different sites, different sexes and different times (cm)

	Type	Cases	Male		Female	
			Cases	Height differences	Cases	Height differences
Front teeth	A	3		0.23 ± 0.017	3	0.71 ± 0.47
	B	3		-0.2 ± 0.052	3	-0.24 ± 0.019
Molar	A	3		0.28 ± 0.11	3	0.28 ± 0.054
	B	3		0.047 ± 0.034	3	-0.11 ± 0.080
Premola	A	3		0.24 ± 0.0072	2	0.18 ± 0.0061
	B	3		-0.47 ± 0.0007	2	-0.27 ± 0.076

of other scientists, the healing of extraction sockets can be divided into five stages [14]: The first stage, hemorrhage and formation blood clot: stop the bleeding within 15–30 min followed by formation of blood clot that fills the entire socket to prevent the infection of wound and promote wound healing; The second stage, the clot stimulates the granulation tissue formation: the gums begin to shrink within a few hours after extraction, vascular endothelial cells and fibroblasts begin proliferate after 24 h, the granulation tissue replaced the blood clot completely about 7 days. The third stage, the granulation tissue is replaced by connective tissue and epithelial tissue: the connective tissue matures gradually within 5–8 days, the new bone starts to form, infiltrated and replaced the clot. The fourth stage, the original bundle bone replaced the connective tissue: bundle bone begin to form after 38 days of extraction, and bone tissue are fully formed at 3 months. The fifth stage, the immature bone tissue replaced with newly formed mature bone tissue: the alveolar process begin to reconstruct 3 days after extraction and gradually becomes mature bone tissue in 40 days, the remodeling of alveolar bone basically completed around 3–6 months.

By way of 6 months clinical trial, Lekovic *et al.* [15,16] found that control sites without any membrane after 6 months of extraction, the average distance of bone resorption in horizontal direction and vertical direction is 4.56 mm and 1.5 mm, respectively, but the experimental sites which covered with bioabsorbable membranes

Table 7. The main effects and interactions of the repeated measure data of time variable

Source	Type III sum of squares	DF	Mean square	F	Sig
Time	0.051	1	0.051	0.763	0.392
Time*type	1.672	1	1.672	24.877	0.000
Time*sex	0.055	1	0.055	0.825	0.373
Time*position	0.032	2	0.016	0.240	0.788
Time*type*sex	0.29	1	0.029	0.429	0.519
Time*type*position	0.186	2	0.093	1.382	0.272
Time*sex*position	0.300	2	0.150	2.235	0.131
Time*type*sex*position	0.082	2	0.041	0.613	0.551
Error (time)	1.479	22	0.067		

Table 8. The main effects and interactions of the other grouping factors

Source	Type III sum of squares	DF	Mean square	F	Sig
Intercept	193.394	1	193.394	342.695	<.0001
Type	8.667	1	8.667	15.357	0.001
Sex	0.001	1	0.001	0.002	0.964
Position	0.823	2	0.411	0.729	0.494
Type*sex	0.095	1	0.095	0.168	0.686
Type*position	2.004	2	1.002	1.776	0.193
Sex*position	4.491	2	2.246	3.979	0.033
Type*sex*position	0.018	2	0.009	0.016	0.984
Error	12.415	22	0.564		

presented with less horizontal resorption of the alveolar bone ridge. Schropp *et al.* [13] demonstrated that the major changes of an extraction site occurred during 1 year after tooth extraction, and two-thirds of the changes occurred in the first trimester. Araujo and Lindhe [17] have studied the dimensional changes of the alveolar ridge after tooth extraction and the processes of bone modeling and remodeling associated with this change. The results showed that the significant change occurred in the first 8 weeks, and during this period, there was a marked osteoclastic activity resulting in resorption of the buccal and the lingual bone wall. Because of the height of the walls at the buccal aspect of the extraction socket was significantly lower than the lingual aspect, the horizontal bone loss at the buccal aspect was more seriously than the lingual aspect.

It give us two enlightenment: (i) the effective interence time of bone remodeling following tooth extraction is the first trimester and (ii) provided nature scaffolds for the osteoblast, which promote the cell migration and differentiation as well as bony union, and preserve the bone mass of alveolar ridge in maximum.

The necessity of site preservation

Site preservation [18] is a measurement that is taken at the time of or following tooth extraction to prevent the alveolar ridge bone resorption in maximum and provided sufficient alveolar bone volume and favorable ridge architecture for dental implantation. Indeed, any procedures can prevent the resorption of alveolar ridge can be seen as site preservation in broader understanding, such as choose the best time to undertake an extraction, minimally traumatic tooth extraction, soft and hard tissue grafting, concomitant use of barrier membranes and immediate implant placement [19]. Placing various bone graft materials inside the extraction socket is the most efforts

of current researches for this method is easy, little trauma and the materials have wide sources.

Site preservation can minimize external resorption of the alveolar ridge and maximize bone formation within the socket. Extensive clinical trials and animal experiments have demonstrated that placing various bone graft materials inside the extraction socket can prevent the height of alveolar ridge effectively in both height and width. Ultramari *et al.* [20] have demonstrated that treatment of postextraction alveoli with xenogeneic grafting material can preserve bone height initially compared to when no xenograft is used are not sustained. Iasella *et al.* [21] found that the use of tetracycline-hydrated freeze-dried bone allograft in the fresh extraction sites lost less width and height and had more bone infill compared to the test group of natural healing. Mardas *et al.* [22] used a synthetic bone substitute and a bovine-derived xenograft combined with a Col membrane to preserve the alveolar ridge dimensions following tooth extraction, the width of the alveolar ridge reduce by 13% and 23%, respectively, and both of them are significantly lower than the control group of natural healing.

From histological perspective, site preservation techniques following tooth extraction can provide good bone for dental implant. Though many literature have demonstrated that the extraction sockets can form to new bone by site preservation techniques, there are many different between the speed and quantity of new bone formation, which related to the biological and physical and chemical properties of the materials that selected closely. Thus, we put forward a higher requirement to the bone graft for site preservation.

Bone graft materials

An ideal bone-grafting material should not only have a good biocompatibility and biodegradability but also be able to produce bone by osteogenesis, osteoinduction and osteoconduction [23]. Besides, their mechanical properties should be equivalent to or better than those of natural bone [24]. Thus, autogenous bone is regarded as a ‘golden standard’ because it is biocompatible and has the potential to form new bone through osteogenesis, osteoinduction and osteoconduction, but its application is limited by the amount of source and post-operative discomfort of the donor site [25]. Several types of bone substitutes are commercially available in recent years, such as allograft, xenografts and alloplasts. They all have some disadvantages, allograft and xenografts cannot avoid the risk of disease transmission, immunological rejection and ethical issues; alloplasts are synthetic bone substitutes that act as a biologic filler with limited periodontal regeneration when used in treating periodontal bone defects [26].

Therefore, based on the understanding of the natural bone and its formation process, many studies have been performed to prepare biomimetic materials mimicking the native bone in the composition, microstructure and the processes of mineralization [27–29]. Designing and preparing new materials and synthesizing bone substitute materials mimicking the natural bone have become a hot topic in the field of biomaterials [30]. Although many scholars have obtained the so-called ‘mineralized collagen’ that consisted of Col/HA composites with or without the self-assembly structure of the natural bone MC, some of them are not strictly a bionic technology. And some of them [31–36] are lack of evidence demonstrating the presence of self-assembled MC and orderly arranged nano-sized HA crystals within the Col fibrils. Cui and co-workers [8, 10] designed MC nano-fibrils via hierarchical self-assembly, which were consistent with autologous bone in terms of both the composition and the microstructure. For the first time, the hierarchical self-assembly structure of Col/HA composite was verified by conventional and

high-resolution transmission electron microscopy [8]. This study has gained widespread international attention in the field of biomaterials, and *Nature Materials* commented and posted a literature noted that ‘The authors found that nanocrystals of the minerals were deposited along the surface of the fibrils—giving the first direct evidence to support previous theories that this occurs’ [37].

Conclusions

The two types of materials used in this study have the same composition of HA and Col but have different microstructures. Compared to physically blended nHA/Col, biomimetic MC had significant promotion effect on the height of bone formation. Therefore, the microstructure played an important role in clinical performance for the bone grafts. The MC with biomimetic composition and microstructure would have broad clinical application prospect in the field of oral and maxillofacial surgeries.

Acknowledgements

This work was in part supported by the National Basic Research Program of China (973 Program, 2011CB606205) and the ‘Twelfth Five-Year’ National Science and Technology Support Program (2012BAI17B02) funded by the Ministry of Science and Technology of China and the National Natural Science Foundation of China (Grant Nos. 21371106 and 51402167).

Conflict of interest statement. None declared.

References

1. Araujo MG, Wennstrom JL, Lindhe J. Modeling of the buccal and lingual bone walls of fresh extraction sites following implant installation. *Clin Oral Implants Res* 2006;17:606–14.
2. Froum S, Cho SC, Rosenberg E *et al.* Histological comparison of healing extraction sockets implanted with bioactive glass or demineralized freeze-dried bone allograft: a pilot study. *J Periodontol* 2002;73:94–102.
3. Cui FZ, Li Y, Ge J. Self-assembly of mineralized collagen composites. *Mater Sci Eng R Rep* 2007;57:1–27.
4. Nalla RK, Porter AE, Daraio C *et al.* Ultrastructural examination of dentin using focused ion-beam cross-sectioning and transmission electron microscopy. *Micron* 2005;36:672–80.
5. Roeder RK, Schwartz AG, Pasteris JD *et al.* Mineral distributions at the developing tendon enthesis. *PLoS One* 2012;7:e48630.
6. James R, Deng M, Laurencin CT *et al.* Nanocomposites and bone regeneration. *Front Mater Sci* 2011;5:342–57.
7. Qiu ZY, Cui Y, Tao CS *et al.* Mineralized collagen: rationale, current status, and clinical applications. *Materials* 2015;8:4733.
8. Zhang W, Liao SS, Cui FZ. Hierarchical self-assembly of nano-fibrils in mineralized collagen. *Chem Mater* 2003;15:3221–6.
9. Landis WJ, Song MJ, Leith A *et al.* Mineral and organic matrix interaction in normally calcifying tendon visualized in three dimensions by high-voltage electron microscopic tomography and graphic image reconstruction. *J Struct Biol* 1993;110:39–54.
10. Ke-Bin L, Kui H, Yu T *et al.* Use of mineralized collagen bone graft substitutes and dorsal locking plate in treatment of elder metaphyseal comminuted distal radius fracture. *Front Mater Sci* 2014;8:87–94.
11. Liao SS, Cui FZ, Zhang W *et al.* Hierarchically biomimetic bone scaffold materials: nano-HA/collagen/PLA composite. *J Biomed Mater Res B Appl Biomater* 2004;69B:158–65.
12. Du C, Cui FZ, Zhang W *et al.* Formation of calcium phosphate/collagen composites through mineralization of collagen matrix. *J Biomed Mater Res* 2000;50:518–27.
13. Schropp L, Wenzel A, Kostopoulos L *et al.* Bone healing and soft tissue contour changes following single-tooth extraction: a clinical and

- radiographic 12-month prospective study. *Int J Periodontics Restorative Dent* 2003;23:313–23.
14. Amler MH, Johnson PL, Salman I. Histological and histochemical investigation of human alveolar socket healing in undisturbed extraction wounds. *J Am Dent Assoc* 1960;61:32–44.
 15. Lekovic V, Camargo PM, Klokkevold PR et al. Preservation of alveolar bone in extraction sockets using bioabsorbable membranes. *J Periodontol* 1998;69:1044–9.
 16. Lekovic V, Kenney EB, Weinlaender M et al. A bone regenerative approach to alveolar ridge maintenance following tooth extraction. Report of 10 cases. *J Periodontol* 1997;68:563–70.
 17. Araujo MG, Lindhe J. Dimensional ridge alterations following tooth extraction. An experimental study in the dog. *J Clin Periodontol* 2005;32:212–8.
 18. Darby I, Chen S, De Poi R. Ridge preservation: what is it and when should it be considered. *Aust Dent J* 2008;53:11–21.
 19. Tomlin EM, Nelson SJ, Rossmann JA. Ridge preservation for implant therapy: a review of the literature. *Open Dent J* 2014;8:66–76.
 20. Oltramari PV, Navarro Rde L, Henriques JF et al. Evaluation of bone height and bone density after tooth extraction: an experimental study in minipigs. *Oral Surg Oral Med Oral Pathol Oral Radiol Endod* 2007;104:e9–16.
 21. Iasella JM, Greenwell H, Miller RL et al. Ridge preservation with freeze-dried bone allograft and a collagen membrane compared to extraction alone for implant site development: a clinical and histologic study in humans. *J Periodontol* 2003;74:990–9.
 22. Mardas N, Chadha V, Donos N. Alveolar ridge preservation with guided bone regeneration and a synthetic bone substitute or a bovine-derived xenograft: a randomized, controlled clinical trial. *Clin Oral Implants Res* 2010;21:688–98.
 23. Porrini R, Rocchetti V, Vercellino V et al. Alveolar bone regeneration in post-extraction socket: a review of materials to postpone dental implant. *Biomed Mater Eng* 2011;21:63–74.
 24. Langer R, Vacanti JP. Tissue engineering. *Science* 1993;260:920–6.
 25. Vos MD, Raghoebar GM, van der Wal JE et al. Autogenous femoral head as grafting material for mandibular augmentation. *Int J Oral Maxillofac Surg* 2009;38:1320–3.
 26. AlGhamdi AS, Shibly O, Ciancio SG. Osseous grafting part II: xenografts and alloplasts for periodontal regeneration—a literature review. *J Int Acad Periodontol* 2010;12:39–44.
 27. Ma J, Wang J, Ai X et al. Biomimetic self-assembly of apatite hybrid materials: from a single molecular template to bi-/multi-molecular templates. *Biotechnol Adv* 2014;32:744–60.
 28. Palmer LC, Newcomb CJ, Kaltz SR et al. Biomimetic systems for hydroxyapatite mineralization inspired by bone and enamel. *Chem Rev* 2008;108:4754–83.
 29. Nudelman F, Lausch AJ, Sommerdijk NA et al. In vitro models of collagen biomineralization. *J Struct Biol* 2013;183:258–69.
 30. Tampieri A, Sprio S, Sandri M et al. Mimicking natural bio-mineralization processes: a new tool for osteochondral scaffold development. *Trends Biotechnol* 2011;29:526–35.
 31. Kikuchi M. Hydroxyapatite/collagen bone-like nanocomposite. *Biol Pharm Bull* 2013;36:1666–9.
 32. Kikuchi M, Itoh S, Ichinose S et al. Self-organization mechanism in a bone-like hydroxyapatite/collagen nanocomposite synthesized in vitro and its biological reaction in vivo. *Biomaterials* 2001;22:1705–11.
 33. Bradt JH, Mertig M, Teresiak A et al. Biomimetic mineralization of collagen by combined fibril assembly and calcium phosphate formation. *Chem Mater* 1999;11:2694–701.
 34. Pederson AW, Ruberti JW, Messersmith PB. Thermal assembly of a biomimetic mineral/collagen composite. *Biomaterials* 2003;24:4881–90.
 35. Fikai A, Andronescu E, Voicu G et al. Self-assembled collagen/hydroxyapatite composite materials. *Chem Eng J* 2010;160:794–800.
 36. Wang J, Liu C. Biomimetic collagen/hydroxyapatite composite scaffolds: fabrication and characterizations. *J Bionic Eng* 2014;11:600–9.
 37. Polishing, sensing, switching and synthesizing. *Nat Mater* 2003;2:566–566.