

Radiofrequency ablation of malignant cervical lymph nodes: an unusual treatment for dysphagia

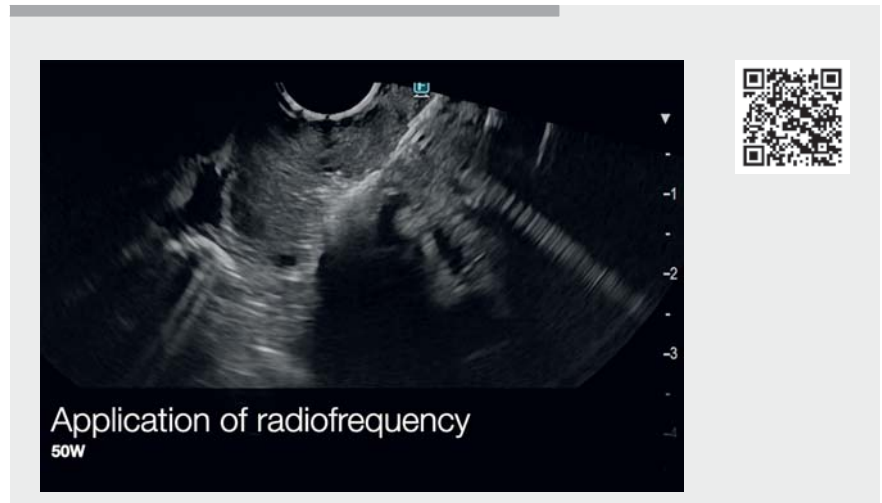


Radiofrequency ablation (RFA) has been used for the treatment of nonfunctional pancreatic neuroendocrine tumors (PNETs) <2 cm [1], functional PNETs (insulinoma) [2], pancreatic metastasis of kidney cancer [3], and isolated cases of intraductal papillary mucinous neoplasm (IPMN) with worrisome features [4]. We describe the use of RFA to treat a compressive cervical lymph node causing dysphagia (► **Video 1**).

A 64-year-old woman undergoing palliative care for metastatic cervical cancer was treated with several lines of chemotherapy (cisplatin-paclitaxel, capecitabine, vinorelbine, paclitaxel, carboplatin, topotecan). The patient presented rapid-onset, dysphagia progressing to grade IV due to a large cervical area lymph node metastasis. The patient had already undergone radiotherapy on the cervical area during the management of her disease. The stenosis was also too close to Killian's triangle to place an esophageal stent. After discussion with the patient and because she could not swallow her own saliva without discomfort, we proposed the use of endoscopic ultrasound-guided RFA on the cervical area lymph nodes.

RFA was performed with a therapeutic linear echoendoscope under carbon dioxide insufflation using EUS-RFA (Starmed/TaeWoong Medical, Gimpo, South Korea). The procedure was performed with the patient sedated and intubated. Radiofrequency power was typically applied (50W) until the appearance of hyperechoic bubbles.

The patient underwent one session of RFA, with two total RFA shots adminis-



► **Video 1** Radiofrequency ablation of malignant cervical lymph nodes.

tered. Clinicians should be careful to not perform RFA too close to the esophageal wall to avoid potential fistula. The goal of the treatment was necrosis of the posterior part of the lymph node.

After 2 days, the dysphasia was reduced to grade I. After 4 months, the patient received only supportive care owing to disease progression.

RFA is a promising minimally invasive technique mainly described for PNETs, but additional applications are expected.

Endoscopy_UCTN_Code_TTT_1AS_2AC

Competing interests

The authors declare that they have no conflict of interest.

The authors

Fabrice Caillol¹, **Jean-Philippe Ratone**¹, **Mariola Marx**¹, **Yanis Dahel**¹, **Solene Hoibian**¹, **Magali Provansal**², **Marc Giovannini**¹

- 1 Endoscopy Unit, Paoli Calmettes Institute, Marseille, France
- 2 Oncology Unit, Paoli Calmettes Institute, Marseille, France

Corresponding author

Fabrice Caillol, MD

Endoscopy Unit, Paoli Calmettes Institute, 232 bd Ste Marguerite, 13009 Marseille, France
fcaillol@free.fr

References

- [1] Marx M, Godat S, Caillol F et al. Management of non-functional pancreatic neuroendocrine tumors by endoscopic ultrasound-guided radiofrequency ablation: retrospective study in two tertiary centers. *Dig Endosc* 2022; 34: 1207–1213
- [2] Marx M, Trosic-Ivanisevic T, Caillol F et al. EUS-guided radiofrequency ablation for pancreatic insulinoma: experience in 2 tertiary centers. *Gastrointest Endosc* 2022; 95: 1256–1263
- [3] Chanez B, Caillol F, Ratone JP et al. Endoscopic ultrasound-guided radiofrequency ablation as an future alternative to pancreatotomy for pancreatic metastases from renal cell carcinoma: a prospective study. *Cancers (Basel)* 2021; 13: 5267
- [4] Barthet M, Giovannini M, Lesavre N et al. Endoscopic ultrasound-guided radiofrequency ablation for pancreatic neuroendocrine tumors and pancreatic cystic neoplasms: a prospective multicenter study. *Endoscopy* 2019; 51: 836–842

Bibliography

Endoscopy 2023; 55: E199–E200

DOI 10.1055/a-1965-3599

ISSN 0013-726X

published online 11.11.2022

© 2022. The Author(s).

This is an open access article published by Thieme under the terms of the Creative Commons Attribution-NonDerivative-NonCommercial License, permitting copying and reproduction so long as the original work is given appropriate credit. Contents may not be used for commercial purposes, or adapted, remixed, transformed or built upon. (<https://creativecommons.org/licenses/by-nc-nd/4.0/>)

Georg Thieme Verlag KG, Rüdigerstraße 14,
70469 Stuttgart, Germany



ENDOSCOPY E-VIDEOS

<https://eref.thieme.de/e-videos>



Endoscopy E-Videos is an open access online section, reporting on interesting cases and new techniques in gastroenterological endoscopy. All papers include a high quality video and all contributions are freely accessible online. Processing charges apply (currently EUR 375), discounts and waivers acc. to HINARI are available.

This section has its own submission website at

<https://mc.manuscriptcentral.com/e-videos>