

# Metastatic brain tumor from urothelial carcinoma of the prostatic urethra

Kohei Morita, Masashi Oda, Masaomi Koyanagi, Masaaki Saiki

Department of Neurosurgery, National Hospital Organization Himeji Medical Center, Himeji, Hyogo, Japan

E-mail: \*Kohei Morita - kmorita710@gmail.com; Masashi Oda - masashi@kuhp.kyoto-u.ac.jp; Masaomi Koyanagi - koyanagm@gmail.com; Masaaki Saiki - seijinbyo@hotmail.com

\*Corresponding author

Received: 16 May 15 Accepted: 24 May 16 Published: 07 July 16


## Abstract

**Background:** Urothelial carcinoma occurs in the bladder, upper urinary tract, and lower urinary tract, including prostatic urethra. A majority of the reported cases of intracranial metastasis from urothelial carcinoma originates from the bladder and upper urinary tract. Brain metastasis from urothelial carcinoma of the prostatic urethra has not yet been reported in the literature.

**Case Description:** A 72-year-old male presented with a metastatic brain tumor and a 3-year history of urothelial carcinoma of the prostatic urethra treated with cystourethrectomy and chemotherapy with gemcitabine-cisplatin. Pathological diagnosis for tumor removal was compatible with metastatic brain tumor from urothelial carcinoma.

**Conclusion:** Brain metastasis from urothelial carcinoma of the prostatic urethra has not yet been reported in the literature. It is an extremely rare case, however, we should be careful of brain metastasis during follow-up for urothelial carcinoma in the lower urinary tract.

**Key Words:** Metastatic brain tumor, prostatic urethra, urothelial carcinoma

<b>Access this article online</b>
<b>Website:</b> <a href="http://www.surgicalneurologyint.com">www.surgicalneurologyint.com</a>
<b>DOI:</b> 10.4103/2152-7806.185784
<b>Quick Response Code:</b>


## INTRODUCTION

Brain metastasis is the most common form of brain tumor in adults, mainly occurring from the lung, breast, and colon. Brain metastasis derived from the urinary bladder and urinary tract cancer is rare.<sup>[4]</sup> The most common pathology of urinary bladder and urinary tract cancer is urothelial carcinoma. The majority of reported cases of intracranial metastasis from urothelial carcinoma originate from the bladder and upper urinary tract. To the best of our knowledge, brain metastasis from urothelial carcinoma of the prostatic urethra has not yet been reported. In this paper, we present a brain metastatic case derived from urothelial carcinoma of the prostatic urethra that underwent surgical resection and whole brain radiation therapy.

## CASE REPORT

A 72-year-old, right-handed man with a past medical history of urothelial carcinoma of the prostatic urethra presented with left homonymous hemianopsia and headaches. The patient was previously diagnosed with

This is an open access article distributed under the terms of the Creative Commons Attribution-NonCommercial-ShareAlike 3.0 License, which allows others to remix, tweak, and build upon the work non-commercially, as long as the author is credited and the new creations are licensed under the identical terms.

**For reprints contact:** [reprints@medknow.com](mailto:reprints@medknow.com)

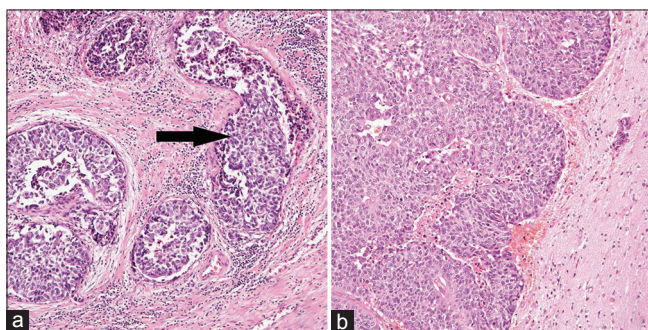
**How to cite this article:** Morita K, Oda M, Koyanagi M, Saiki M. Metastatic brain tumor from urothelial carcinoma of the prostatic urethra. *Surg Neurol Int* 2016;7:S488-91.

<http://surgicalneurologyint.com/Metastatic-brain-tumor-from-urothelial-carcinoma-of-the-prostatic-urethra/>

urothelial carcinoma of the prostatic urethra when he was 68 years old. At that time, he was treated with total cystourethrectomy. The pathological diagnosis revealed urothelial carcinoma with no metastasis to the lymph node but invasion into the vein [Figure 1a]. At the time of urothelial carcinoma diagnosis, computed tomography (CT) scan of the chest showed a tumor in the upper right lobe of the lung, which was diagnosed as adenocarcinoma with a transbronchial lung biopsy. Three months after total cystourethrectomy, the patient was treated with a left upper lobectomy of the lung and dissection of the lymph node with video-assisted thoracic surgery. The pathological diagnosis was adenocarcinoma of the lung with no metastasis to the lymph node and was considered to have no relationship to urothelial carcinoma.

A follow-up abdominal CT scan 1 year after cystourethrectomy showed metastasis of urothelial carcinoma to the lateral external iliac of the right lymph node. He was treated with six cycles of gemcitabine and cisplatin chemotherapy. During post-chemotherapy follow-up, other metastases were not found.

Three years after cystourethrectomy, the patient presented with left homonymous hemianopsia and headaches. Neurological examination upon admission revealed no other neurological deficits. Magnetic resonance imaging (MRI) showed an irregularly-shaped, heterogeneously-enhanced mass with gadolinium enhancement on T1-weighted images [Figure 2a] surrounded by marked edema in the right occipital lobe and the calcarine area. Metastatic tumors were not found elsewhere. The diameter was approximately 30 mm and was considered to have partial attachment to the dura mater. We removed the tumor via a right occipital craniotomy. The tumor had attached to the dura and so we incised it from the edge of attachment. The tumor was soft, yellowish-gray, and fairly well-demarcated



**Figure 1:** (a) A 68-year-old patient was treated with total cystourethrectomy. Hematoxylin-eosin staining of the prostatic urethra reveals urothelial carcinoma. The arrow indicates groups of urothelial carcinoma cells invading into the vein. (b) Hematoxylin-eosin staining of metastatic brain tumor shows groups of well-differentiated urothelial carcinoma cells with necrosis, which is the same pathological findings of the origin of the tumor, the prostatic urethra. The tumor was attached to the dura mater

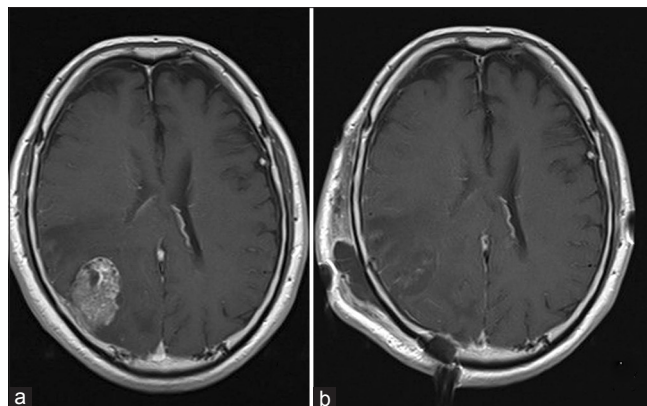
from the surrounding brain with no apparent feeding artery. The pathological conclusion was that this was a well-differentiated urothelial carcinoma with necrosis, which was considered to have metastasized from the urothelial carcinoma of the prostatic urethra [Figure 1b].

Postoperative MRI showed gross total removal of the tumor [Figure 2b]. Whole brain radiation therapy, 30 Grays in 10 fractions, was performed following tumor removal. The patient had no other neurological deficits except for left homonymous hemianopsia.

## DISCUSSION

We reported here a rare case of a metastatic brain tumor from urothelial carcinoma of the lower urinary tract with venous invasion and metastasis to the lymph nodes. Urothelial carcinoma is a common type of cancer in western countries<sup>[2]</sup> and easily results in metastatic tumors. A retrospective study of 392 patients with urinary bladder cancer reported the most common sites of metastasis to be the lymph nodes (104 patients, 69%) followed by bone (71 patients, 47%), lung (55 patients, 37%), liver (39 patients, 26%), and peritoneum (24 patients, 16%).<sup>[9]</sup> Urothelial carcinomas are categorized by their anatomical origin as upper urinary tract and lower urinary tract.

Although urothelial carcinoma from the lower urinary tract has the same pathological features as urothelial carcinoma from the upper urinary tract, there are some differences in the mechanism of metastasis.<sup>[12,14]</sup> First, most metastatic tumors of urothelial carcinoma occur from the upper urinary tract and not from the lower urinary tract. Second, the regional lymph nodes are different; the lower urinary tract's regional lymph nodes are internal iliac lymph nodes, external iliac lymph nodes, obturator lymph nodes, common iliac lymph nodes, and presacral lymph nodes, whereas the upper urinary tract's



**Figure 2:** (a) Magnetic resonance image (MRI) before the operation shows an irregularly shaped, heterogeneously enhanced mass with Gadolinium enhancement on T1 images. (b) MRI after the operation shows gross total removal of the tumor

regional lymph nodes are paraaortic lymph nodes and paracaval lymph nodes. Third, the anatomical feature of each urinary tract is different; the lower urinary tract has a muscle layer whereas the upper urinary tract has no muscle layer. In addition, there are less invasive carcinomas at the lower urinary tract than the upper urinary tract. These factors may result in the mechanistic differences of metastasis between the upper and lower urinary tracts.

For the treatment of urothelial carcinoma, the primary form of chemotherapy is cisplatin-based schemes such as gemcitabine-cisplatin (GC); methotrexate, vinblastine, doxorubicin, and cisplatin (M-VAC); or paclitaxel, cisplatin, and gemcitabine (PCG).<sup>[2]</sup> Among these series, the GC combination showed a significantly better toxicity profile and is now considered the standard treatment for this disease.<sup>[10]</sup> In contrast to other organs, metastatic brain tumors often show resistance to chemotherapy because the brain is partially protected from systemic drugs by the blood-brain barrier (BBB) and the blood-tumor barrier.<sup>[7]</sup> In the present case, it is possible that chemotherapy was effective on the metastatic tumor in other organs, however, was less effective on the metastatic brain tumor, resulting in a solitary metastatic brain tumor.

Similar to other metastatic brain tumors, the treatment for cerebral metastasis of urothelial carcinoma may follow the general guidelines for metastatic brain tumors. For a single large-sized lesion (>3 cm), particularly with a mass effect (>1 cm midline shift), surgical resection should be considered with/without whole brain radiotherapy (WBRT). WBRT has been accepted as one of the treatments for metastatic brain tumors.<sup>[3,8]</sup>

Cases of metastatic urothelial carcinoma usually show poor outcomes,<sup>[6,11]</sup> because when it does occur, it has already been in the setting of a widespread metastatic disease.<sup>[4]</sup> However, in this case, the CT images showed no other apparent metastasis. Metastatic brain carcinoma is often a secondary metastasis from metastatic lung tumors, and solitary brain metastasis without lung metastasis is rare. Prostatic adenocarcinoma, however, sometimes shows solitary brain metastasis. Reported cases of prostatic adenocarcinoma suggest that metastasis via vertebral venous plexus sometimes results in solitary brain metastasis because blood flow of the epidural and vertebral veins may anatomically communicate with the veins of the thoracic or abdominal cavities and the central nervous system.<sup>[1,5]</sup> Therefore, tumors at the pelvic area, including the urinary tract, could disseminate to the central nervous system without lung metastasis. Because urothelial carcinoma of the prostatic urethra occurs at almost the same position of prostatic adenocarcinoma, it may lead to a solitary brain tumor through the same mechanism as that of brain metastasis from prostatic adenocarcinoma. This case showed venous invasion of

the tumor, thus, solitary brain metastasis via the vertebral venous plexus could be involved. It is possible that the metastatic urothelial carcinoma in this case occurred from a micrometastatic lung tumor. Subsequently, the micrometastatic lung tumor and other metastatic tumors, including the lateral external iliac right lymph node, were successfully treated with chemotherapy, however, the remaining metastatic brain tumor was not, due to the BBB's resistance to chemotherapy.

Although metastatic brain tumors of urothelial carcinoma of the prostatic urethra are rare, accounting for this metastatic mechanism, we should consider the possibility of brain metastasis. In addition, a reported case of a long-term survivor showed that good control of metastasis resulted in a good prognosis.<sup>[13]</sup>

Considering this case, taking a frequent follow-up and treatment with chemotherapy, including the GC protocol, is recommended after surgical treatment.

## CONCLUSION

This is a case of a metastatic brain tumor of urothelial carcinoma of the prostatic urethra and lower urinary tract. It could be treated with surgical resection, chemotherapy, and radiation therapy as with other metastatic brain tumors of urothelial carcinoma. Considering a poor prognosis of the tumor, we should be careful to consider brain metastasis during the follow-up of patients with urothelial carcinoma in the lower urinary tract as with other urothelial carcinomas.

## Financial support and sponsorship

Nil.

## Conflicts of interest

The authors declare that the article content was composed in the absence of any commercial or financial relationships that could be construed as a potential conflict of interest. A component of this case was presented at the spring conference of Japan Neurosurgery Association in Kinki legion, Osaka, April 14, 2015.

## REFERENCES

1. Batson OV. The function of the vertebral veins and their role in the spread of metastases. *Ann Surg* 1940;112:138-49.
2. Castellano D, Puente J, de Velasco G, Chirivella I, Lopez-Criado P, Mohedano N, et al. Safety and effectiveness of vinflunine in patients with metastatic transitional cell carcinoma of the urothelial tract after failure of one platinum-based systemic therapy in clinical practice. *BMC Cancer* 2014;14:779.
3. Chaichana KL, Rao K, Gadkaree S, Dangelmajer S, Bettgowda C, Rigamonti D, et al. Factors associated with survival and recurrence for patients undergoing surgery of cerebellar metastases. *Neurol Res* 2014;36:13-25.
4. Clatterbuck RE, Sampath P, Olivi A. Transitional cell carcinoma presenting as a solitary brain lesion: A case report and review of the world literature. *J Neurooncol* 1998;39:91-4.
5. Ferverza FC, Wolanskyj AP, Eklund HE, Richardson RL. Brain metastasis:

- An unusual complication from prostatic adenocarcinoma. *Mayo Clin Proc* 2000;75:79-82.
6. Moon KS, Jung S, Lee KH, Hwang EC, Kim IY. Intracranial metastasis from primary transitional cell carcinoma of female urethra: Case report & review of the literature. *BMC Cancer* 2011;11:23.
  7. Palmieri D, Chambers AF, Felding-Habermann B, Huang S, Steeg PS. The biology of metastasis to a sanctuary site. *Clin Cancer Res* 2007;13:1656-62.
  8. Rades D, Meyners T, Veninga T, Stalpers LJA, Schild SE. Hypofractionated whole-brain radiotherapy for multiple brain metastases from transitional cell carcinoma of the bladder. *Int J Radiat Oncol Biol Phys* 2010;78:404-8.
  9. Sarmiento JM, Wi MS, Piao Z, Stiner ES. Solitary cerebral metastasis from transitional cell carcinoma after a 14-year remission of urinary bladder cancer treated with gemcitabine: Case report and literature review. *Surg Neurol Int* 2012;3:82.
  10. Toschi L, Finocchiaro G, Bartolini S, Gioia V, Cappuzzo F. Role of gemcitabine in cancer therapy. *Future Oncol* 2005;1:7-17.
  11. Tsugu A, Yoshiyama M, Matsumae M. Brain metastasis from large cell neuroendocrine carcinoma of the urinary bladder. *Surg Neurol Int* 2011;2:84.
  12. Xie J, Zhang XB, Wen J, Zhang YS, Li HZ. Comparison of clinicopathological features in metastatic upper tract urothelial carcinoma and urothelial bladder cancer. *Int Urol Nephrol* 2016;48:481-7.
  13. Yasuda K, Nakamura M, Takamoto D, Sanjo H, Gohbara A, Teranishi JI, et al. A case of long-term survivor after combined modality therapy for brain metastasis of bladder carcinoma. *Hinyokika Kiyo* 2012;58:553-6.
  14. Yates DR, Catto JW. Distinct patterns and behaviour of urothelial carcinoma with respect to anatomical location: How molecular biomarkers can augment clinico-pathological predictors in upper urinary tract tumours. *World J Urol* 2013;31:21-9.